



The GIANT

Find herein histology practical presentations

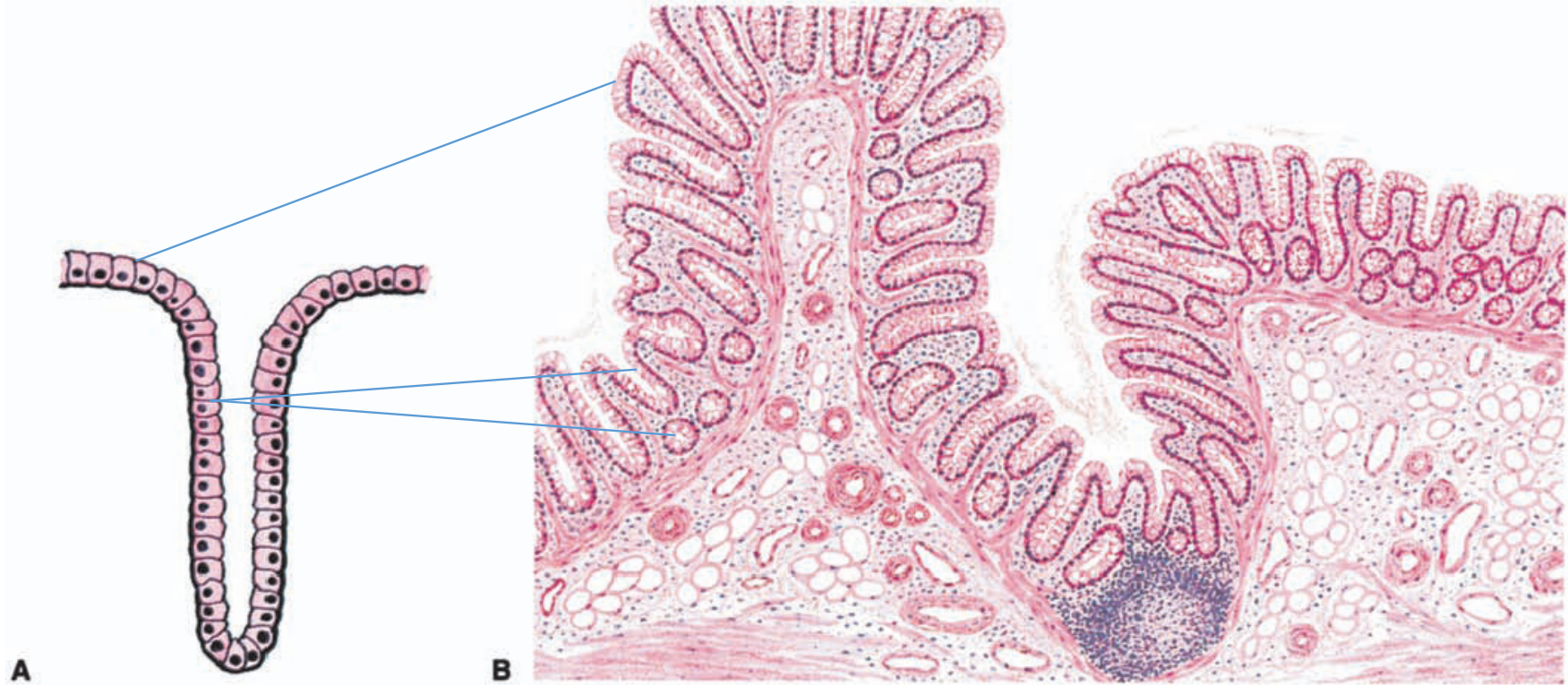
4,5,6,7,9,10,11,13.20 and 22.

[Giant compilation October 17th 2021.](#)

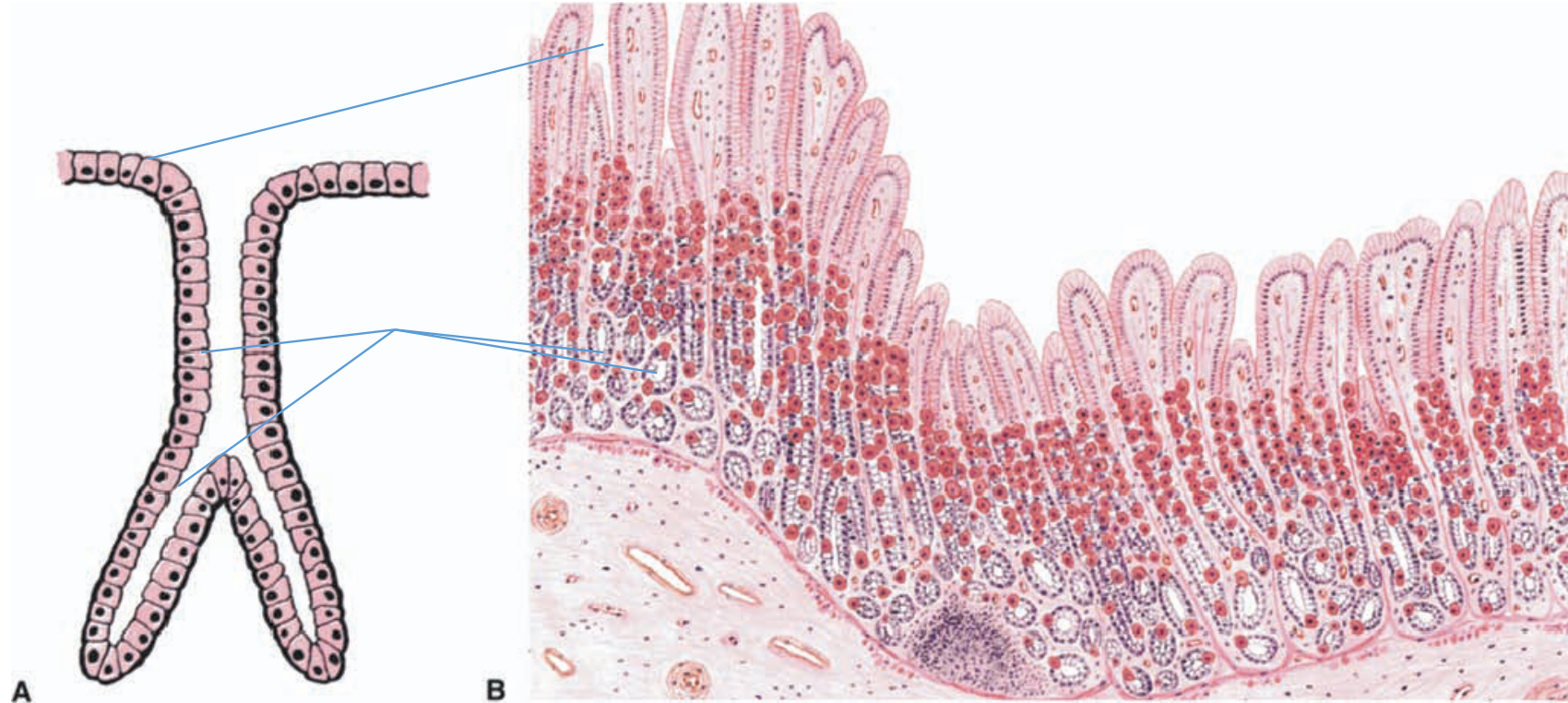
PRACTICAL 4

EPITHELIAL 2-EXOCRINE GLANDS

UNBRANCHED SIMPLE TUBULAR EXOCRINE GLANDS



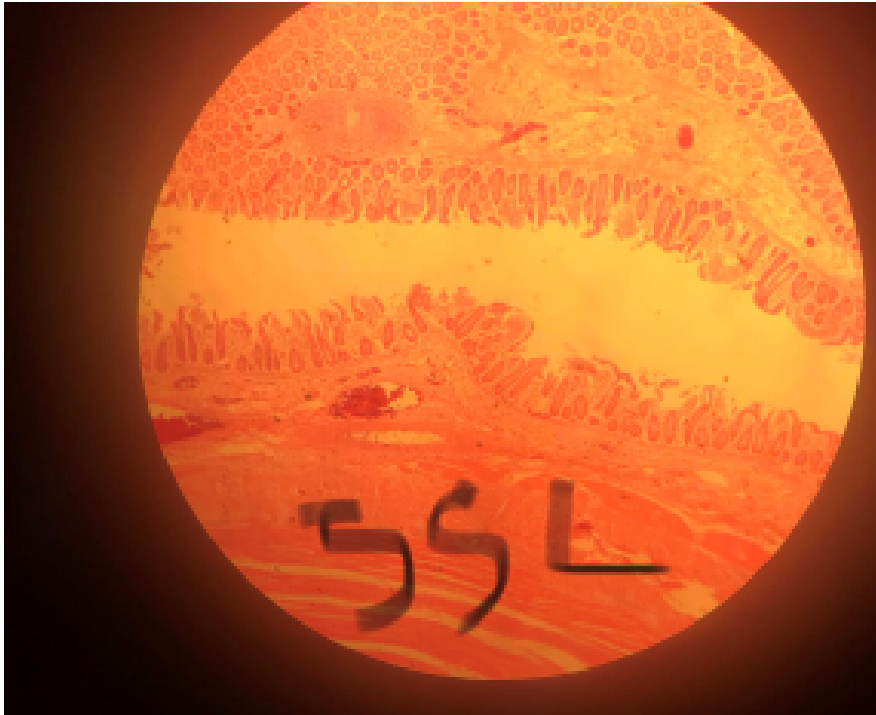SIMPLE BRANCHED TUBULAR GLAND EXOCRINE GLAND



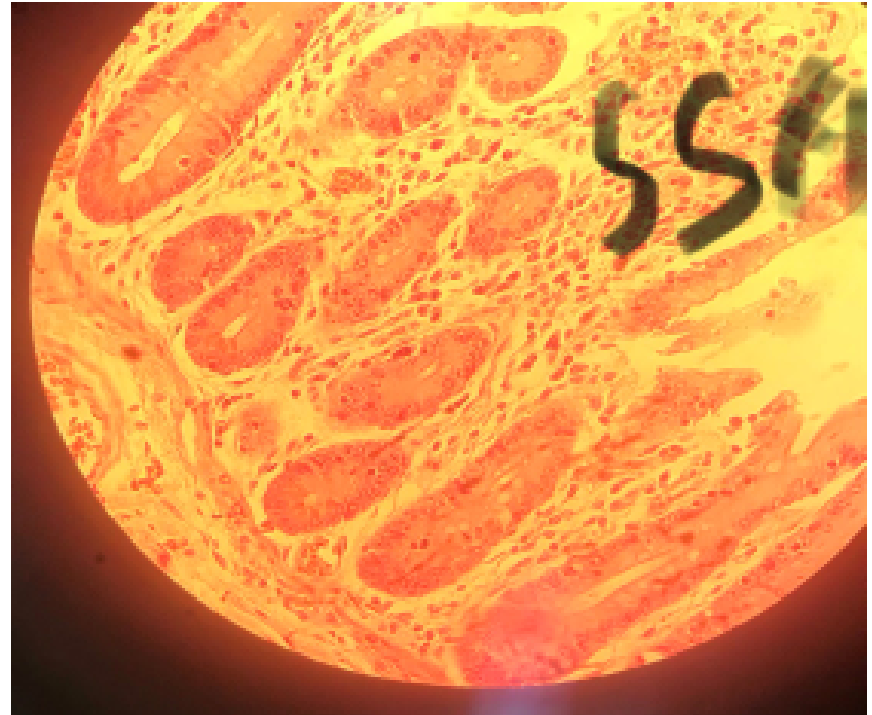SIMPLE TUBULAR GLANDS AND UNICELLULAR GLANDS

SLIDE 55 ILEUM (H&E)

- LP

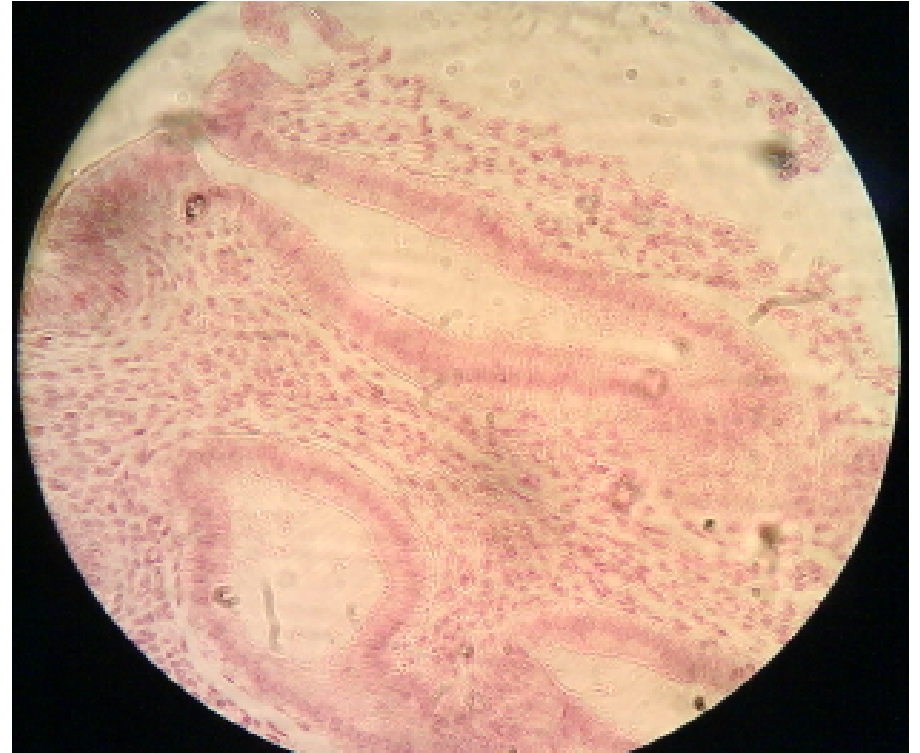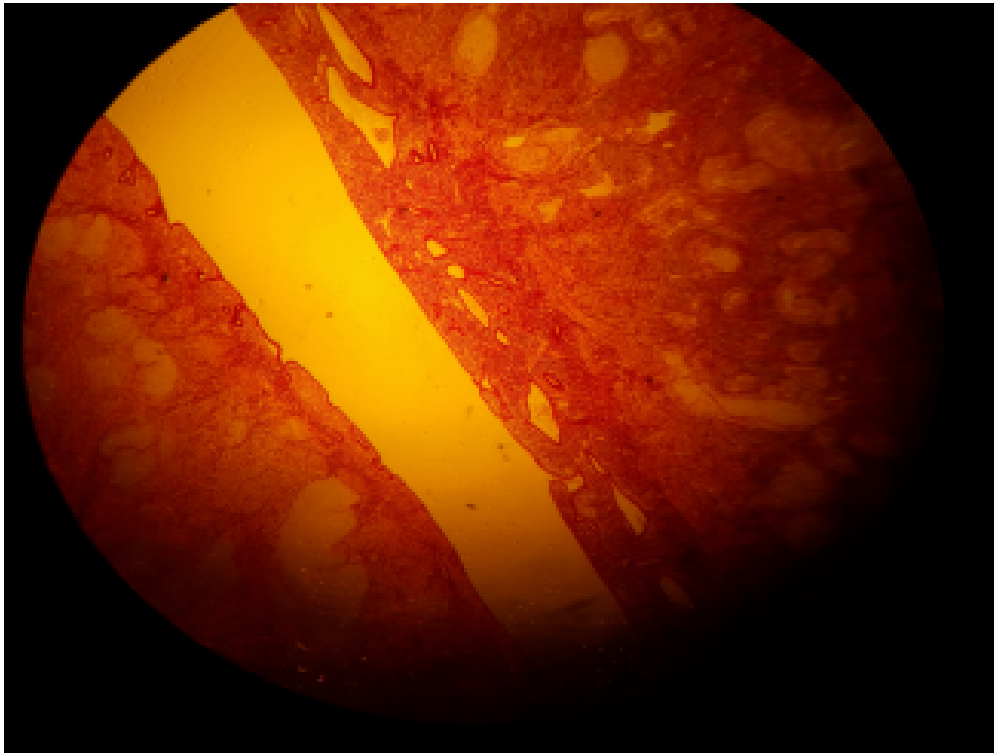


HP



SLIDE 88 UTERUS (H&E)
SIMPLE TUBULAR GLANDS

- LP NON-SECRETING

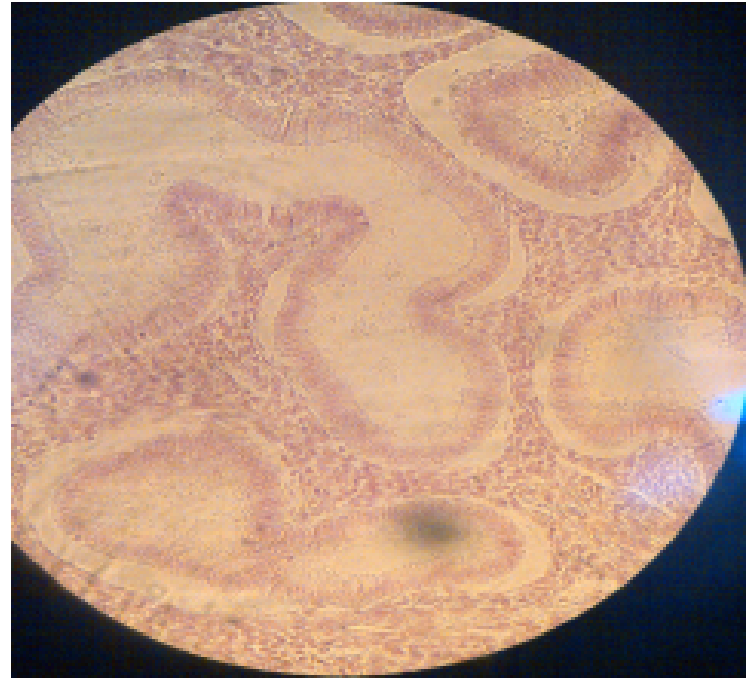
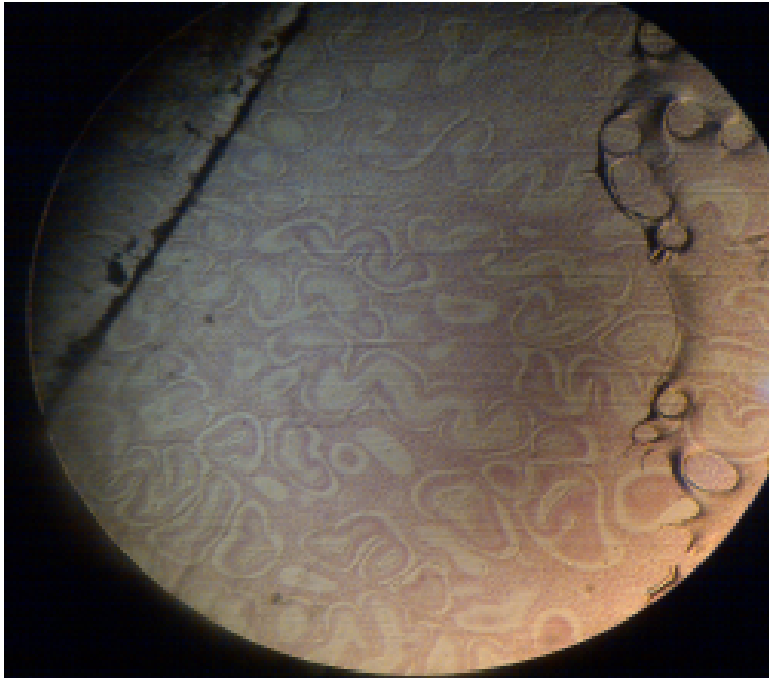


UTERUS (H&E)

SIMPLE TUBULAR GLANDS

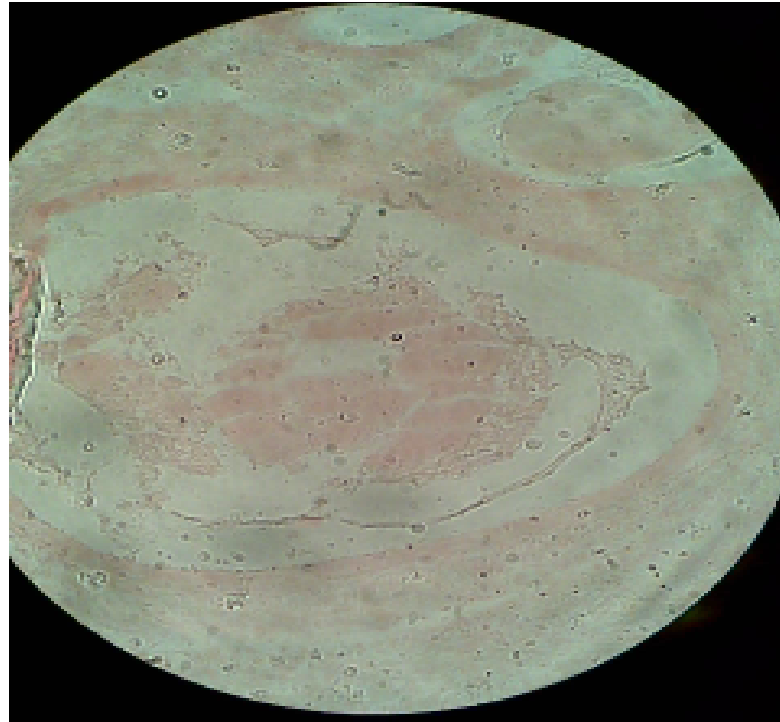
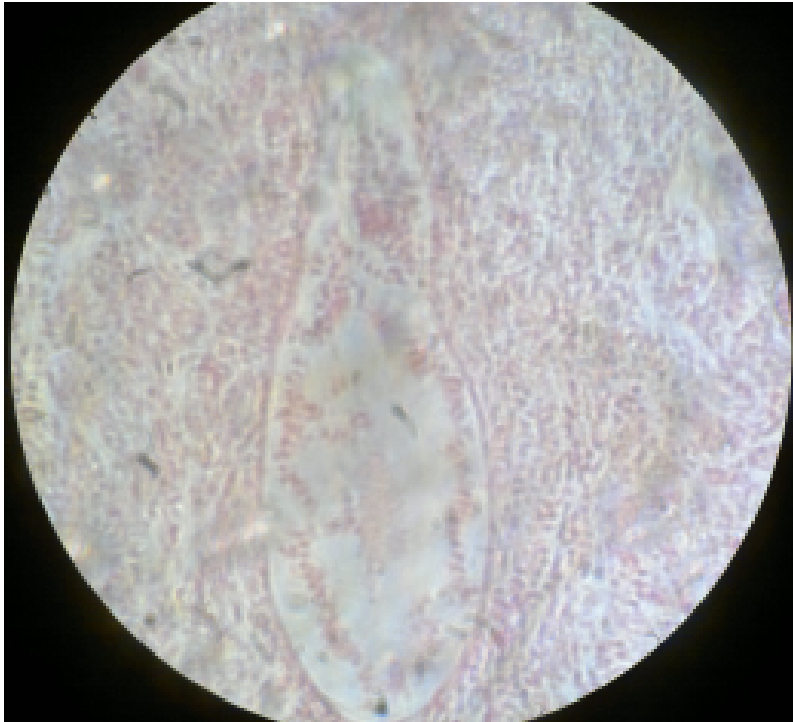
- TS:NON-SECRETING , LP

HP



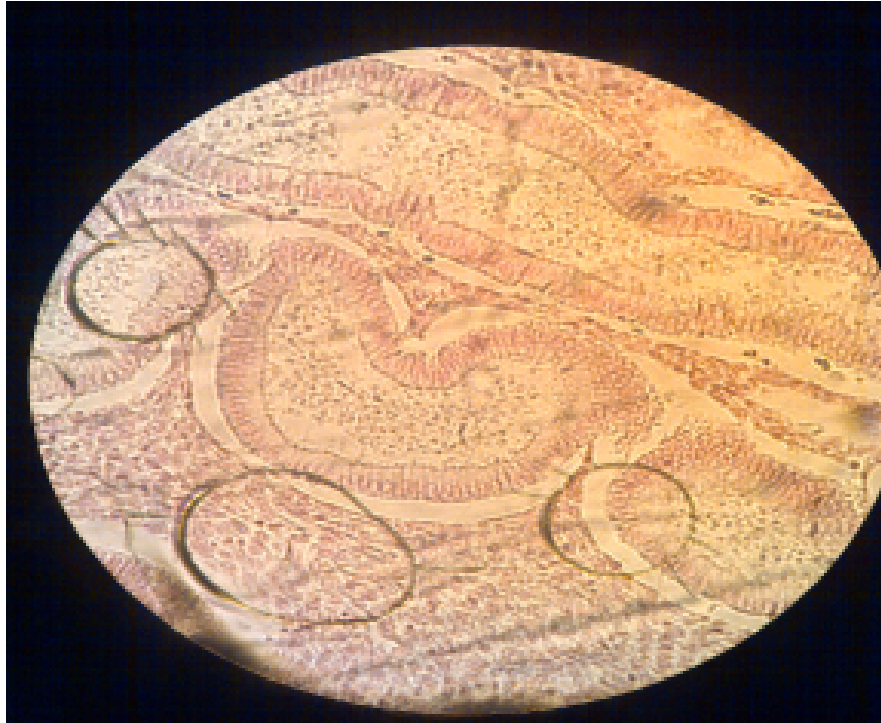SLIDE H 9.31 UTERUS-SECRETING MUCOSA (H&E) SIMPLE TUBULAR GLANDS

- LS: HP SECRETING



UTERUS-SECRETING MUCOSA (H&E) SIMPLE TUBULAR GLANDS

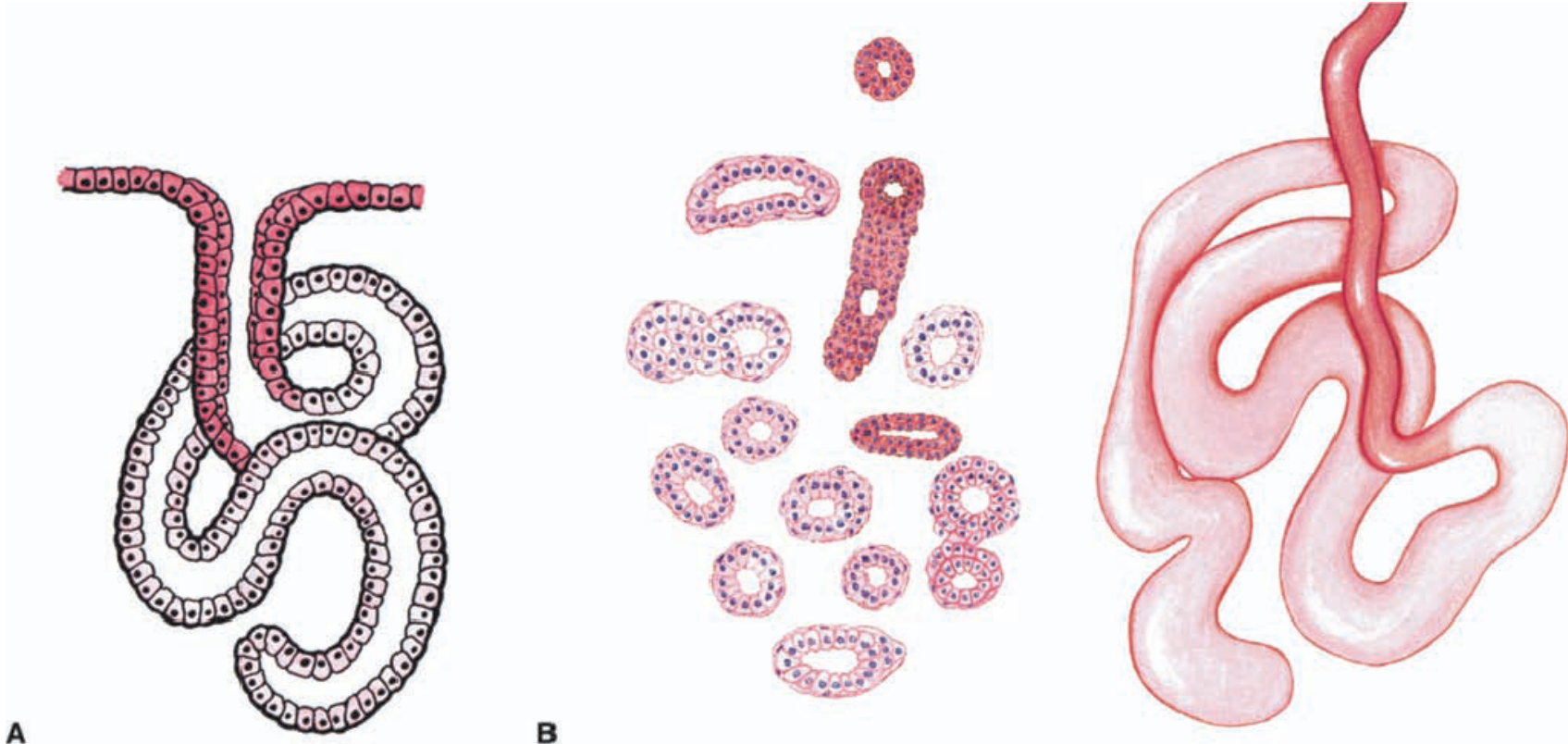
- TS: SECRETING, HP



COILED TUBULAR (EXOCRINE) GLANDS: SWEAT GLANDS

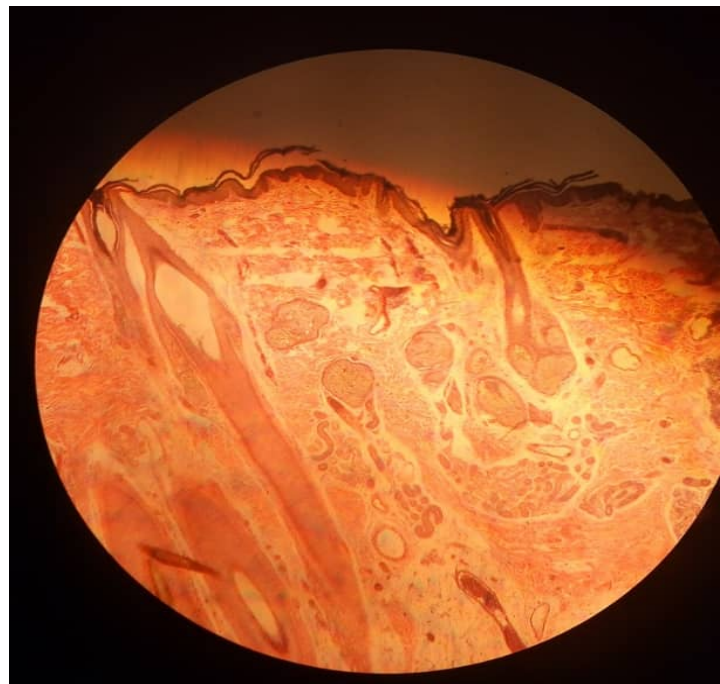
(A) DIAGRAM OF GLAND

(B) CROSS SECTION

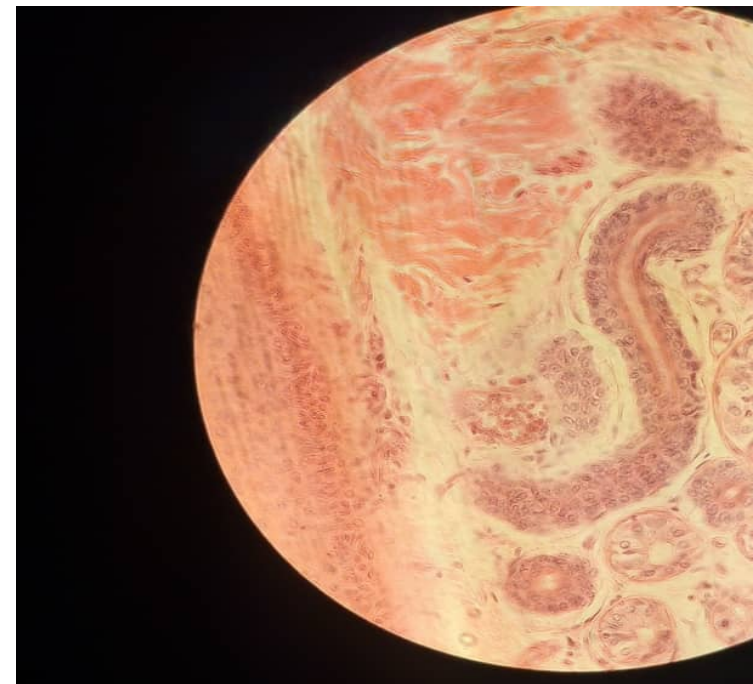


SLIDE 35 SCALP (H&E)
SIMPLE COILED TUBULAR GLANDS (MEROCRINE/ECCRINE
GLANDS)

• LP

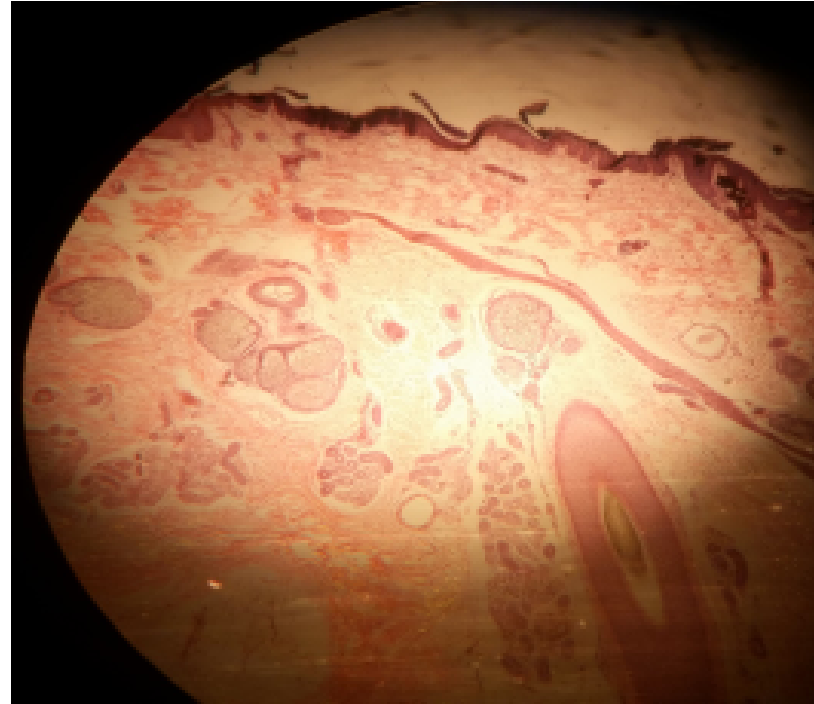
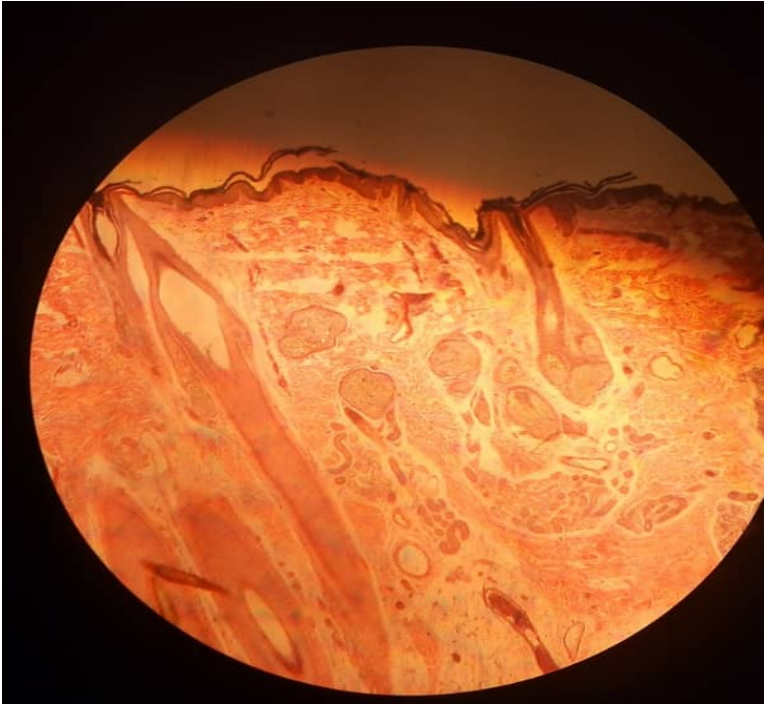


HP



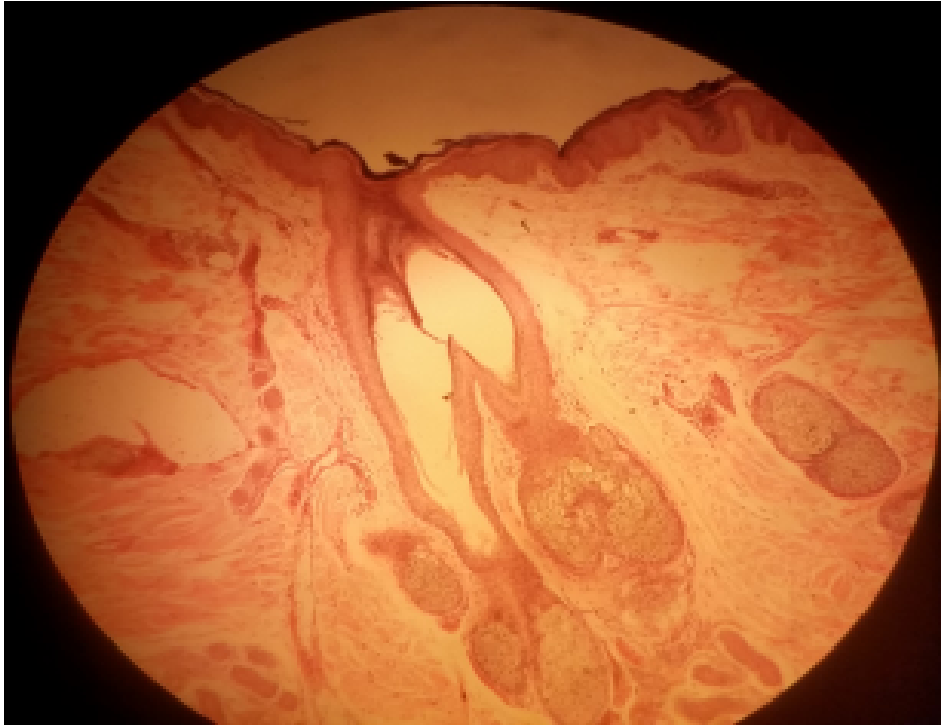
SIMPLE BRANCHED SACCULAR/ACINAR GLANDS SLIDE 35 SCALP (H&E) SEBACEOUS GLANDS

- LP

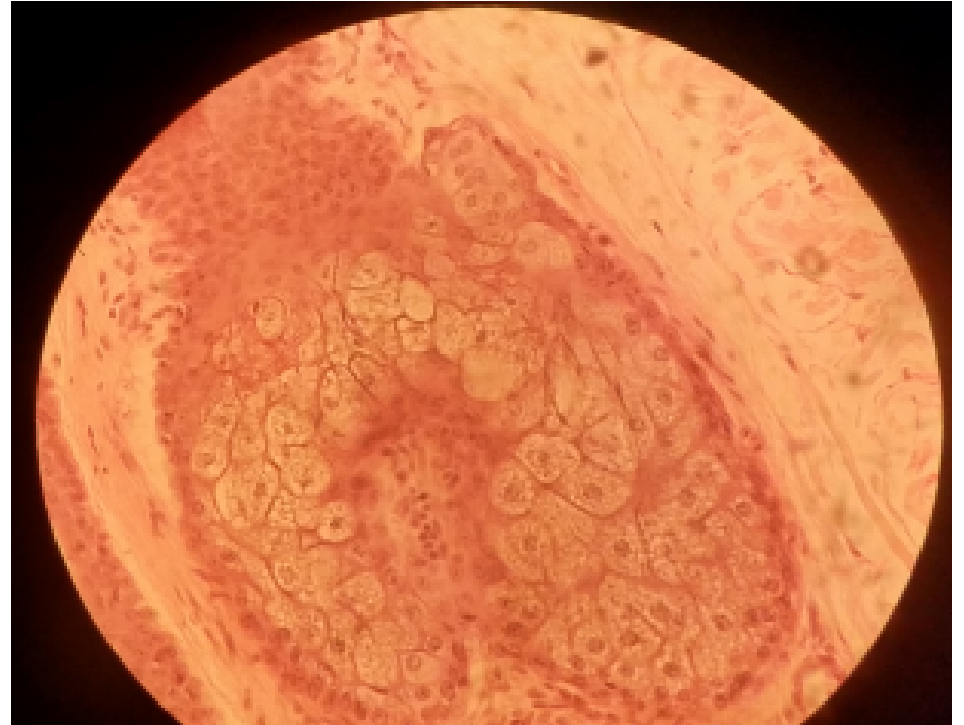


SIMPLE BRANCHED SACCULAR/ACINAR GLANDS
SLIDE 35 SCALP (H&E) SEBACEOUS GLANDS
(HOLOCRINE MODE OF SECRETION)

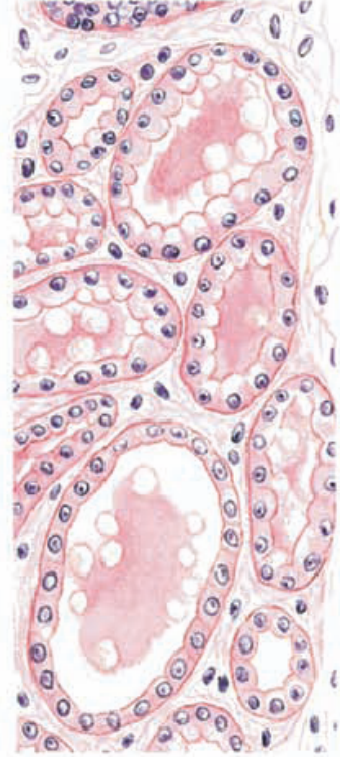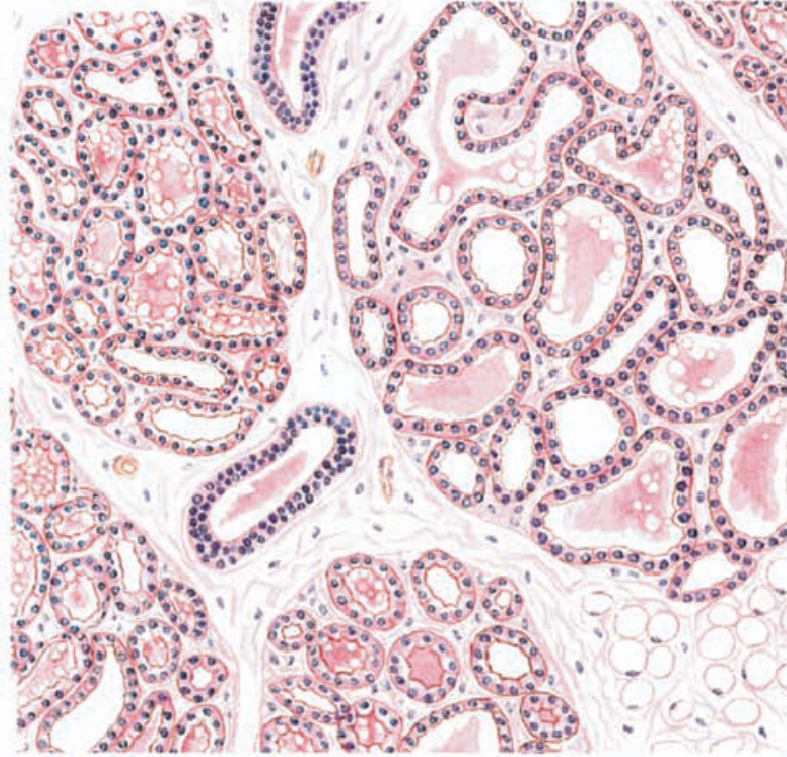
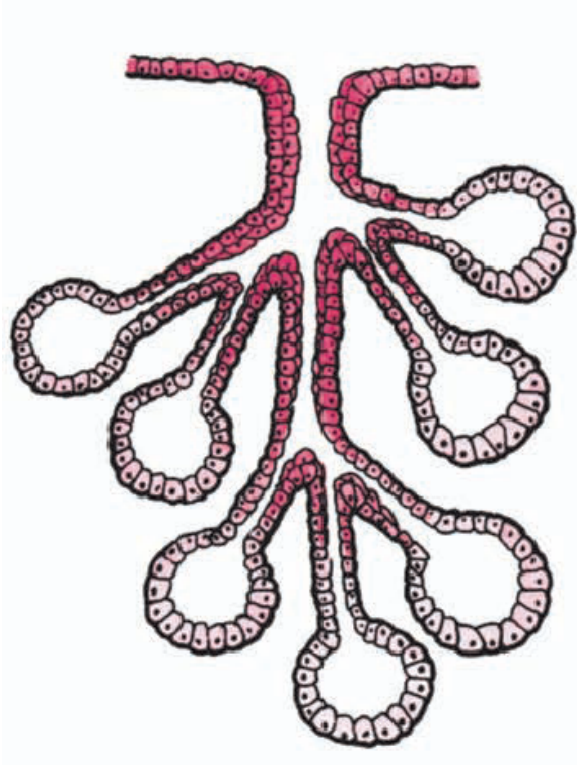
• MP



HP

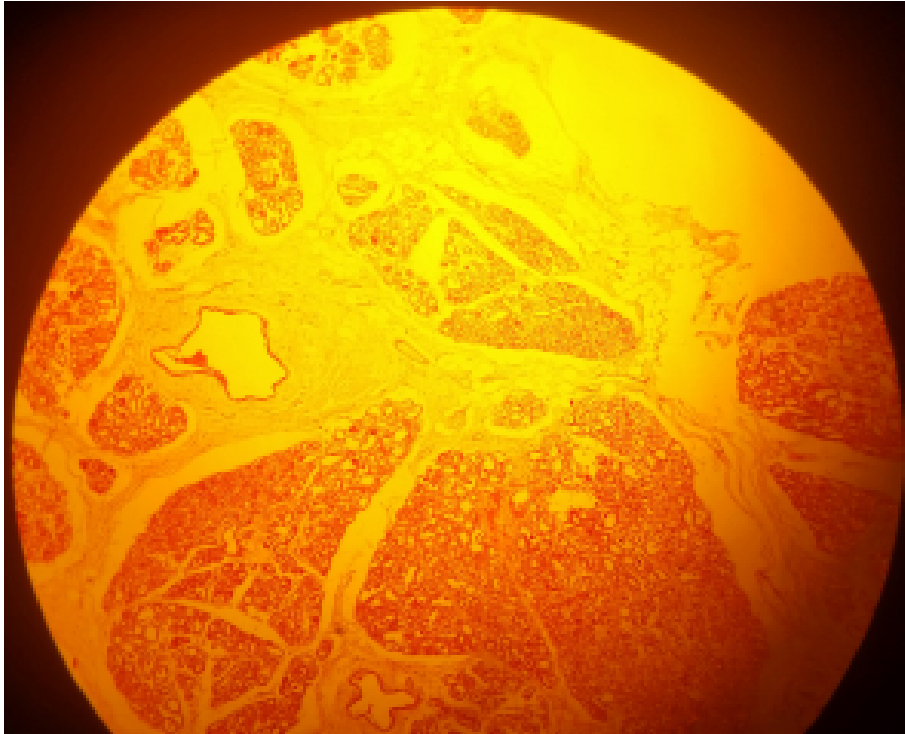


COMPOUND ACINAR (EXOCRINE) GLAND: MAMMARY GLAND (H&E)
(A) DIAGRAM OF GLAND
(B) DURING LACTATION

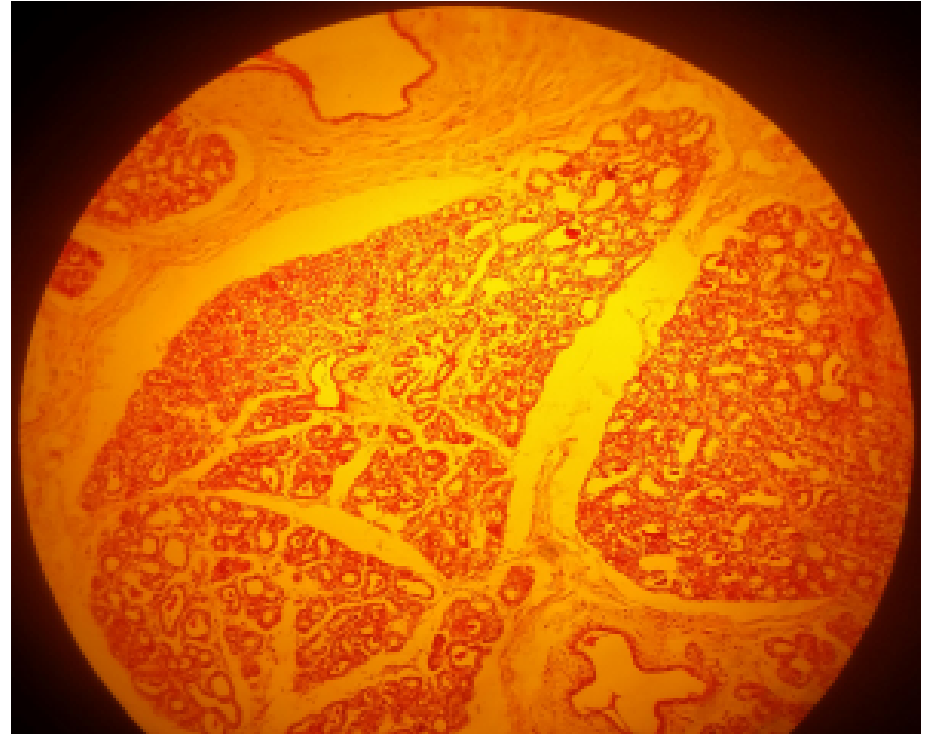


COMPOUND AVEOLAR GLANDS
SLIDE 95 BREAST (MAMMARY GLAND) (H&E)
NON-LACTATING

• LP

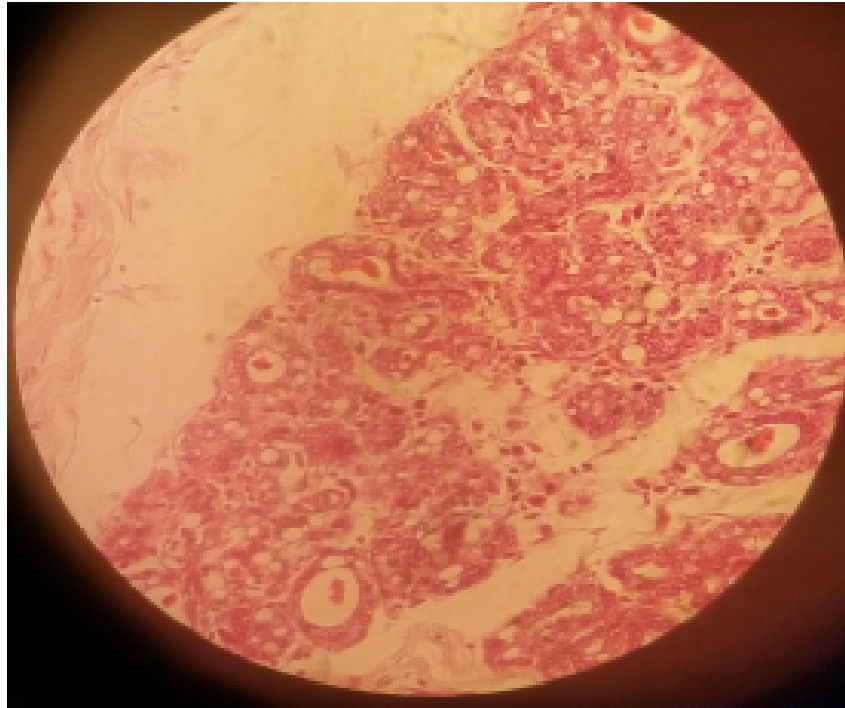


MP



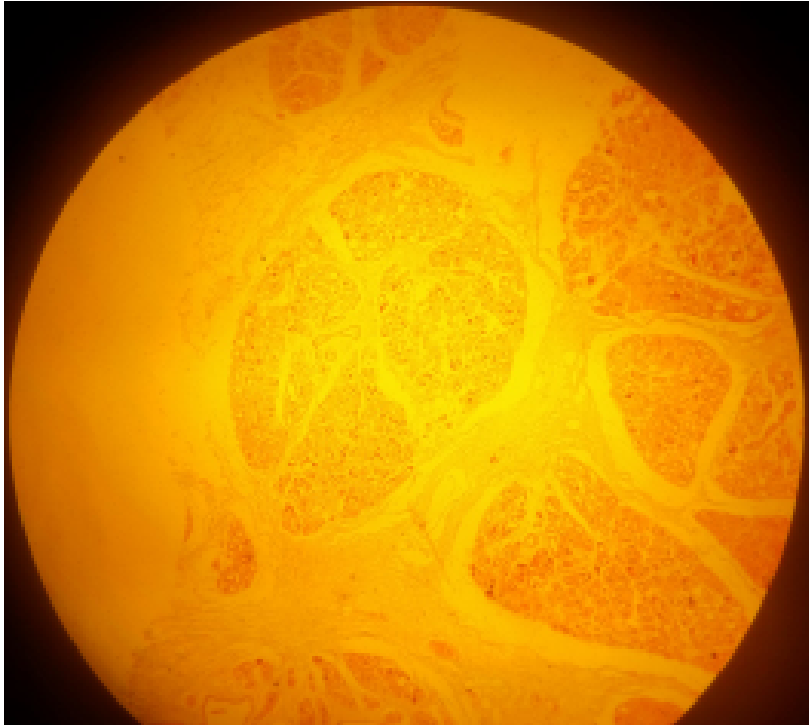
COMPOUND AVEOLAR GLANDS
SLIDE 95 BREAST (MAMMARY GLAND) (H&E)
NON-LACTATING

- HP

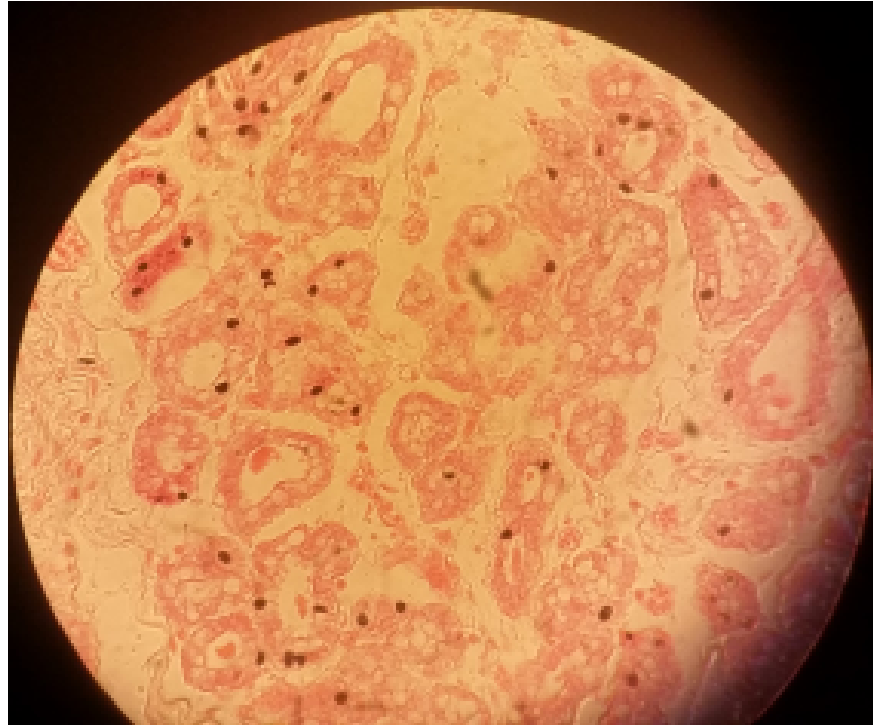

COMPOUND AVEOLAR/ACINAR GLANDS
SLIDE H9.352 BREAST (MAMMARY GLAND) (H&E)
LACTATING (APOCRINE MODE OF SECRETION)

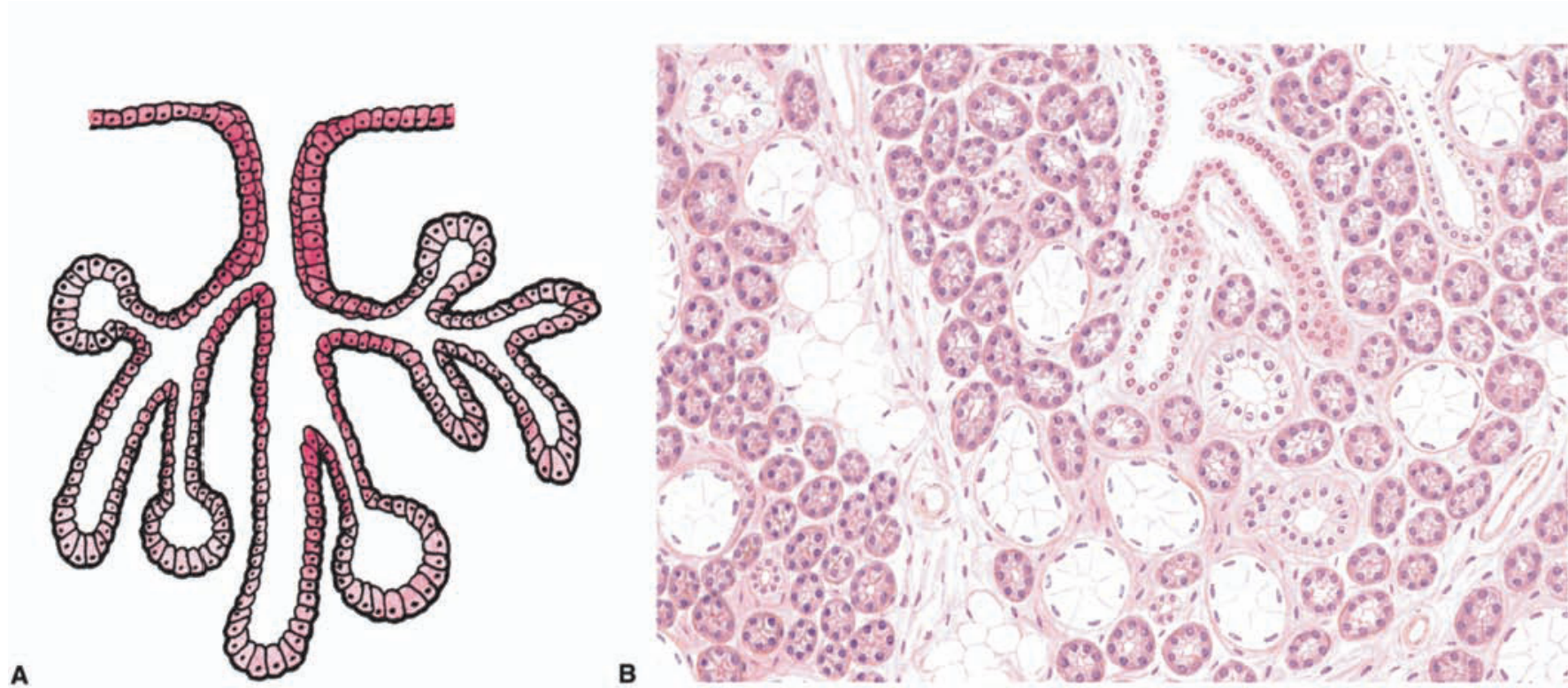
• LP



HP

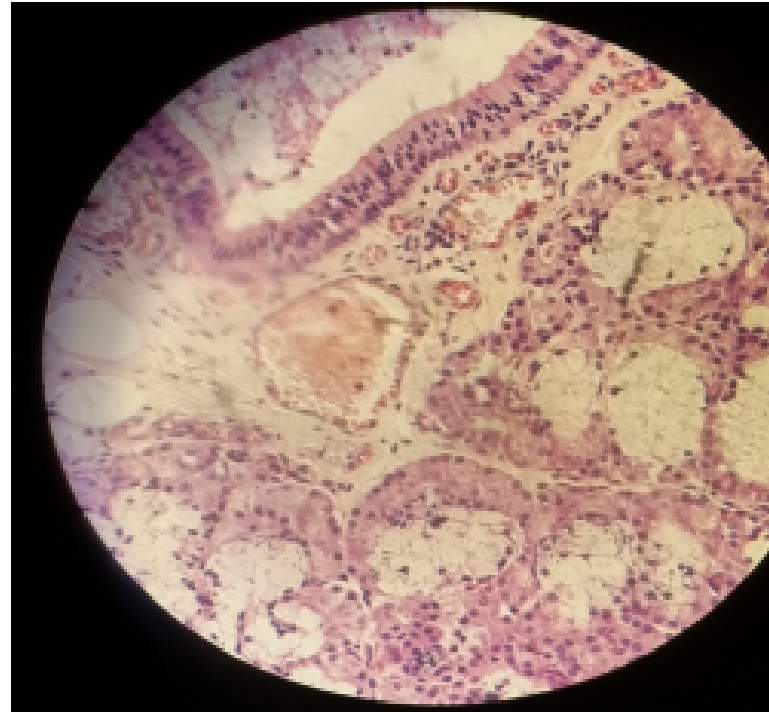
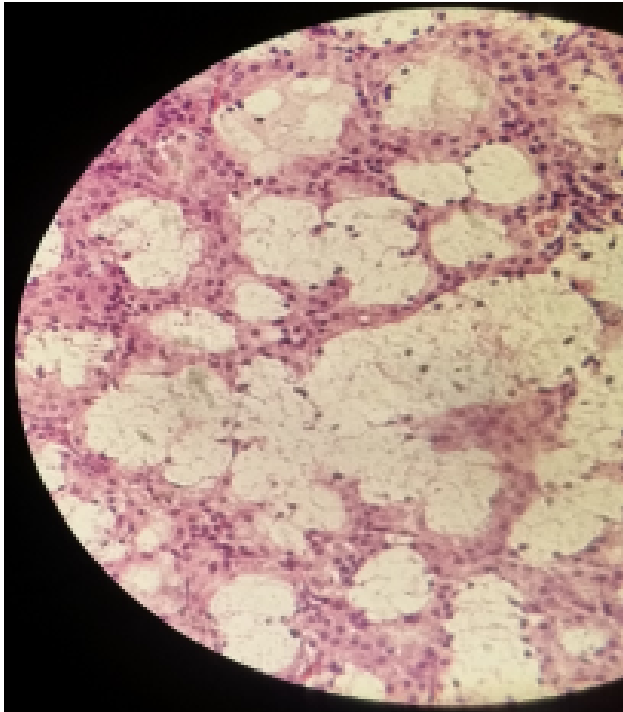


COMPOUND TUBULOACINAR (EXOCRINE) GLAND



COMPOUND TUBULOACINAR (EXOCRINE) GLANDS: SEROUS AND
MUCOUS ACINI
SLIDE 48 SUBLINGUAL GLAND (MALLORY)
(MEROCRINE MODE OF SECRETION)

- HP



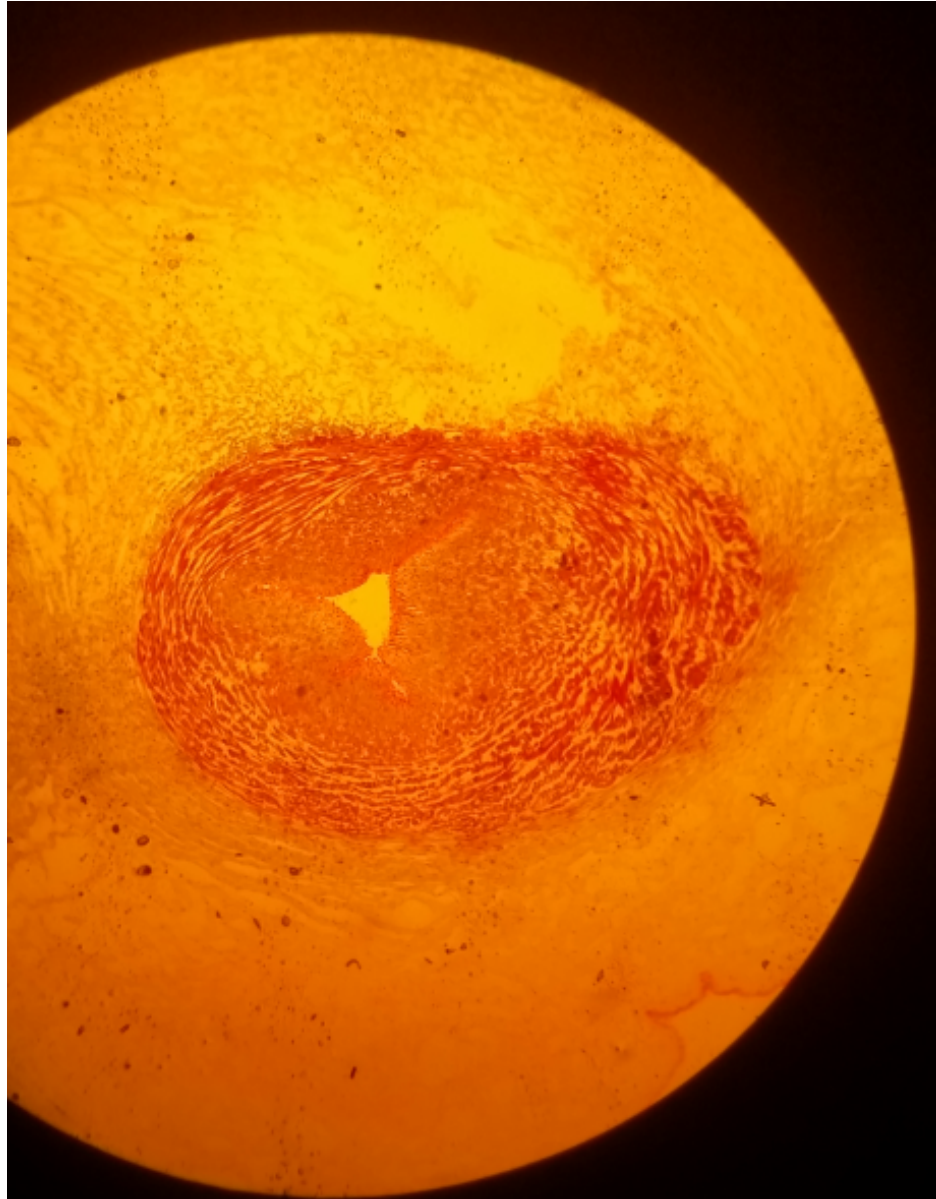
CONNECTIVE TISSUE PROPER

PRACTICAL 5

Mucous connective tissue

Slide 2: Umbilical cord (Gomori)

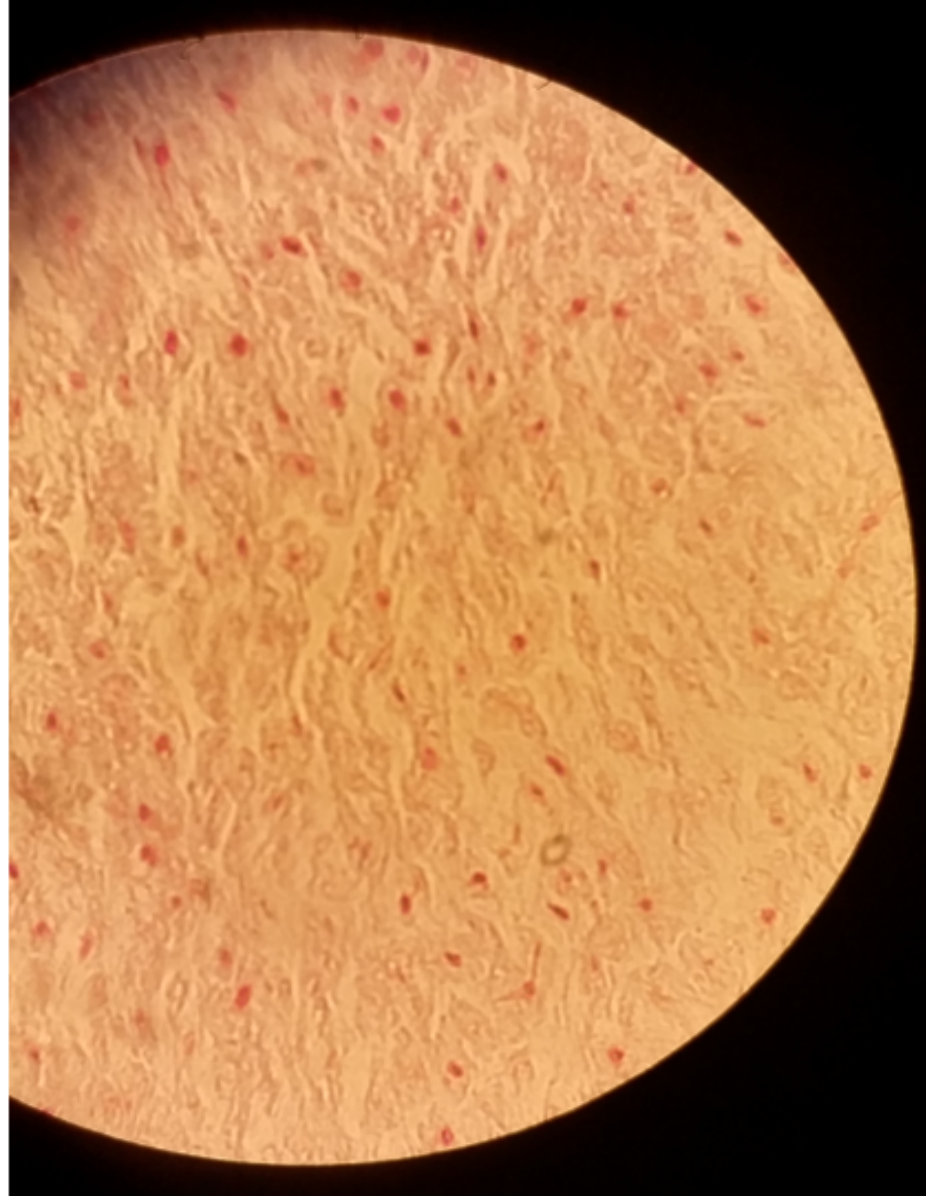
LP




Mucous connective tissue

Slide 2: Umbilical cord (Gomori)

- HP

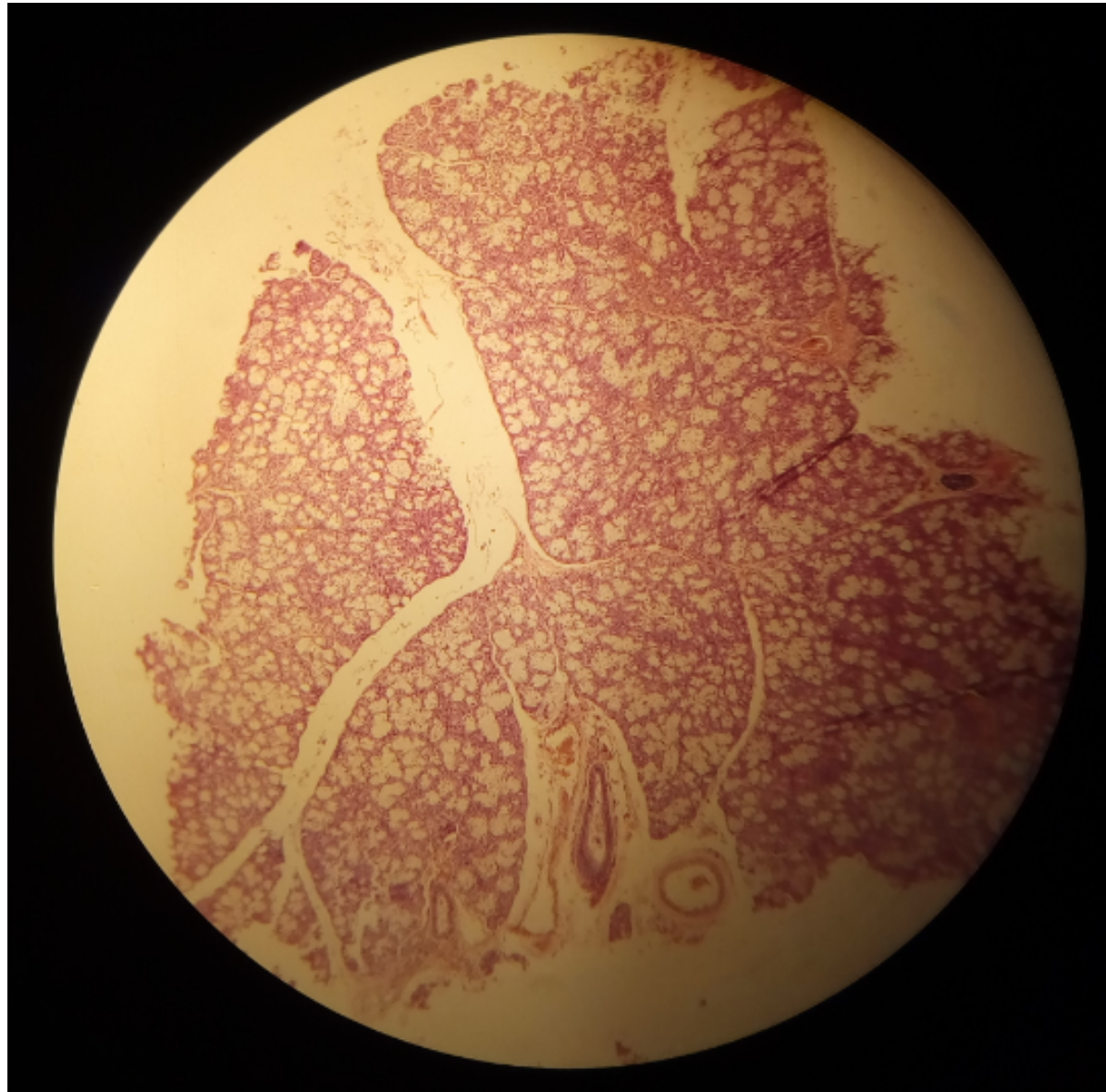




Dense, irregular CT

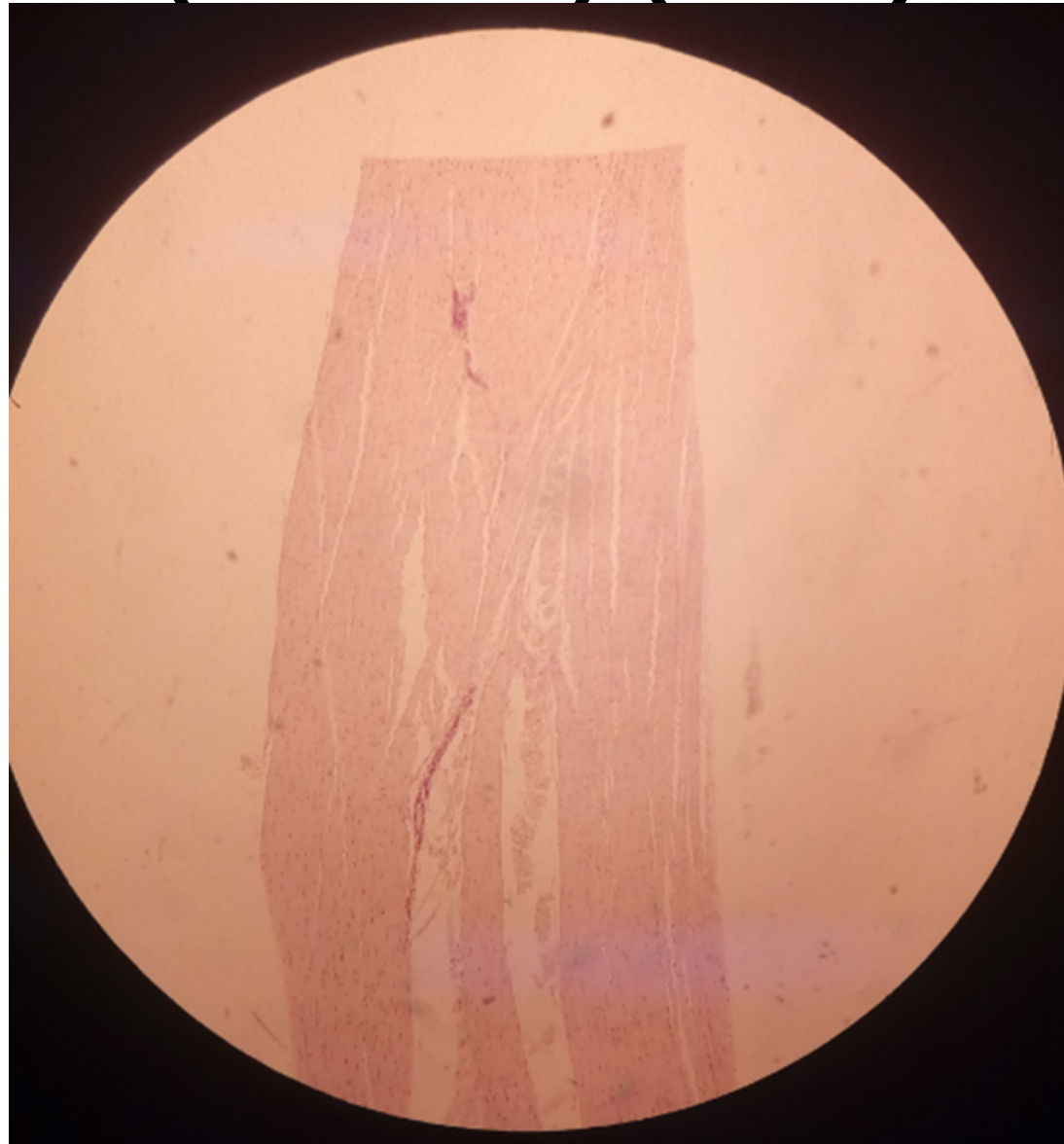
Slide 48: Sublingual gland (Mallory)

- LP



Dense, regular CT
Slide H2 11: White fibrous tissue
(Tendon) (H&E)

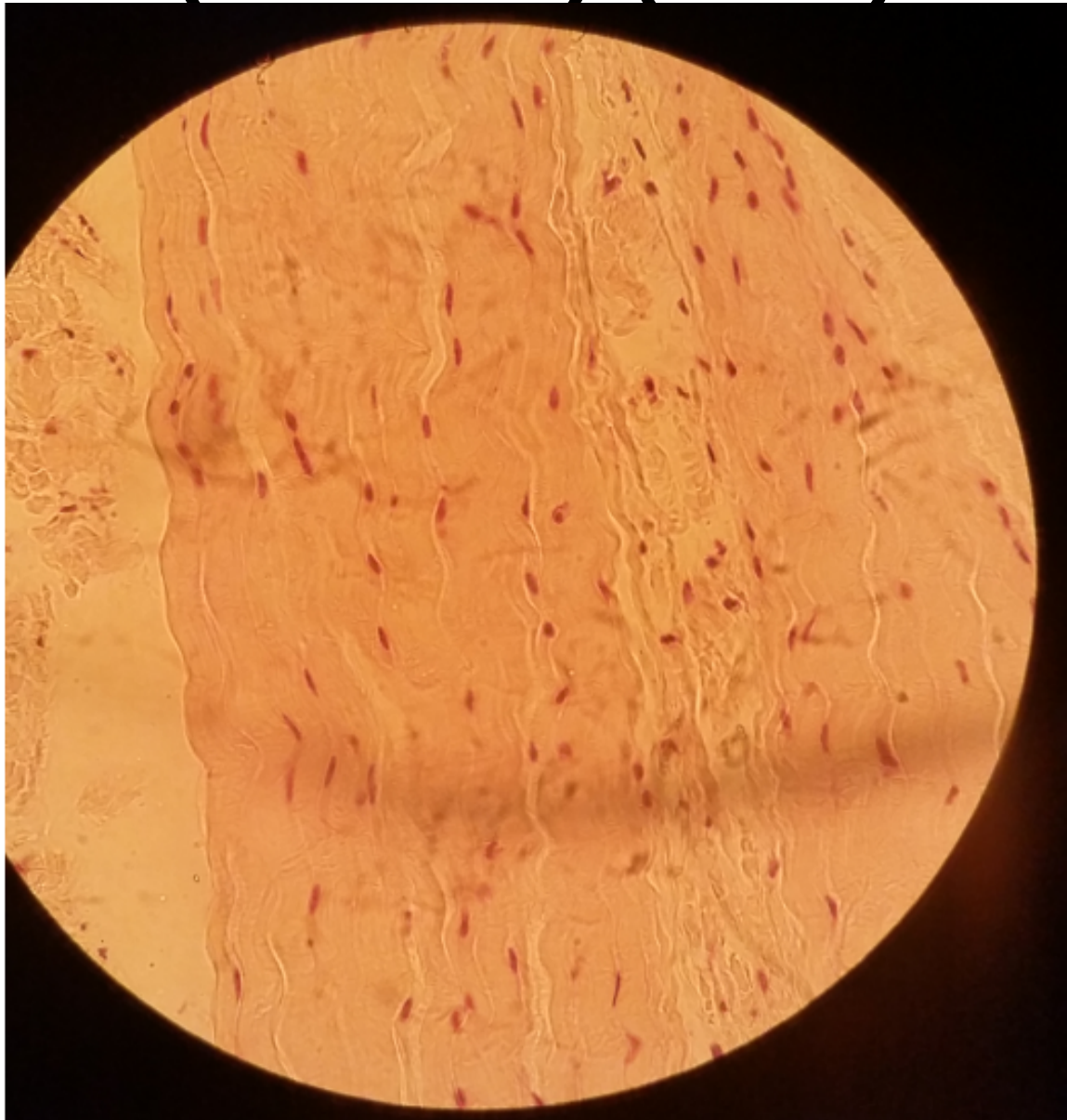
- LP



Dense, regular CT

Slide H2 11: White fibrous tissue (Tendon) (H&E)

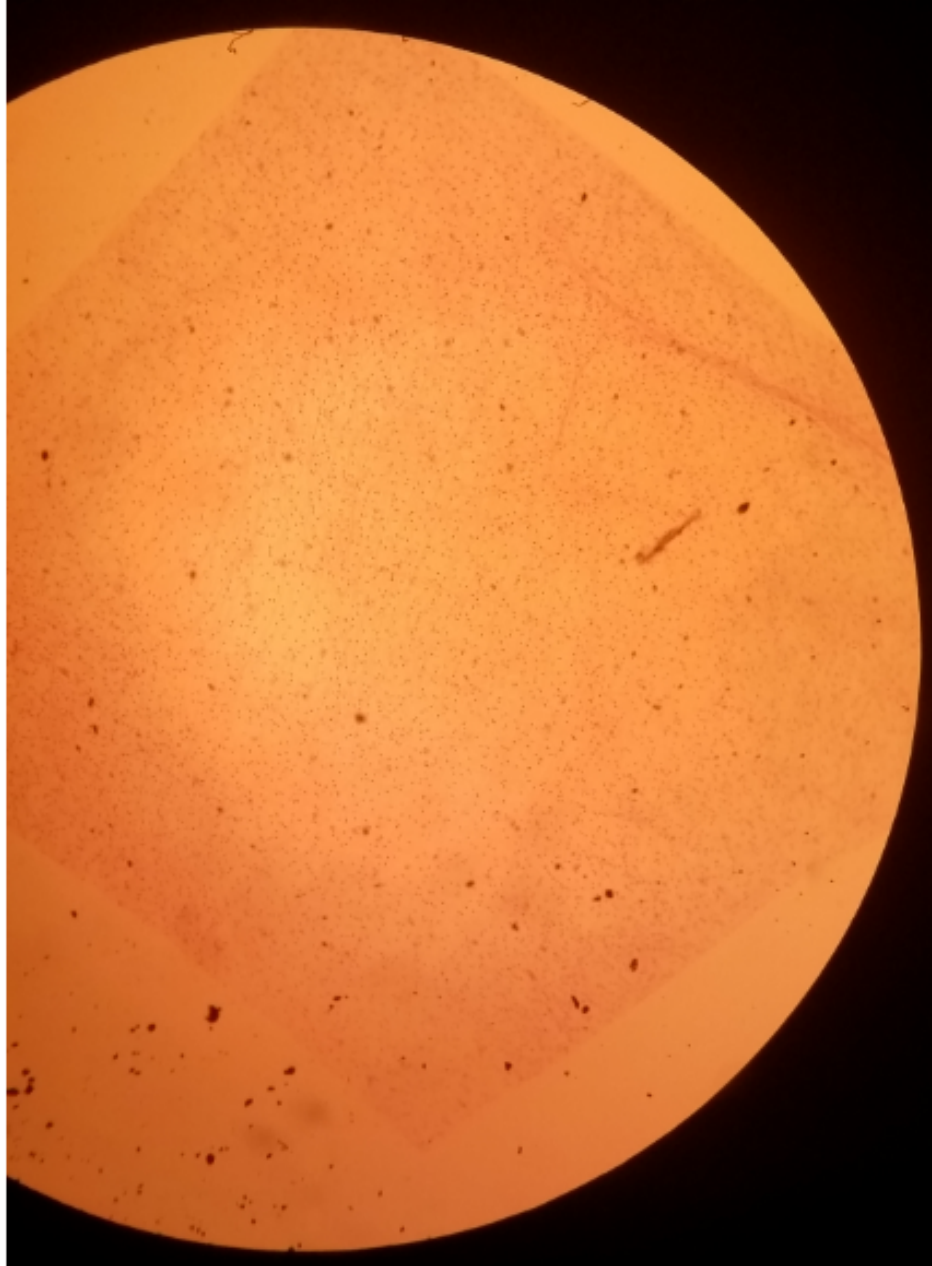
- HP



Loose (areolar) connective tissue

Slide H2.13 tissue spread

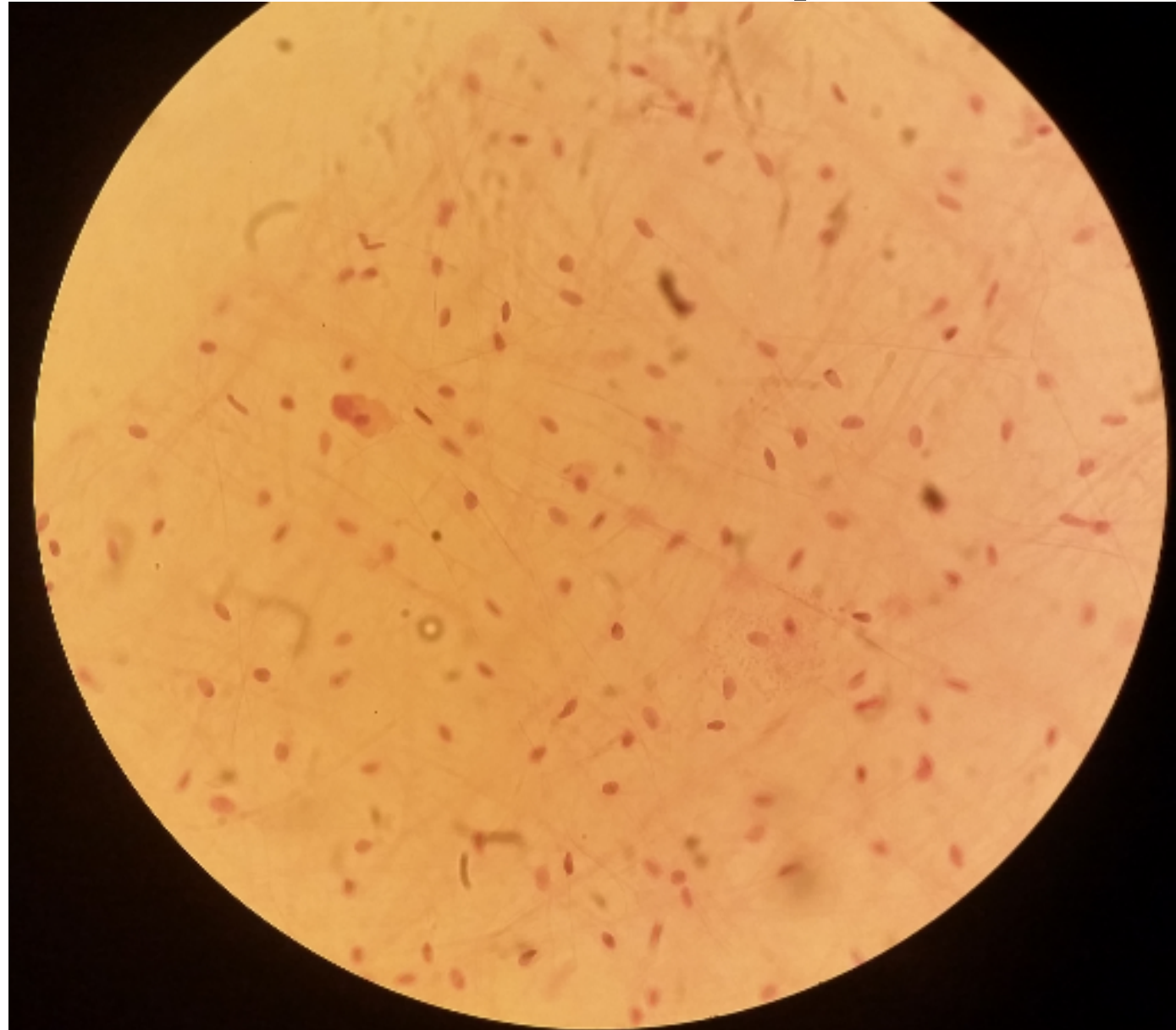
- LP



Loose (areolar) connective tissue

Slide H2.13 tissue spread

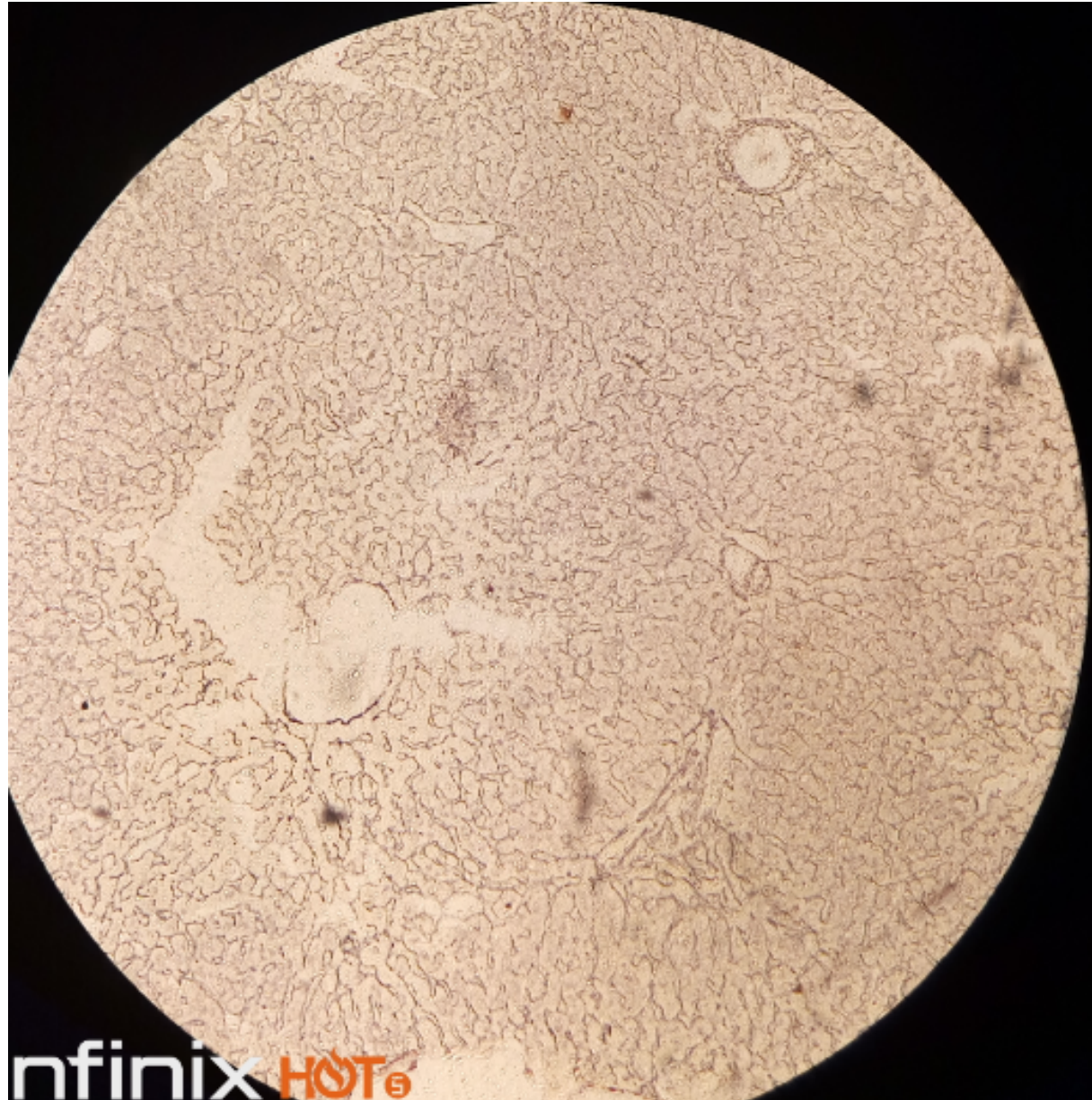
- HP



Reticular fibres

Slide 63 silver stain liver

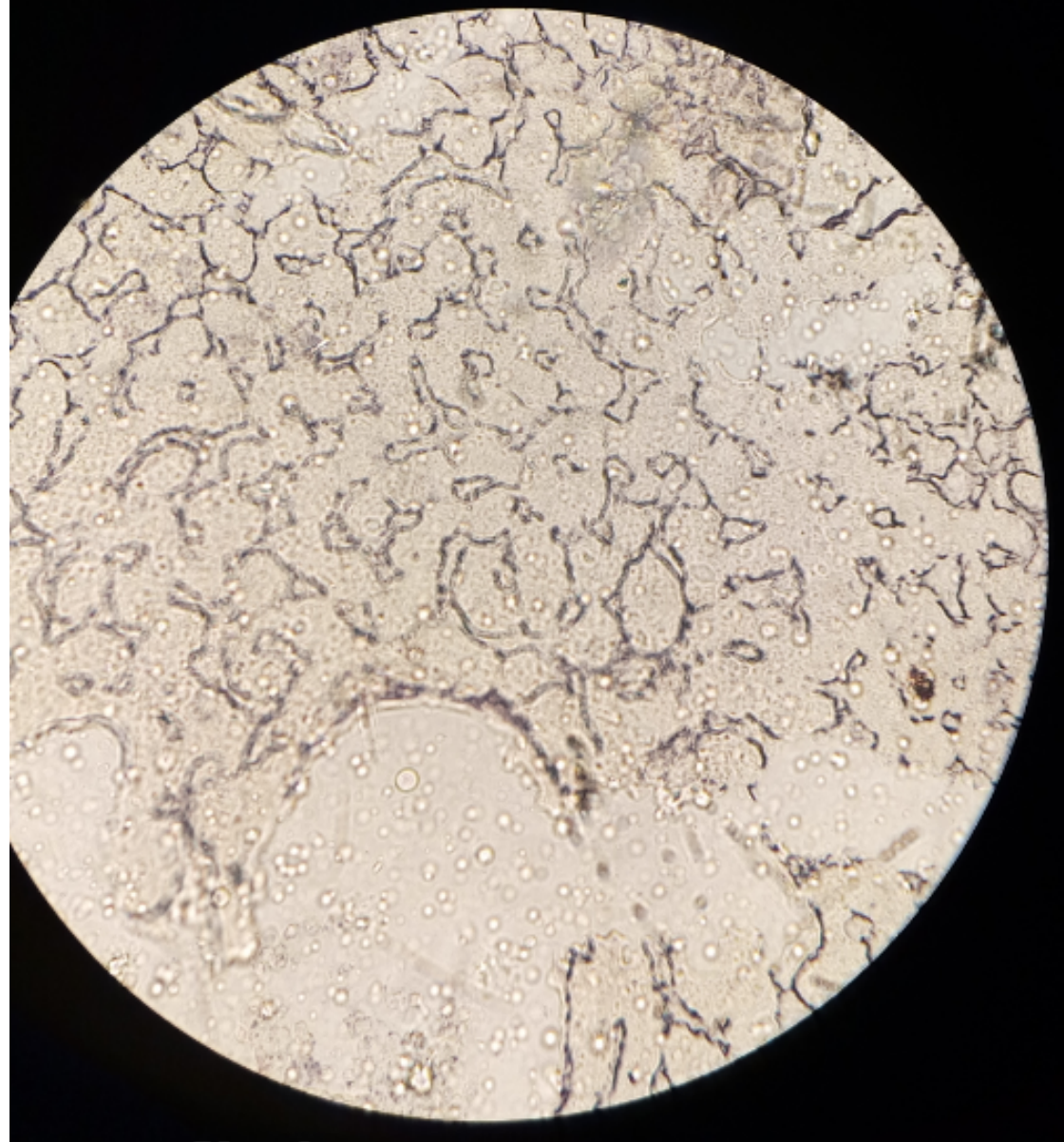
- Lp



Reticular fibres

Slide 63 silver stain liver

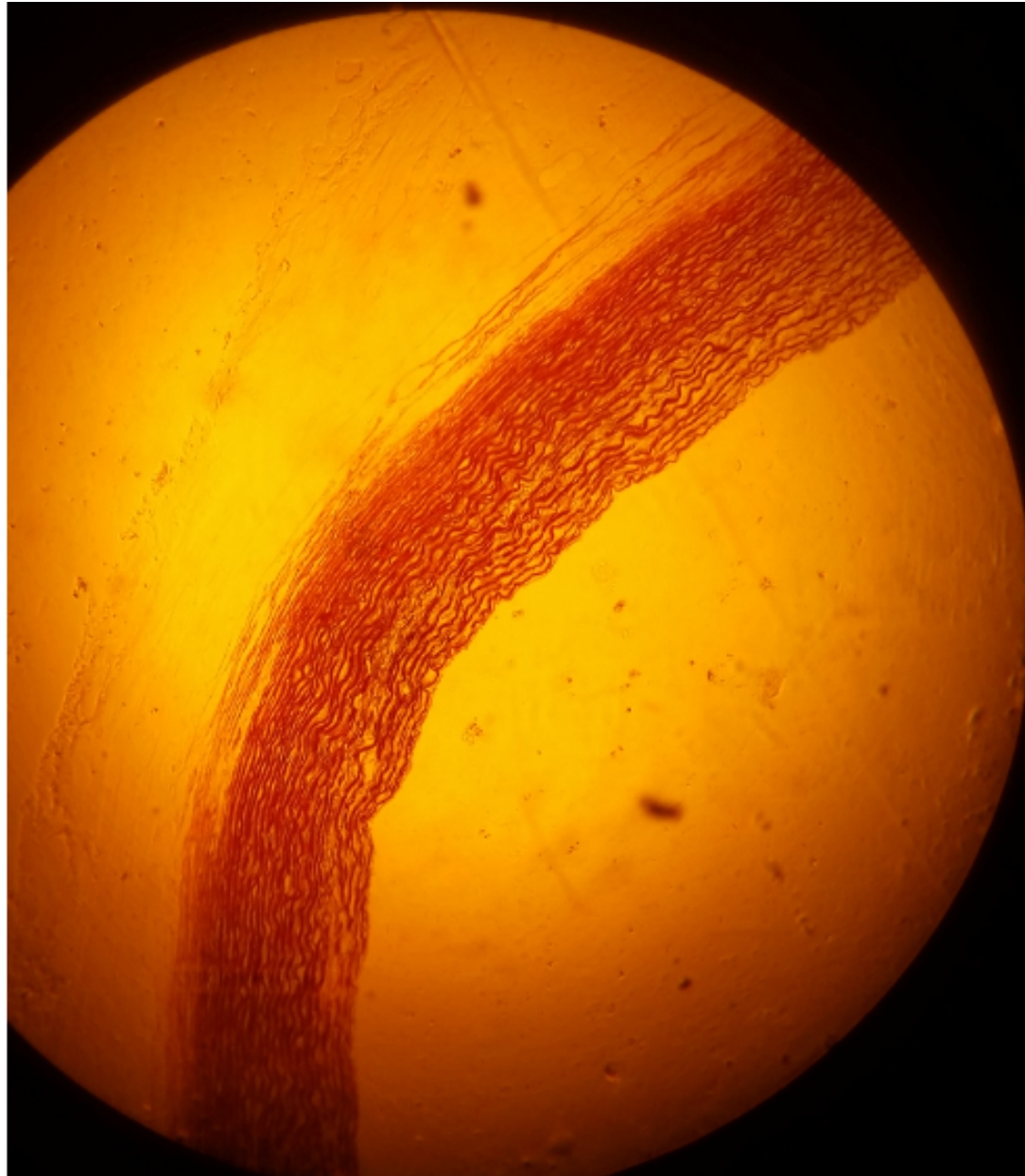
- Hp



Elastic tissue

Slide H2.63

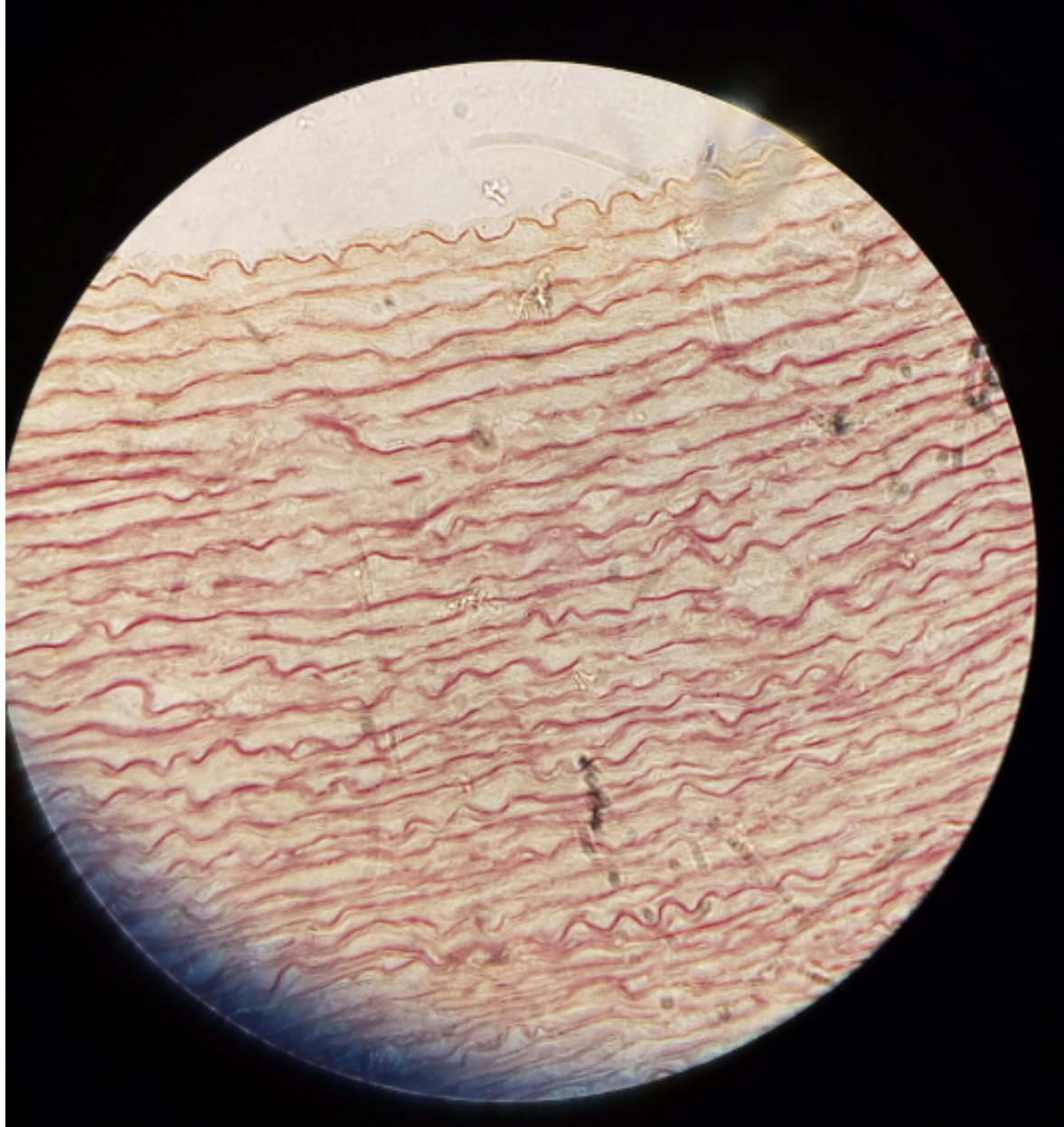
- LP



Elastic tissue

Slide H2.63

- Hp



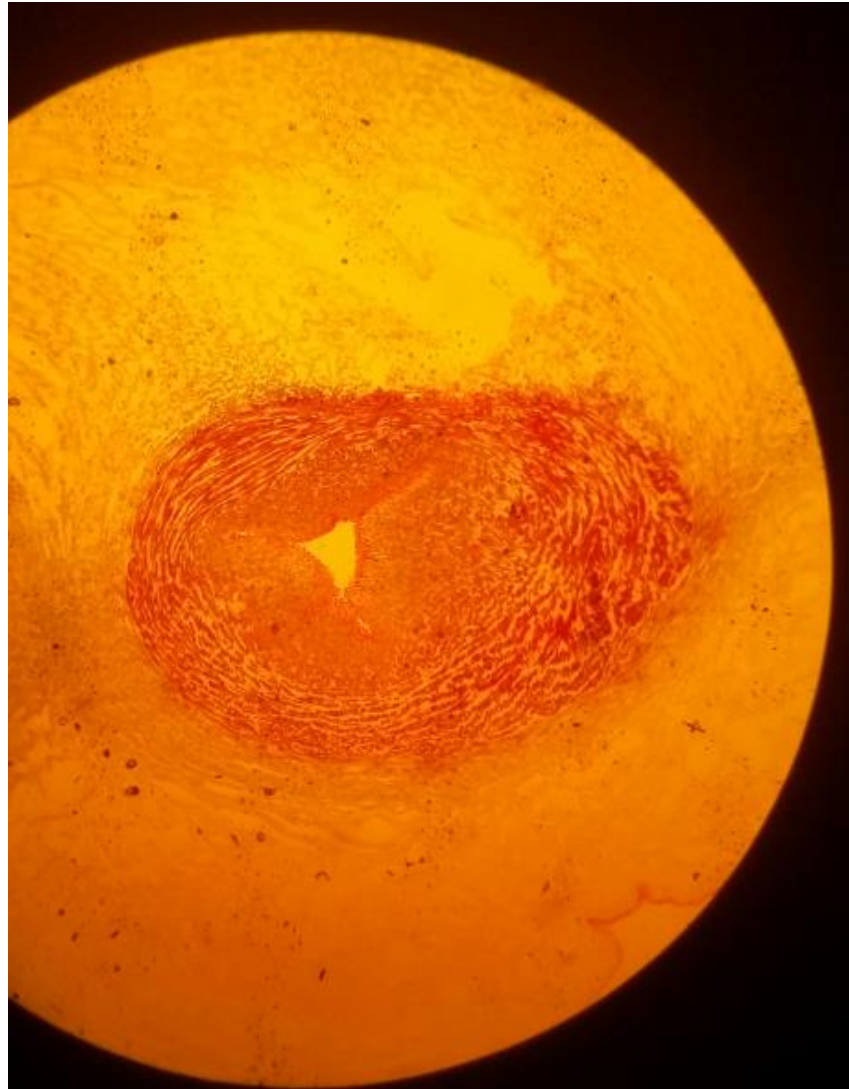
CONNECTIVE TISSUE PROPER

PRACTICAL 5

Mucous connective tissue

Slide 2: Umbilical cord (Gomori)

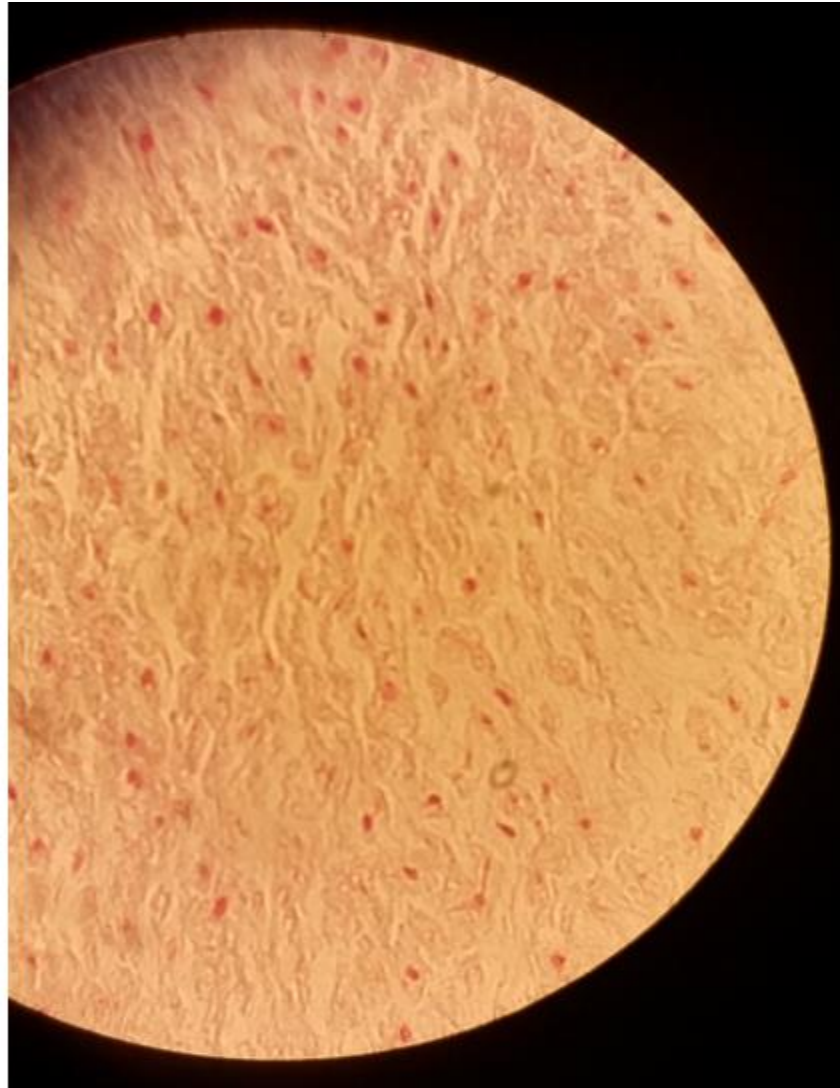
LP

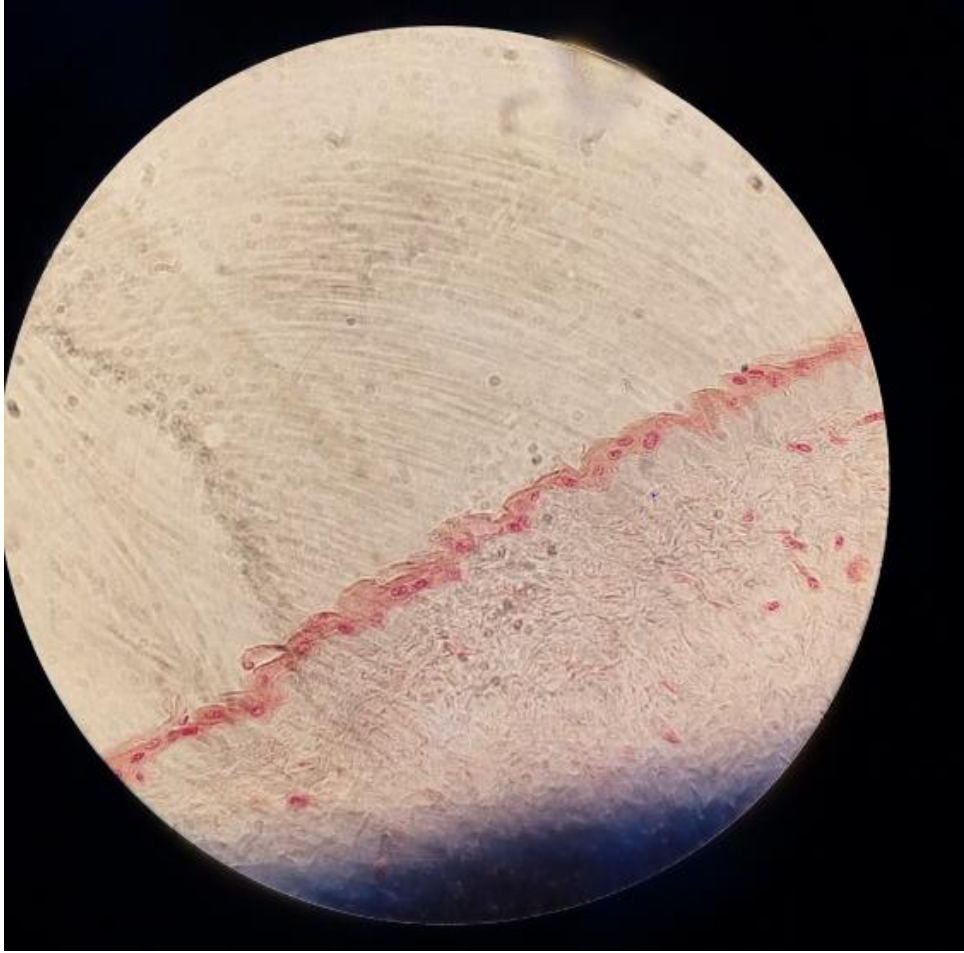


Mucous connective tissue

Slide 2: Umbilical cord (Gomori)

- HP

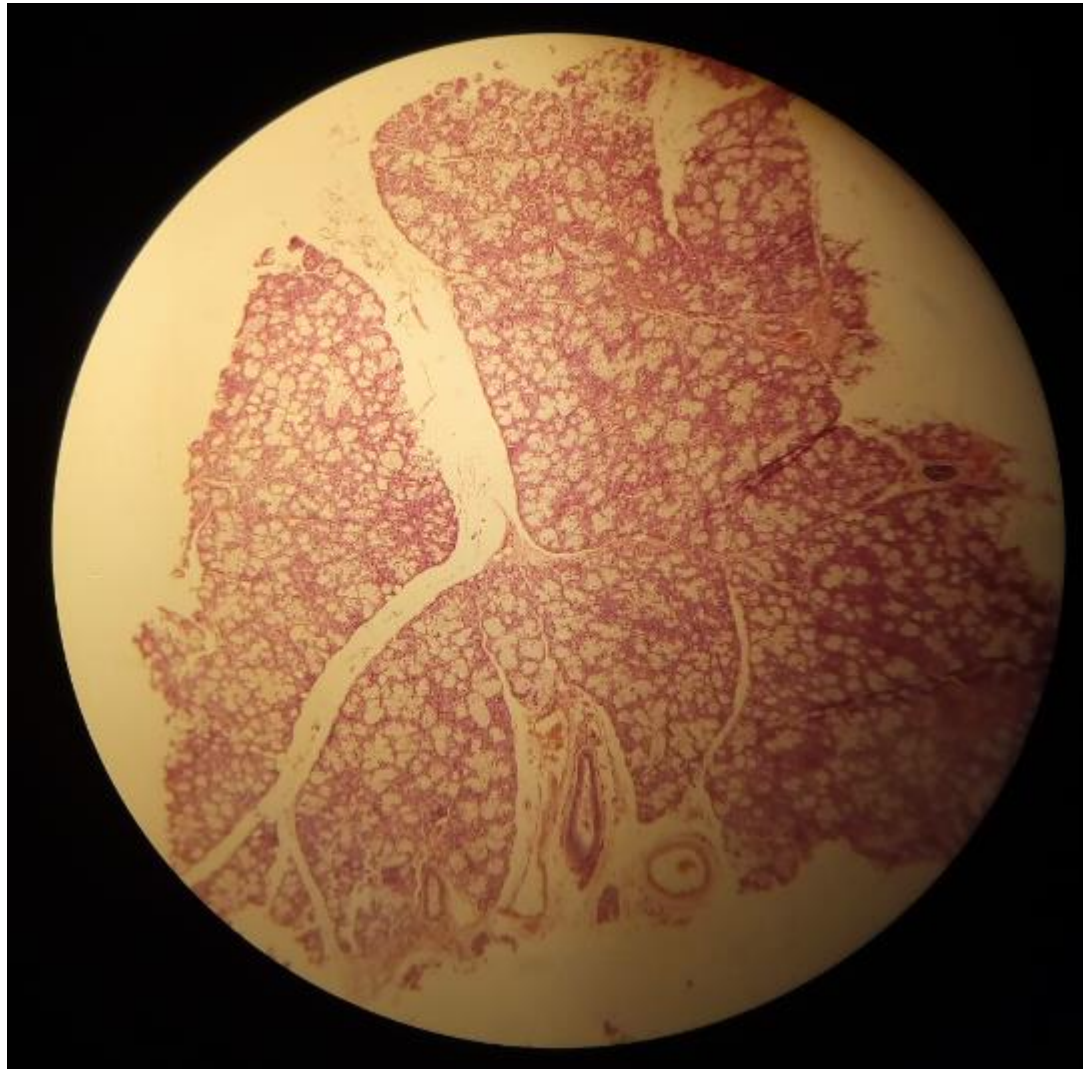



Dense, irregular CT

Slide 48: Sublingual gland (Mallory)

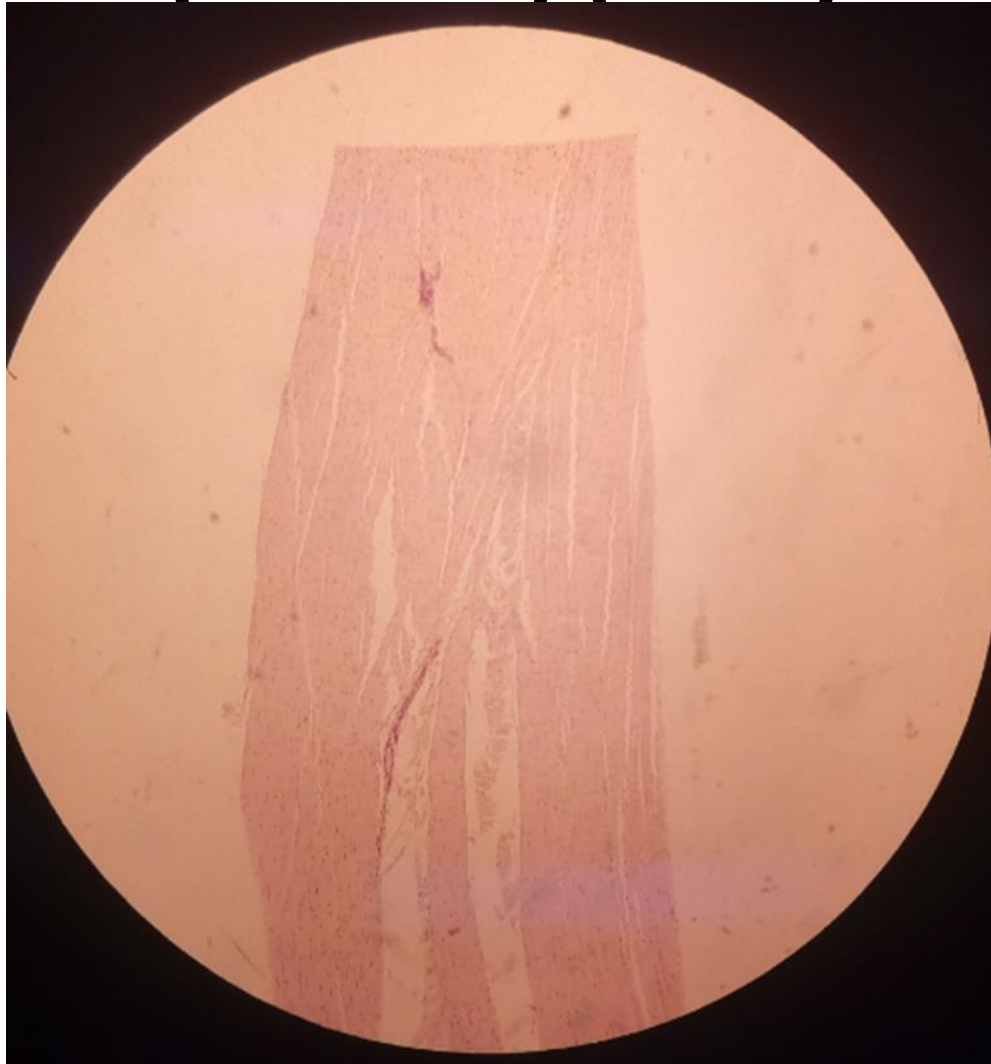- LP



Dense, regular CT

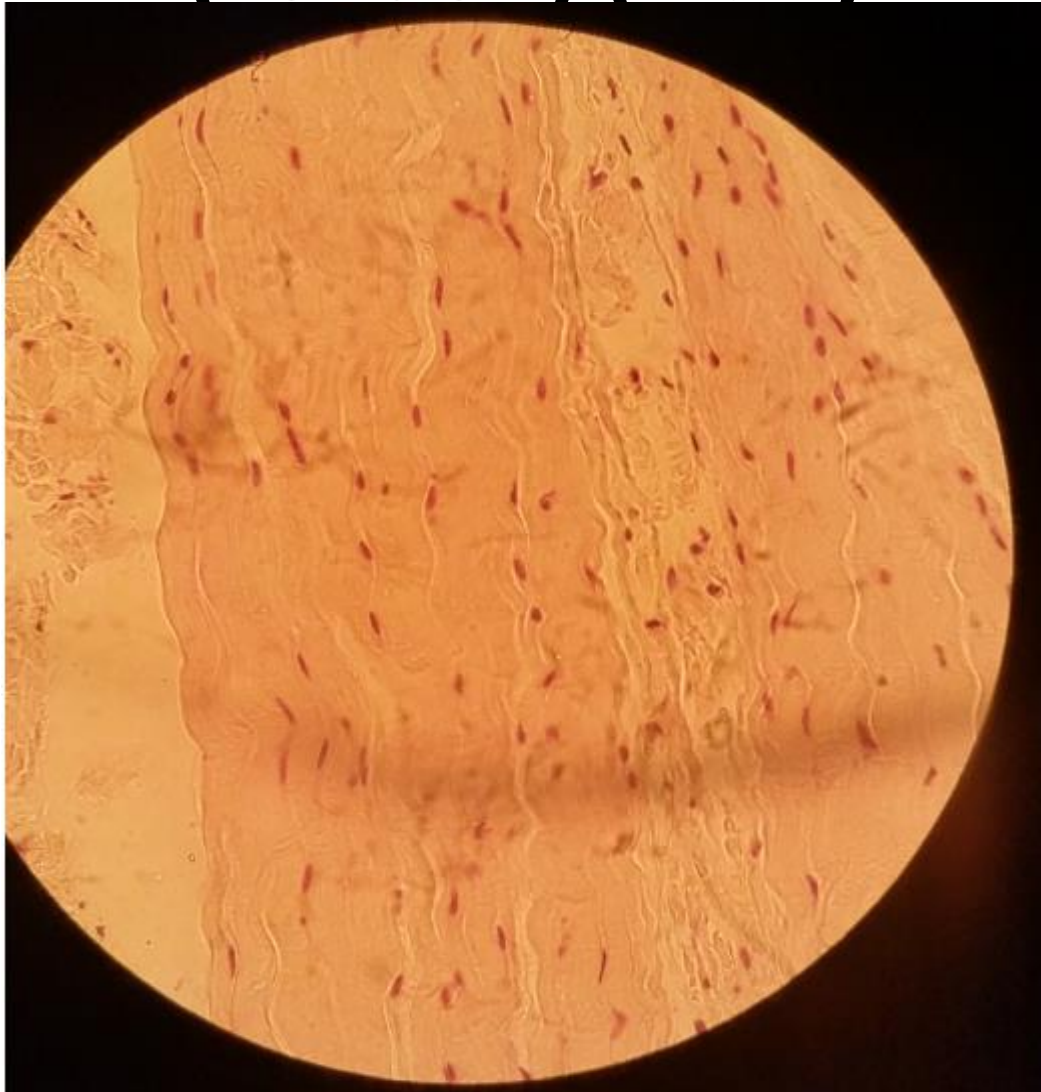
Slide H2 11: White fibrous tissue (Tendon) (H&E)

- LP



Dense, regular CT
Slide H2 11: White fibrous tissue
(Tendon) (H&E)

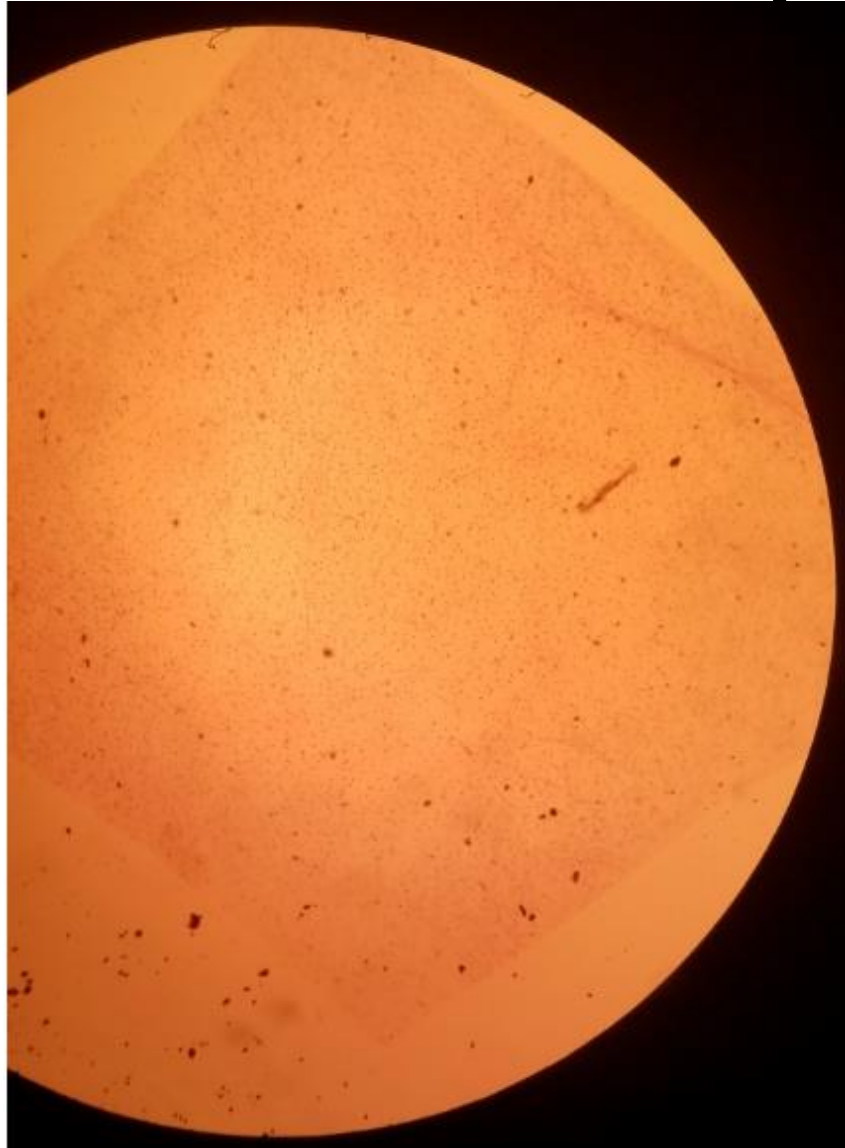
- **HP**



Loose (areolar) connective tissue

Slide H2.13 tissue spread

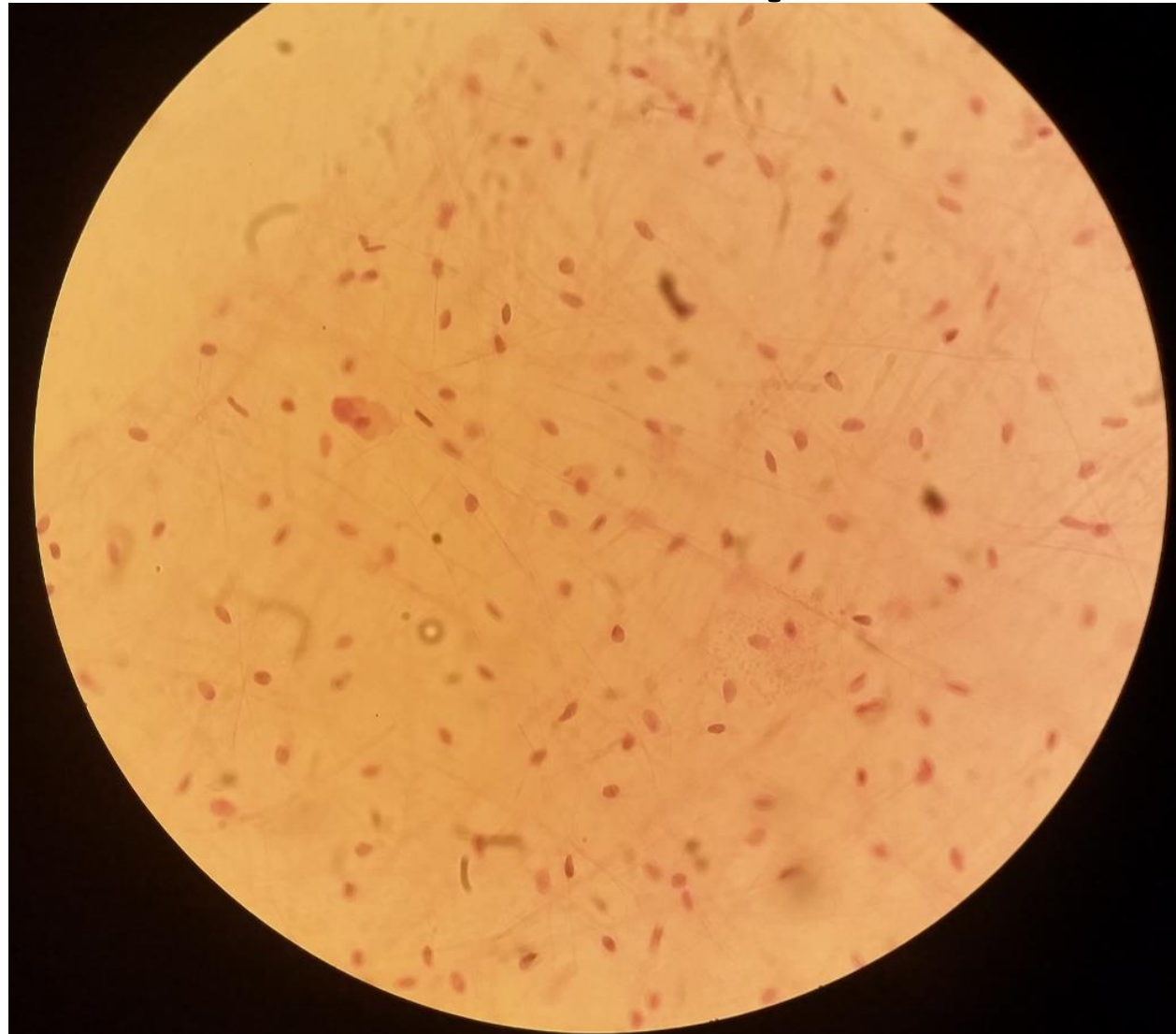
- LP



Loose (areolar) connective tissue

Slide H2.13 tissue spread

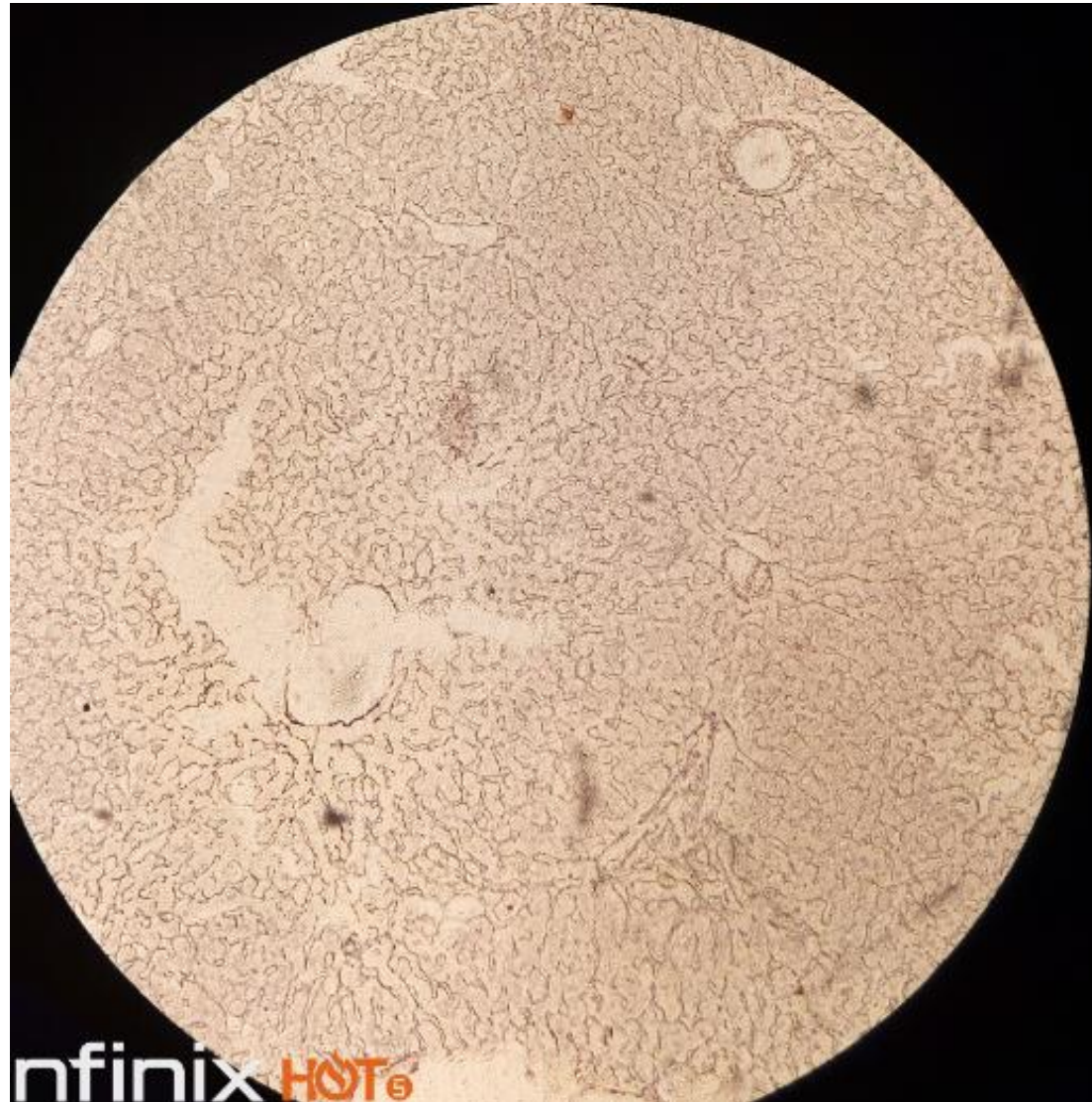
- HP



Reticular fibres

Slide 63 silver stain liver

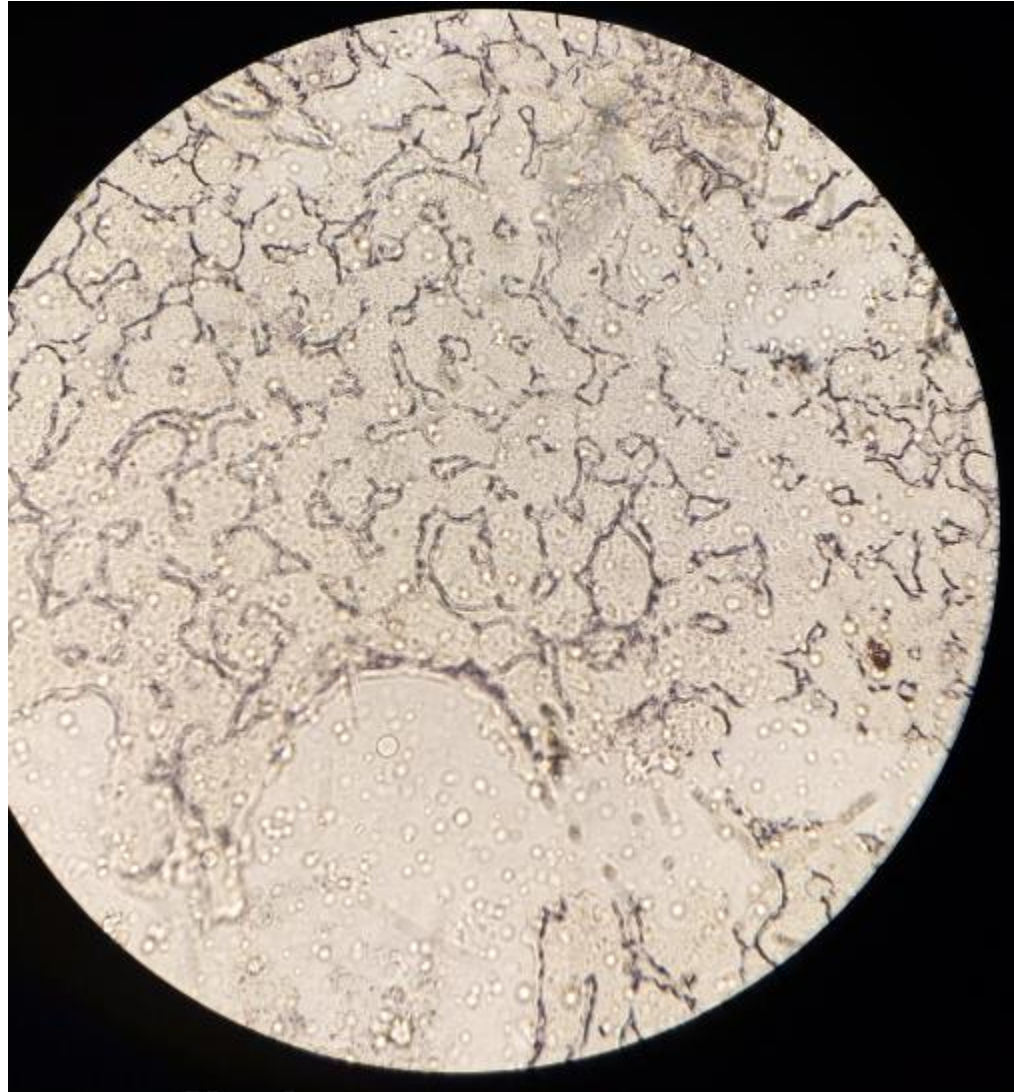
- Lp



Reticular fibres

Slide 63 silver stain liver

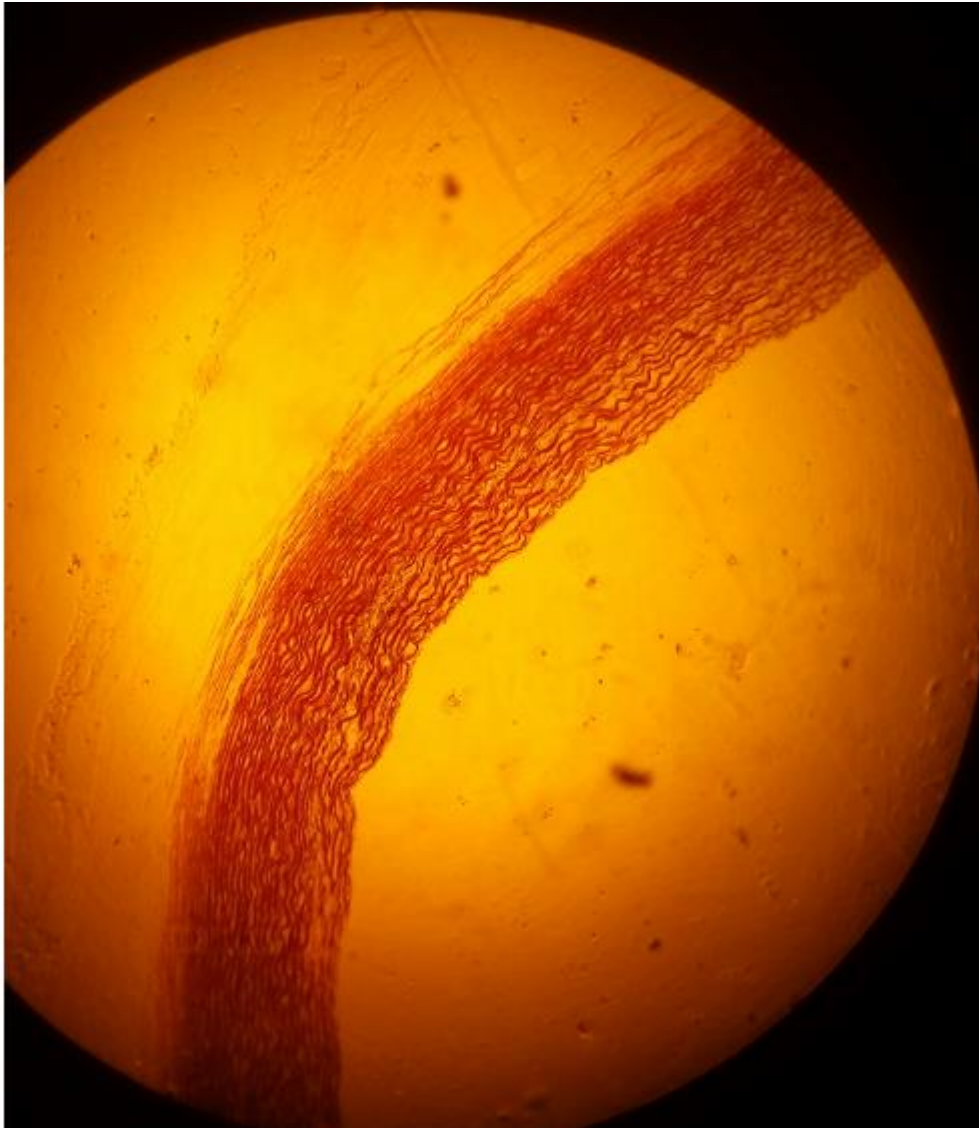
- Hp



Elastic tissue

Slide H2.63

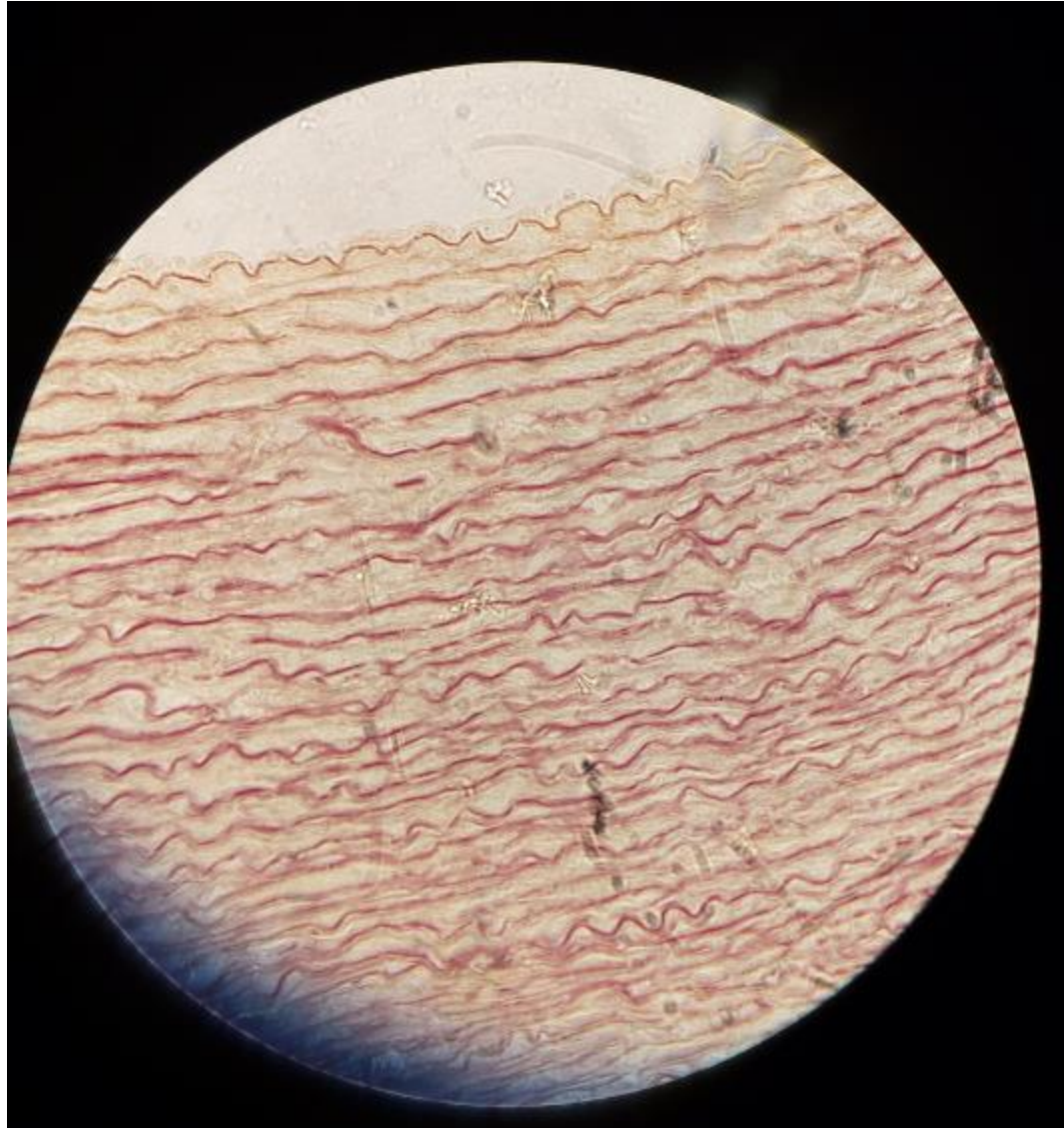
- LP



Elastic tissue

Slide H2.63

- Hp



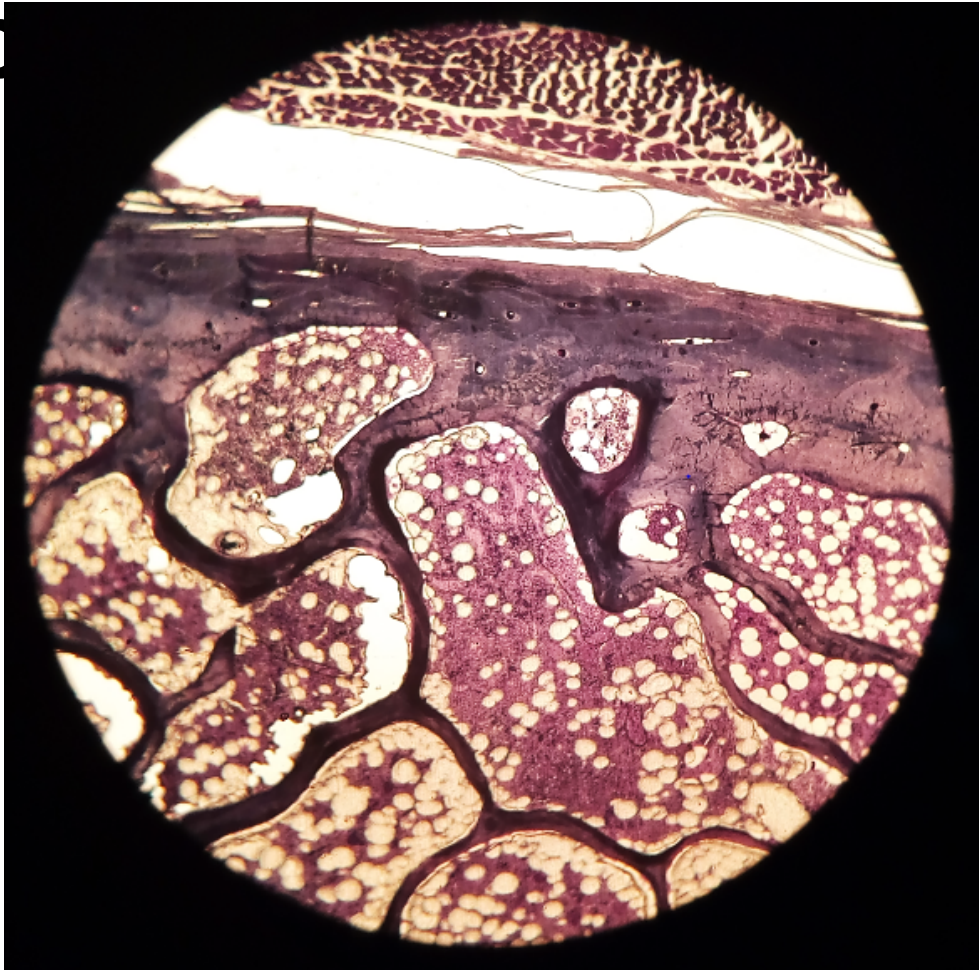
Practical 7: Bone & Ossification

Presenter: J.Z.Sichela

Compact and cancellous bone

slide 6: Rib Lp

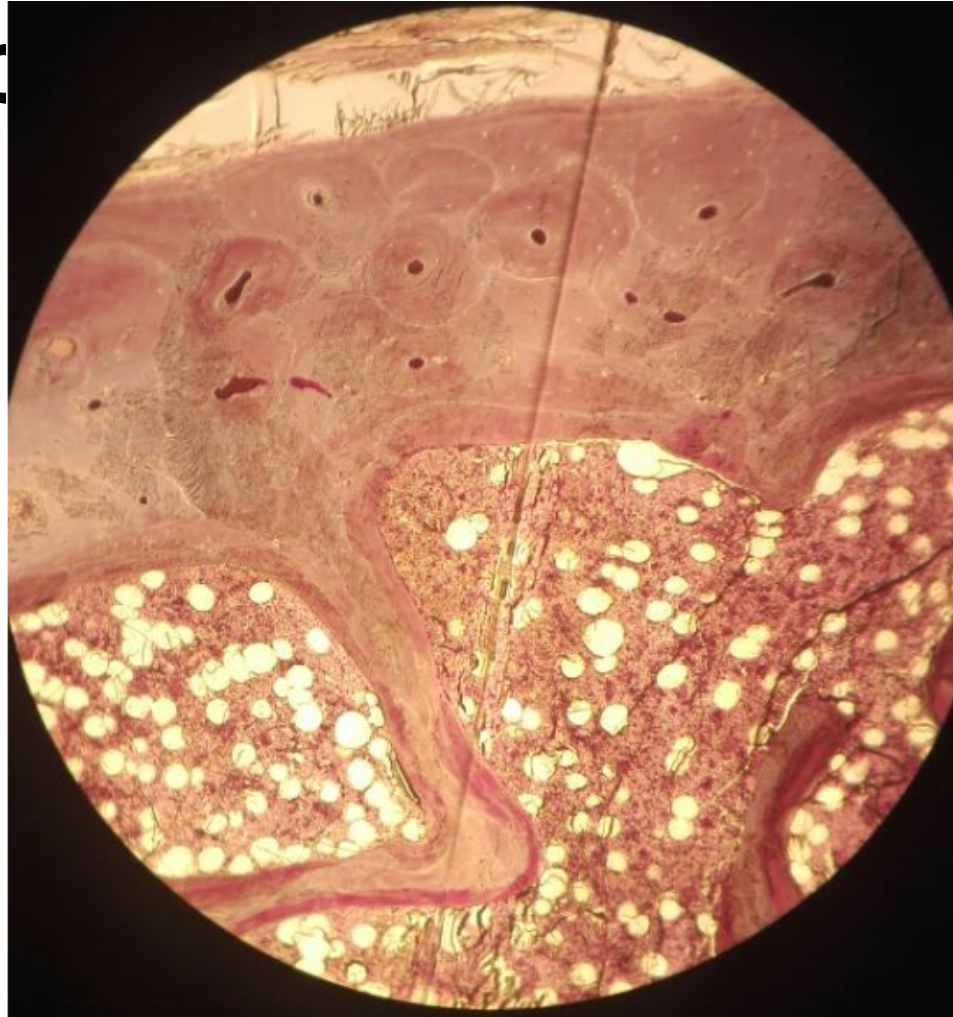Compact
bone



Compact and cancellous bone

slide 6: Rib Mp

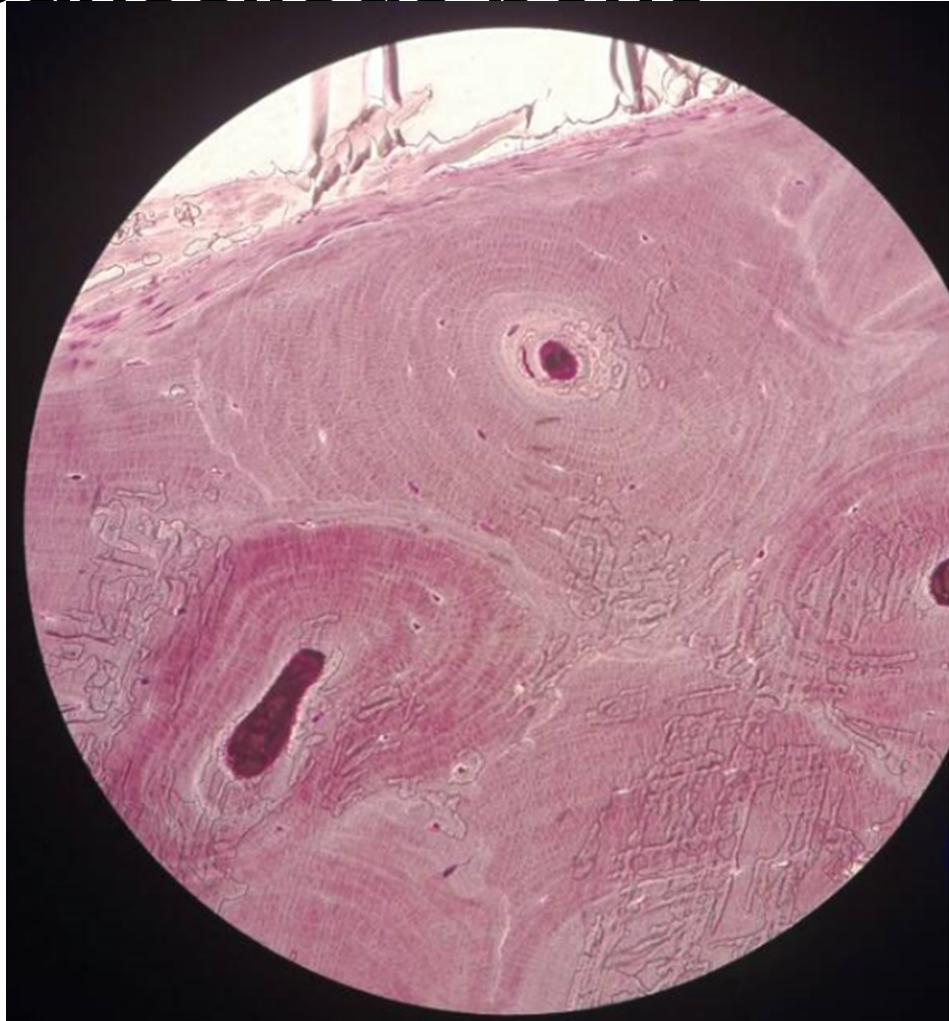Compact bone



Compact and cancellous bone

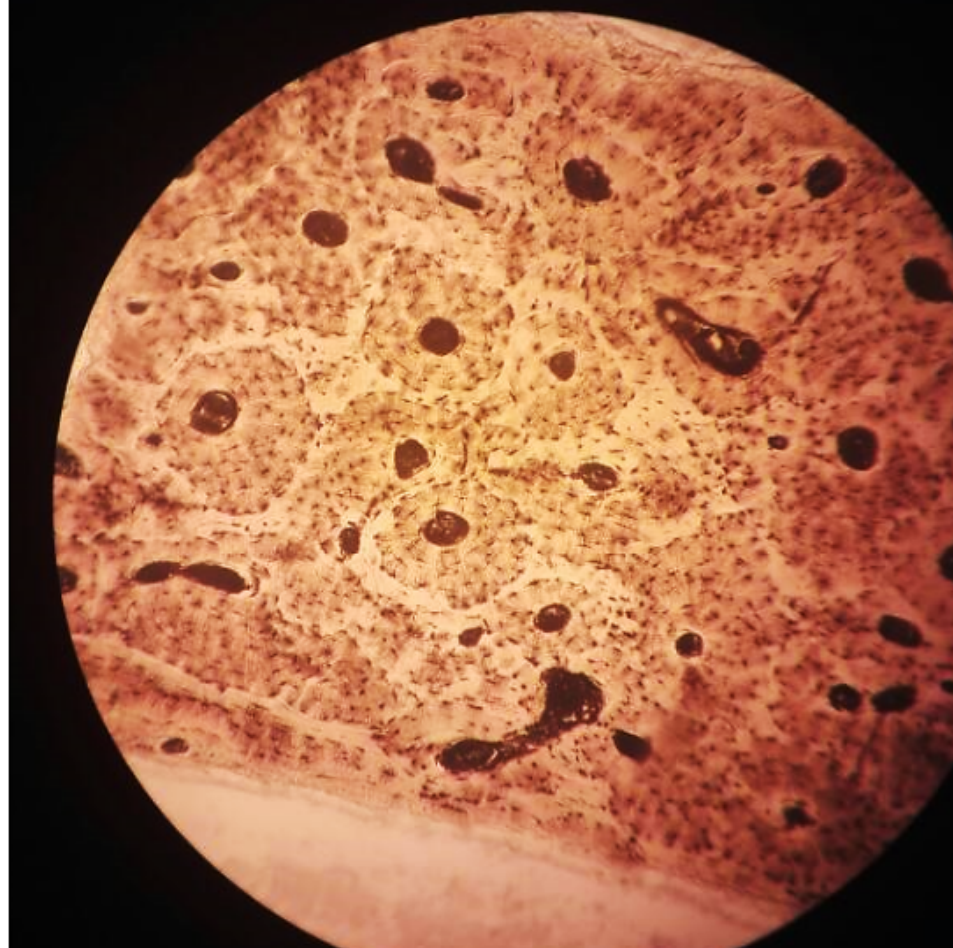
slide 6: Rib Hp

Compact
bone



Compact and cancellous bone slide H2.74: Lp


Ground Bone



Compact and cancellous bone

slide H2.74: H

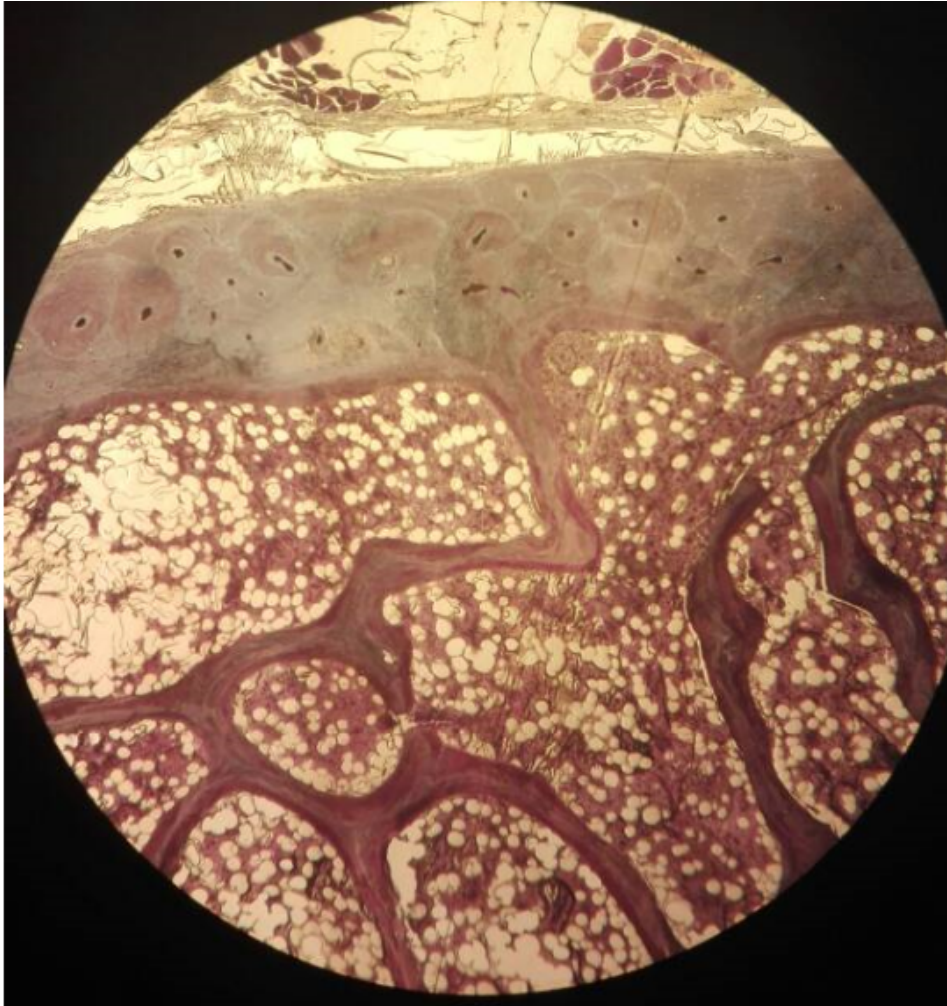
Ground Bone



Compact and cancellous bone

slide 6: Rib Lp

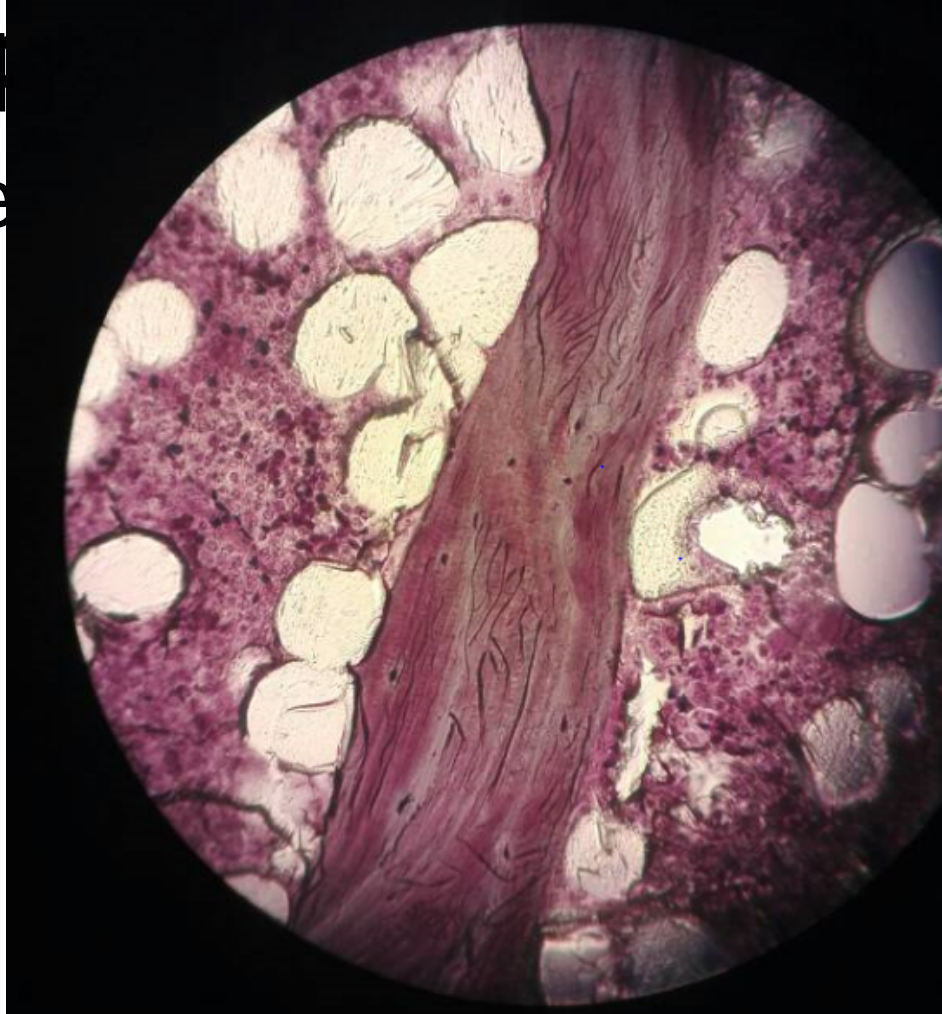
Cancellous bone



Compact and cancellous bone

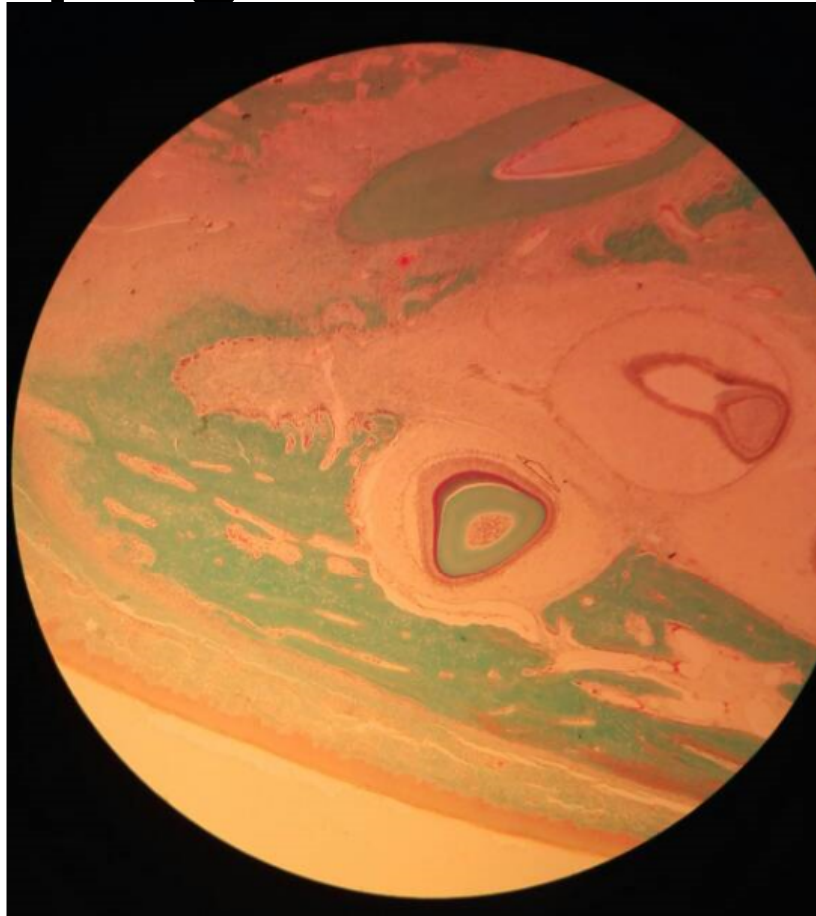
slide 6: Rib H&E

Cancellous bone



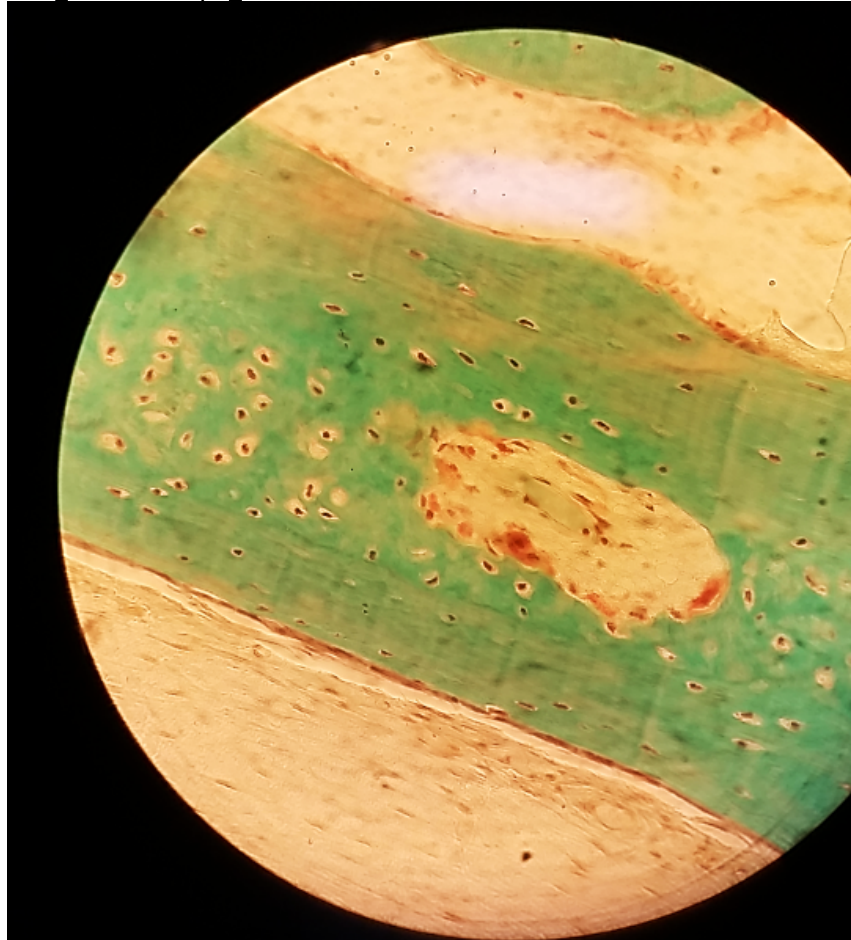
Intramembranous calcification slide 50: Developing Tooth

Lp

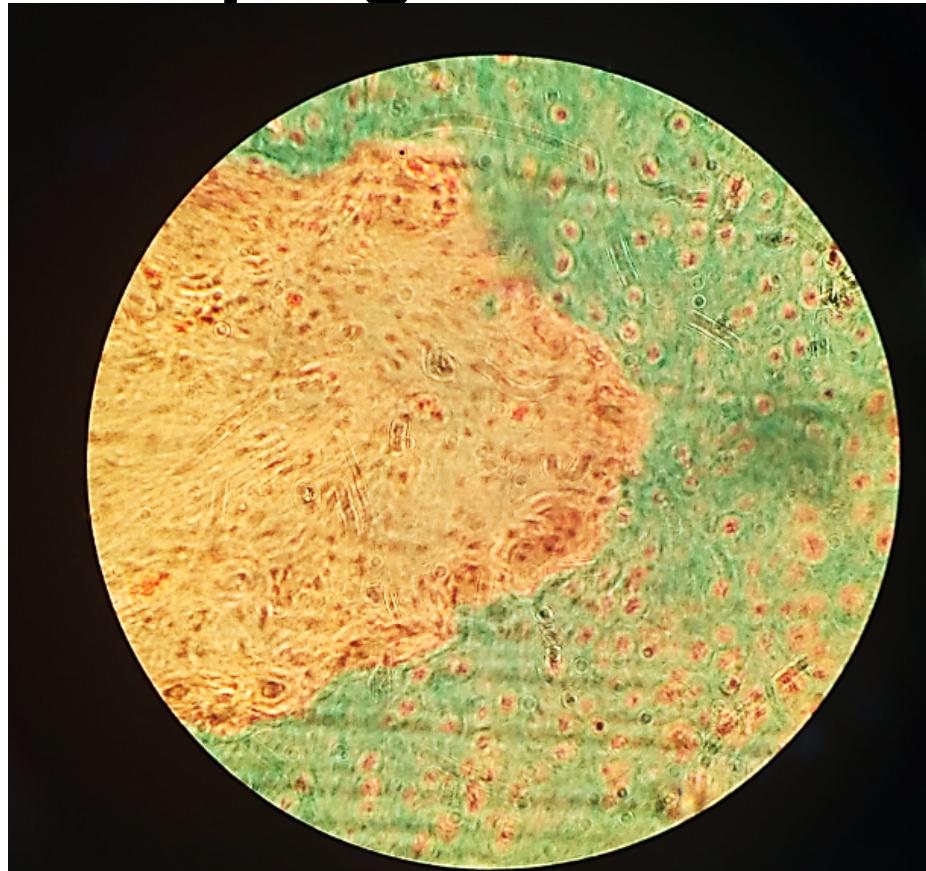


Intramembranous calcification slide 50: Developing Tooth

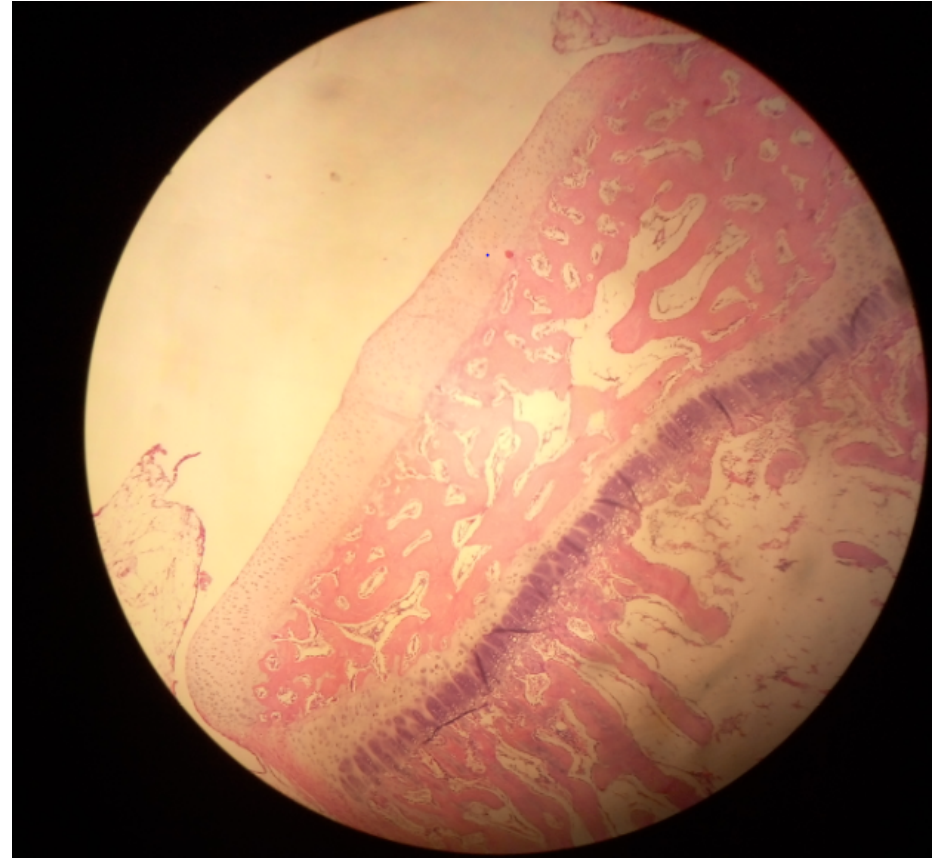
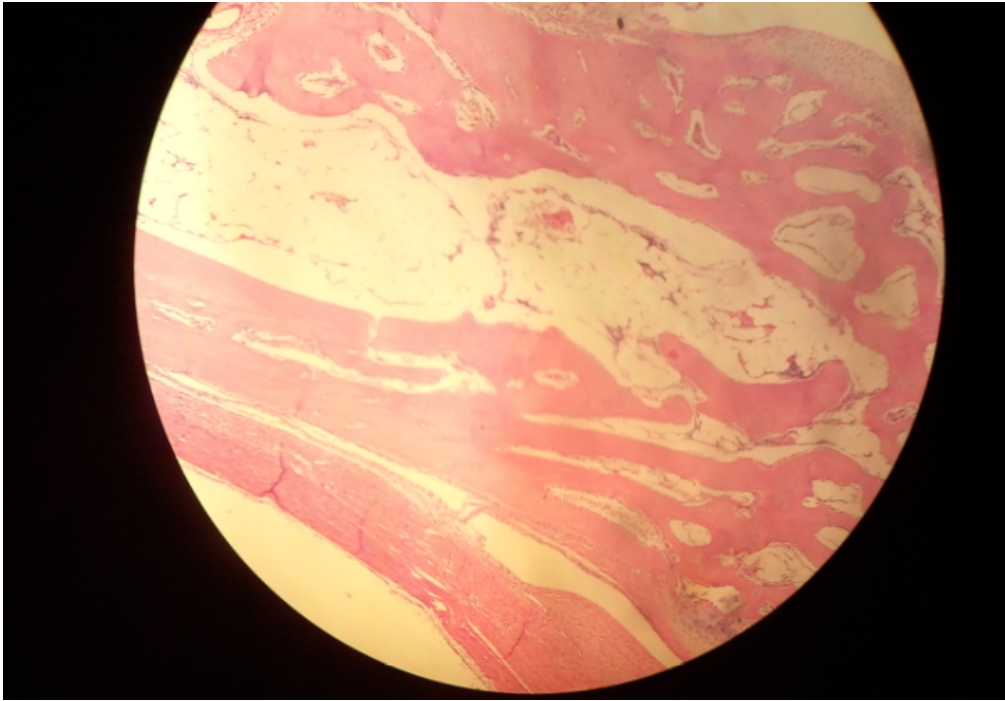
Hp



Intramembranous calcification slide 50: Developing Tooth

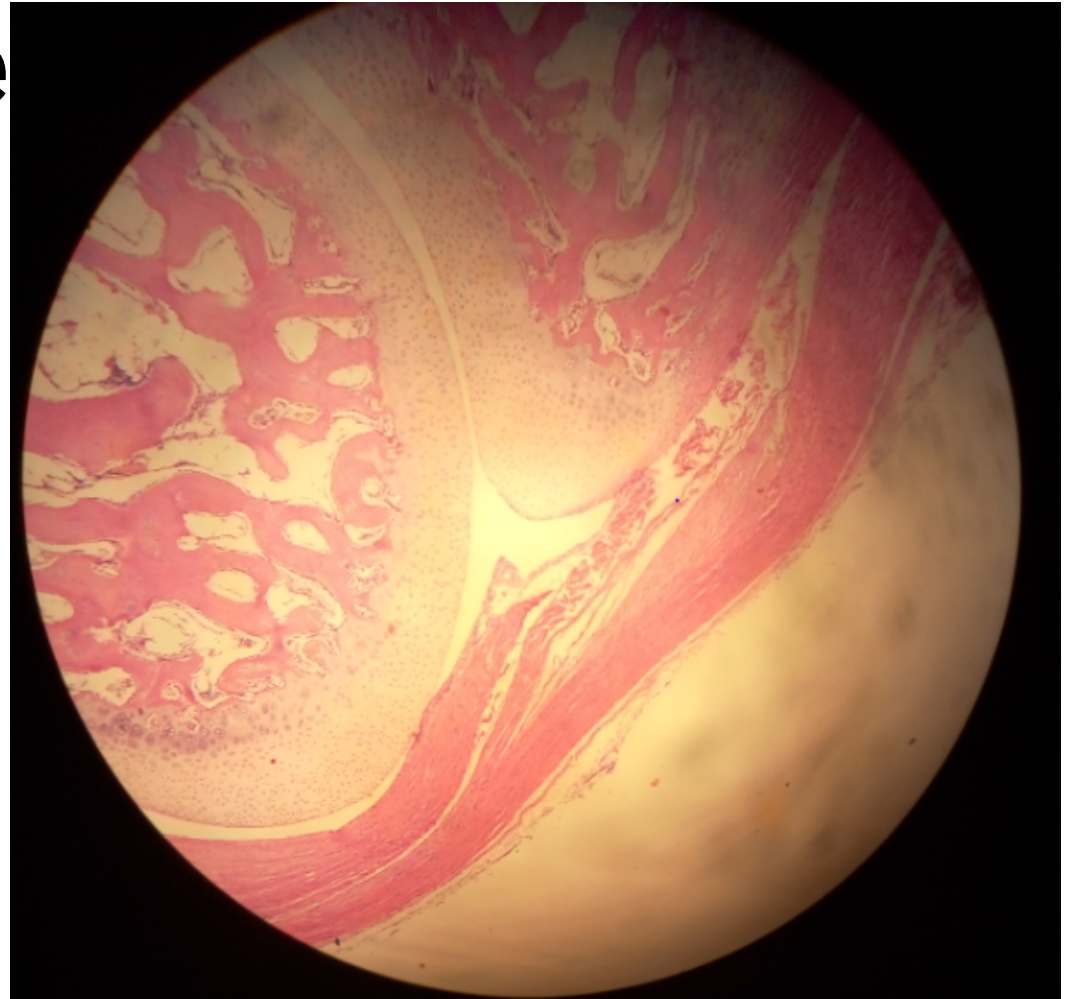
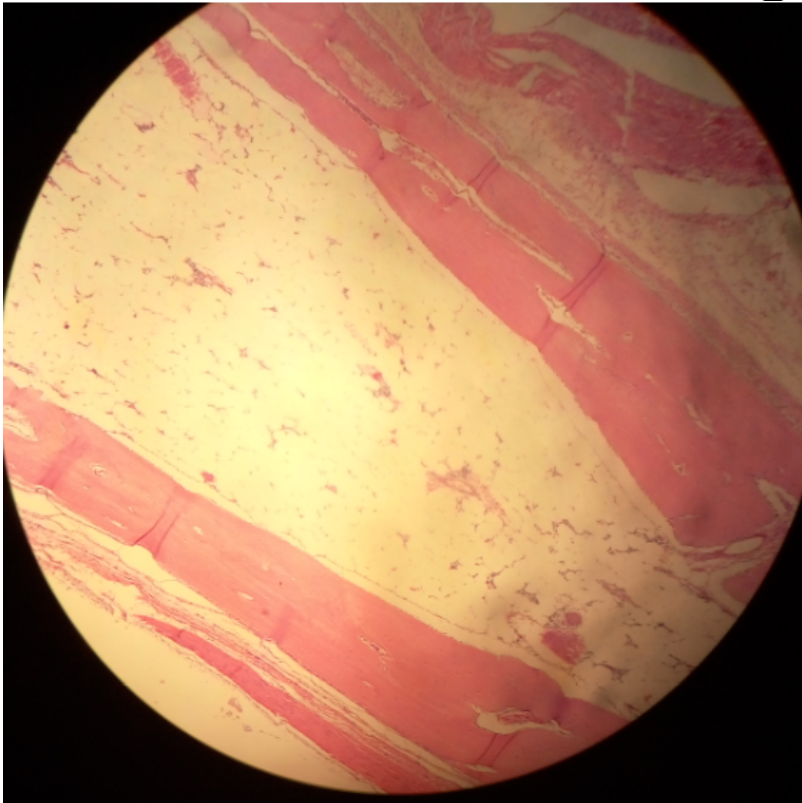


Endochondral ossification slide 7: Fetal Finger



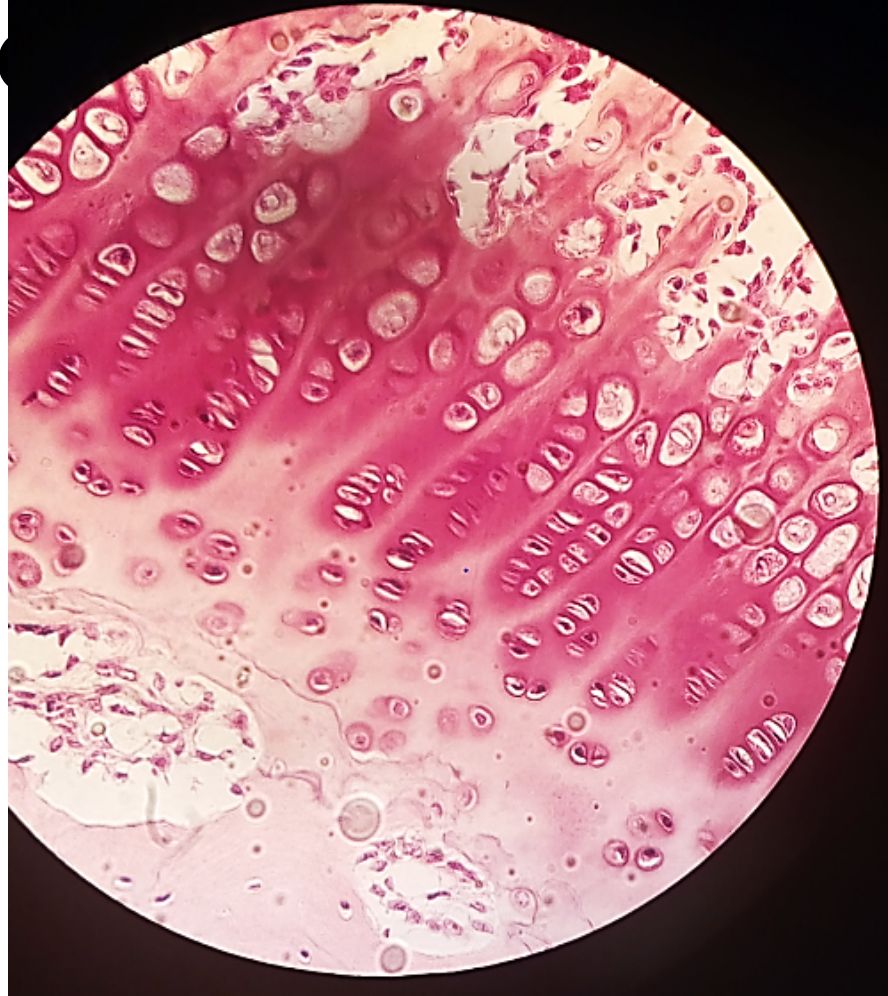
Endochondral ossification

slide 7: Fetal Finge



Endochondral ossification

slide 7: Fetal Finger



Epiphyseal plate

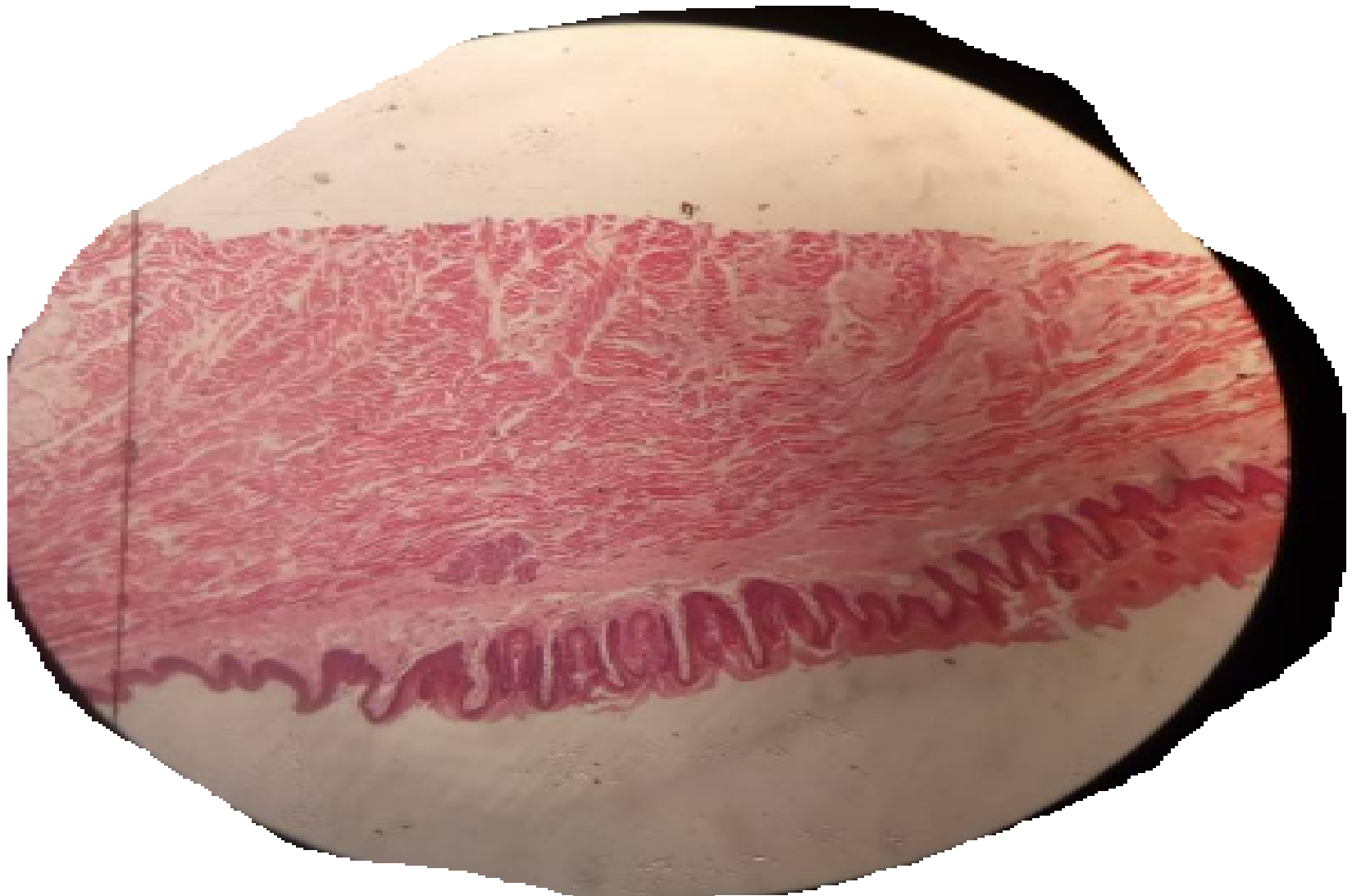slide 8: Femur, Epiphyseal Disc

LAB 9

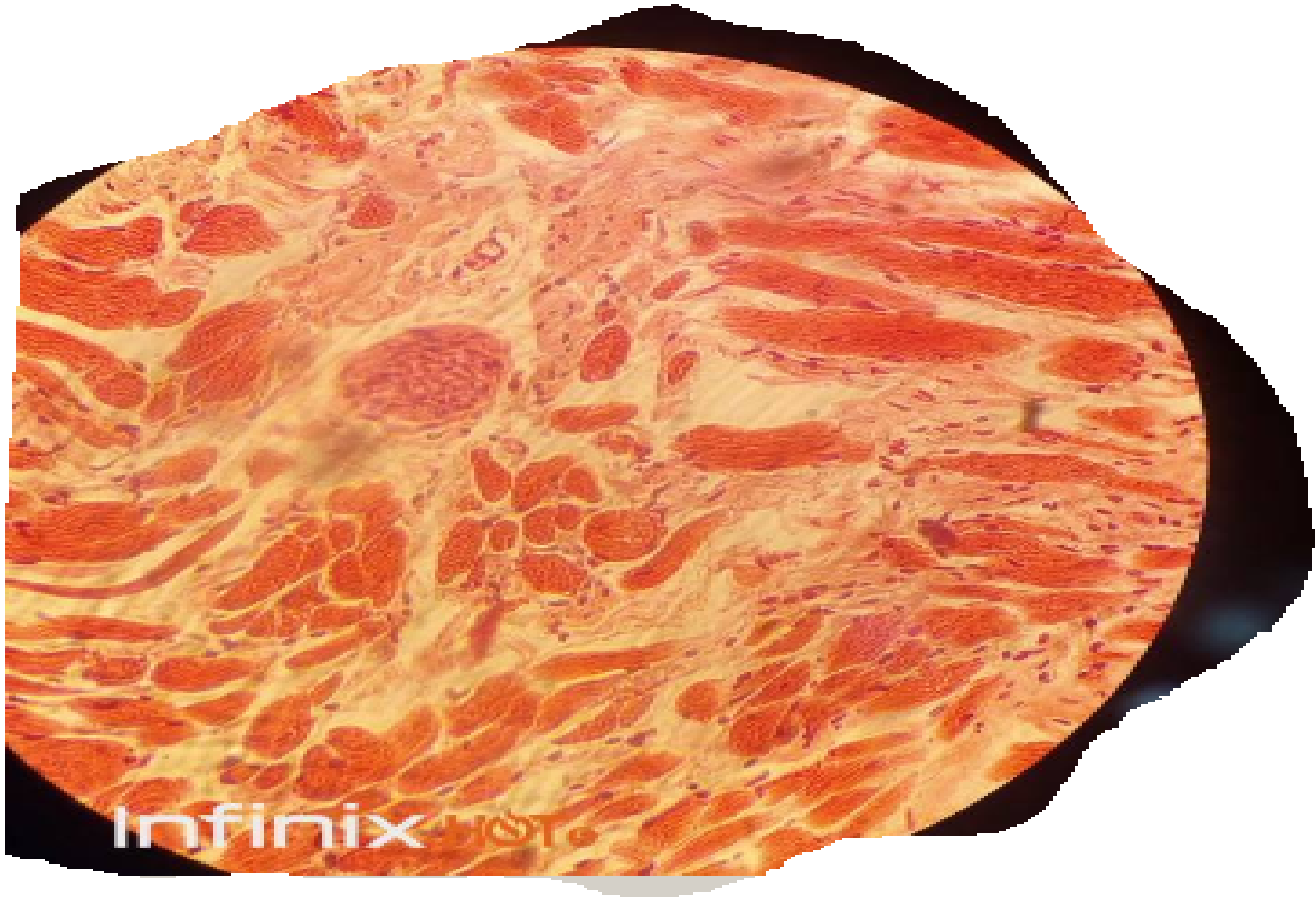MUSCLE TISSUE

1. STRIATED SKELETAL MUSCLE

- SLIDE 43 ROOT OF THE TONGUE/LP



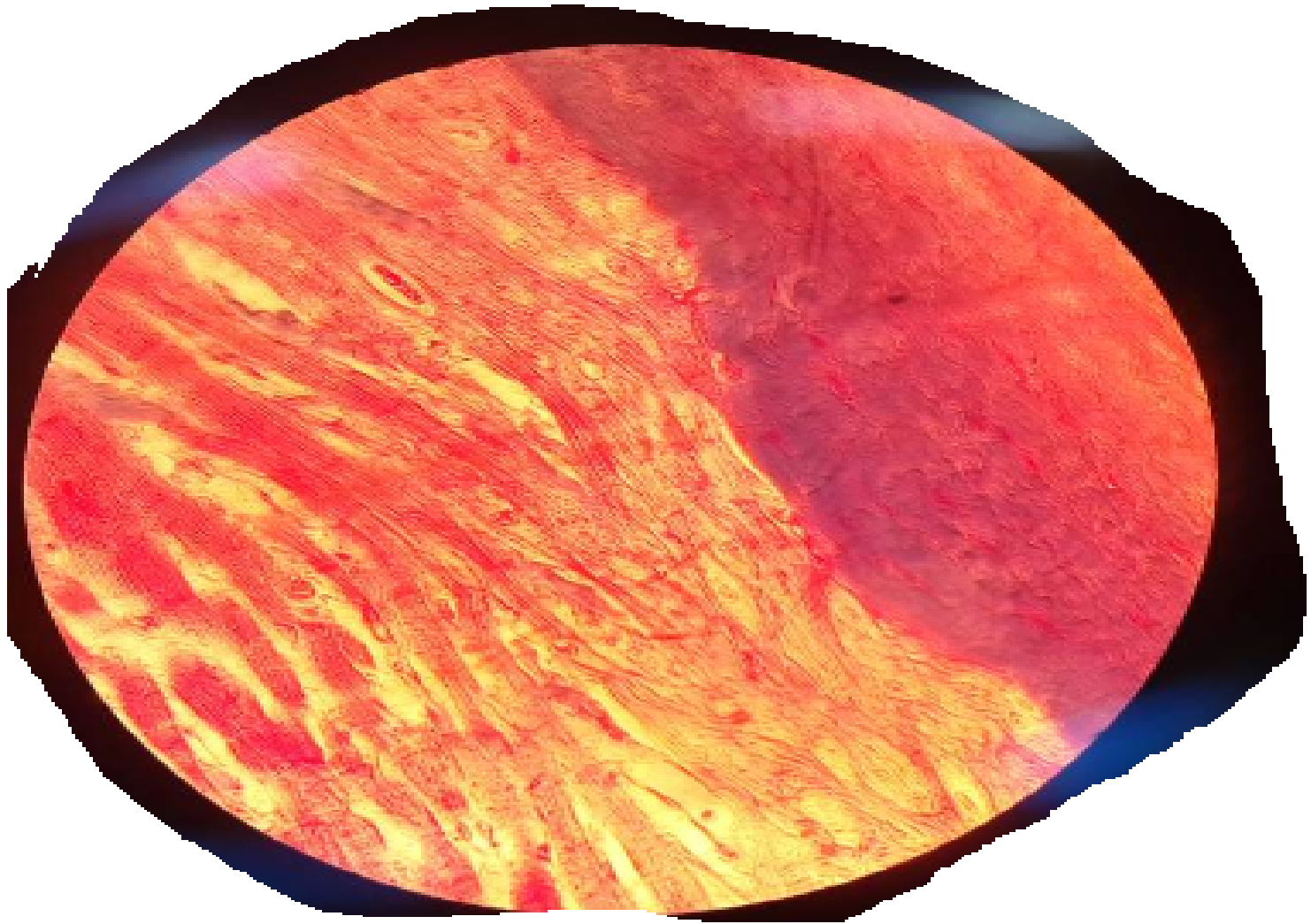
ROOT OF THE TONGUE/HP



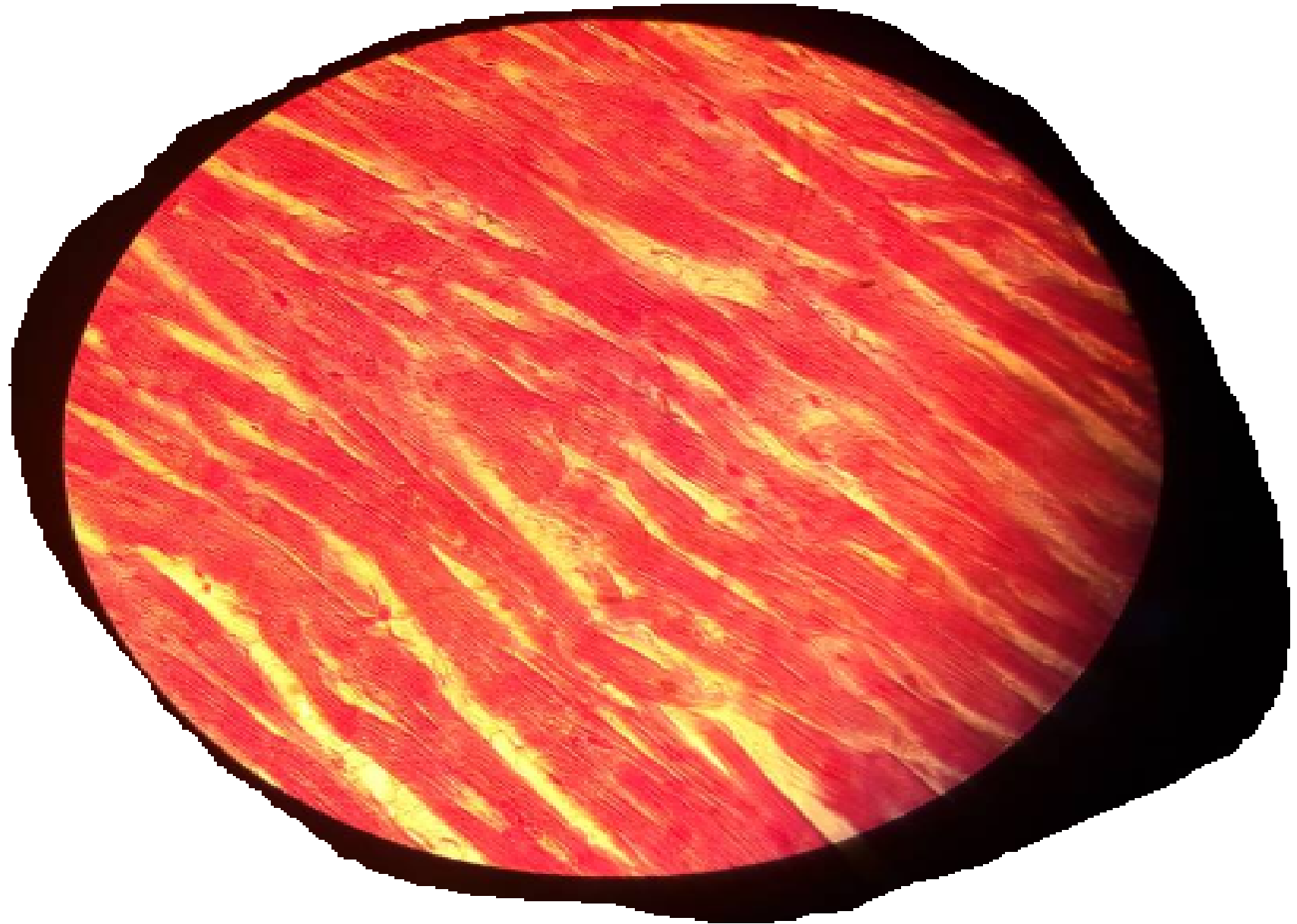
Infinix HISTO

2. CARDIAC MUSCLE

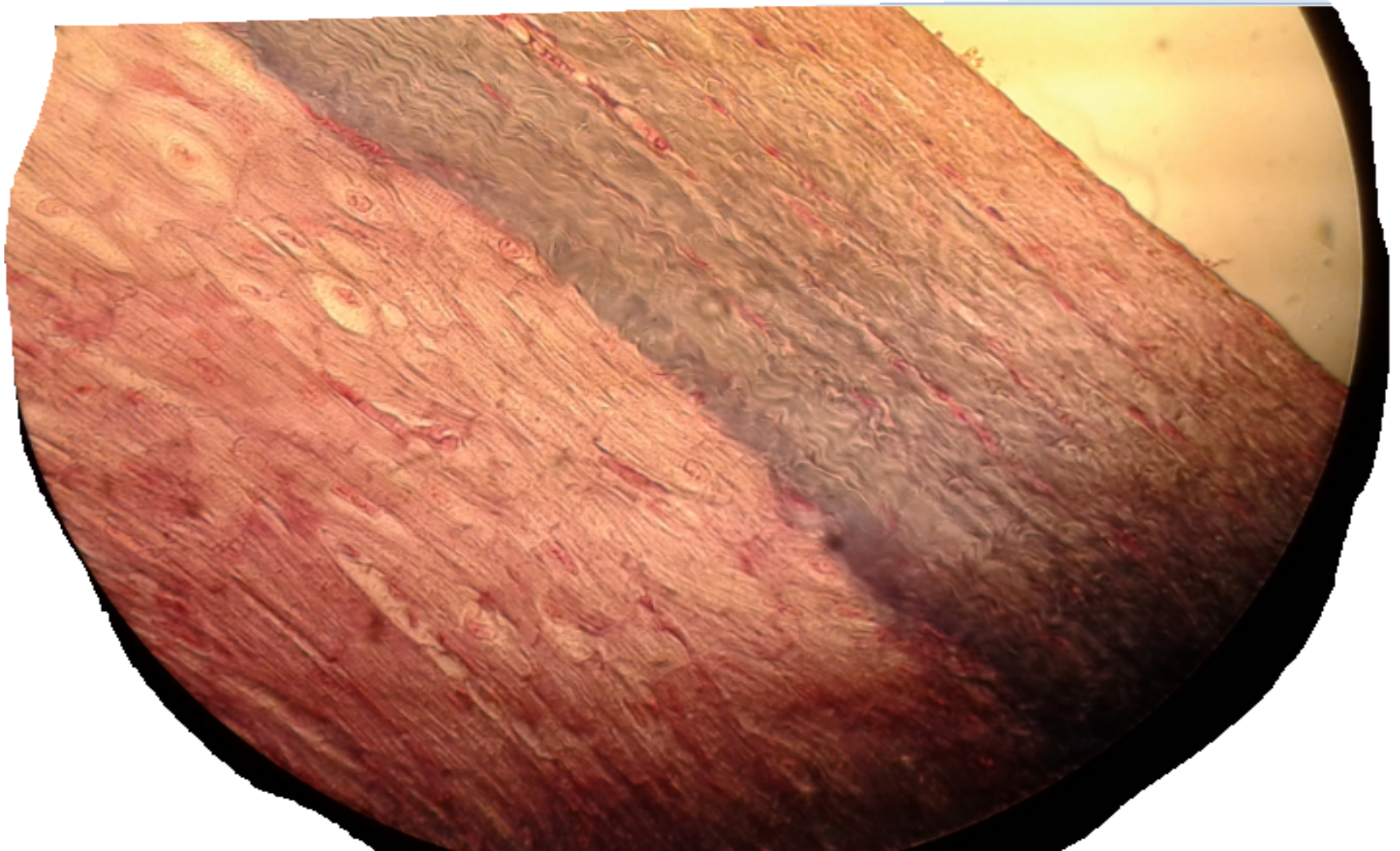- SLIDE 25 HEART(MALLORY)/LP



SLIDE 25 HEART(MALLORY)/LH

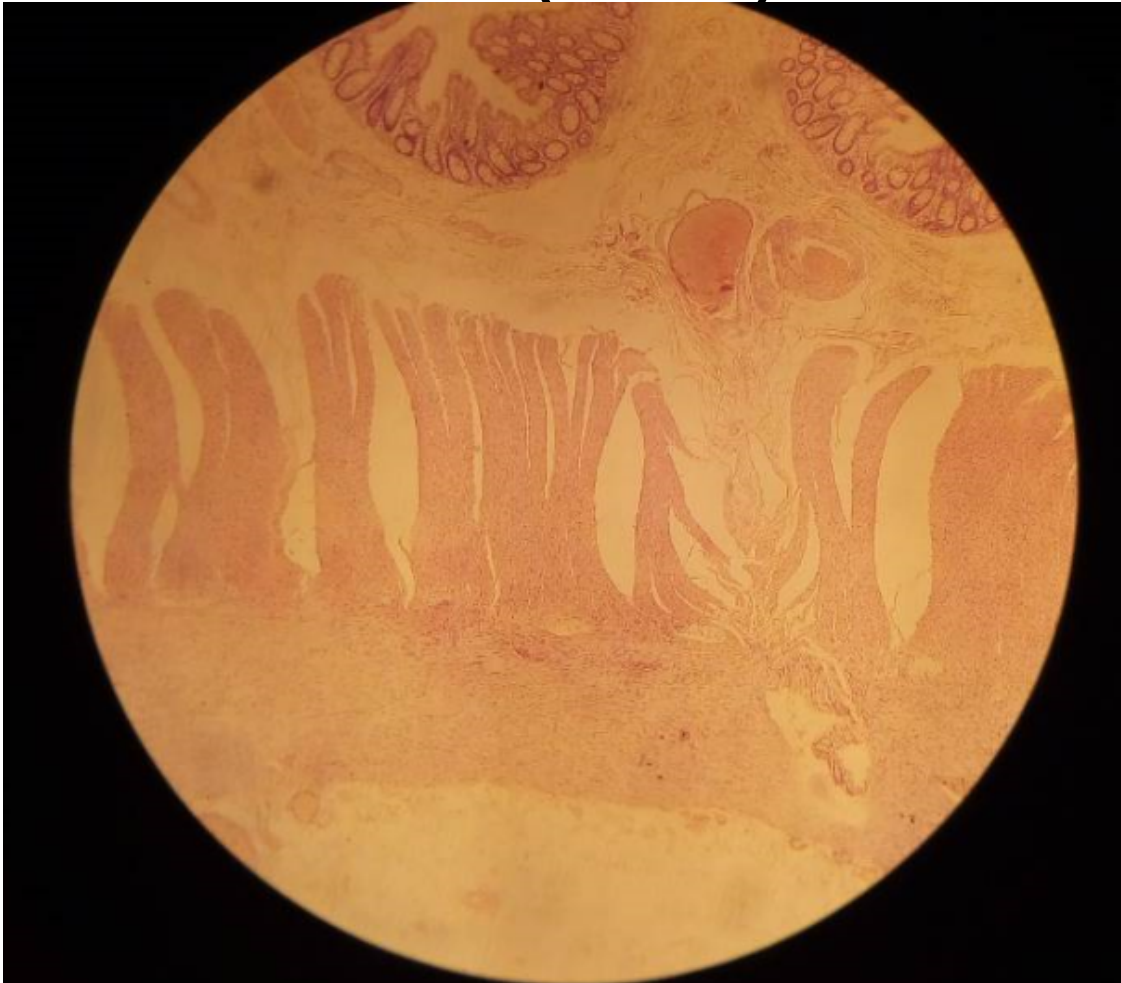


3. PURKINJE FIBRES /HP

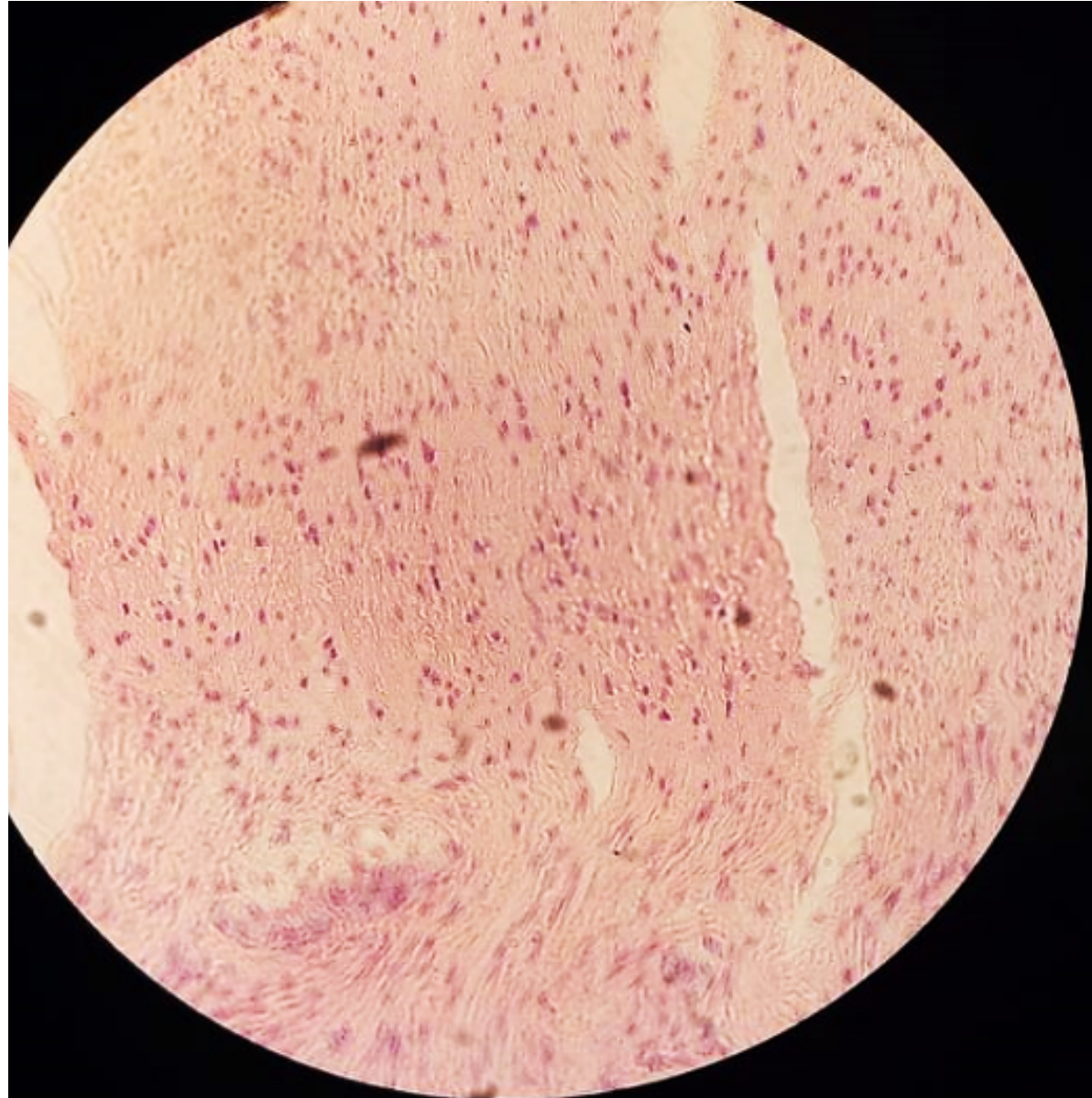


4. SMOOTH MUSCLE


- SLIDE 53 COLON(HAB)



COLON HP

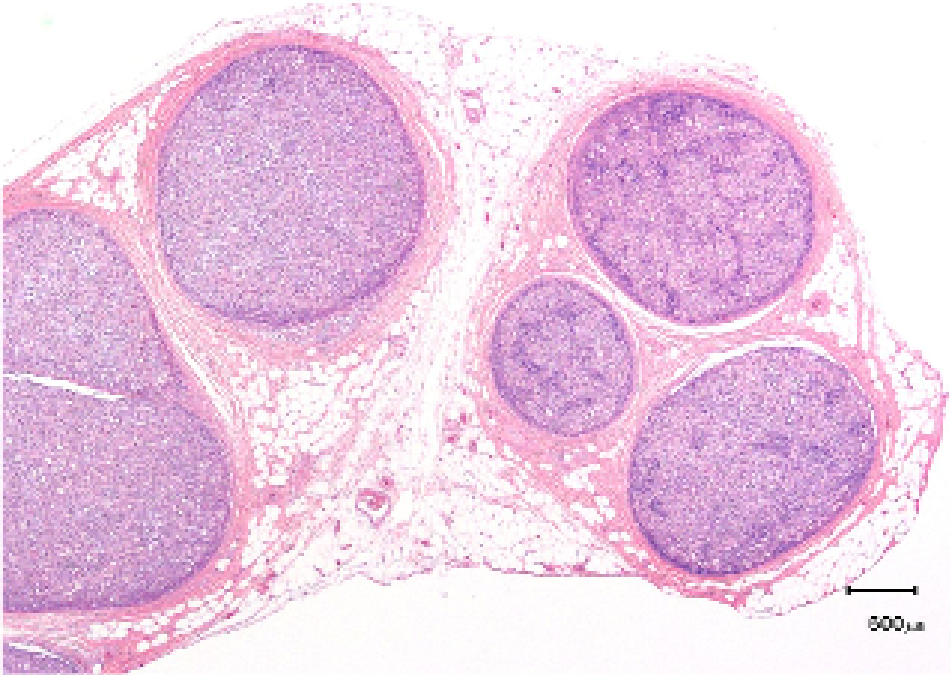


SLIDE H3.21 TEASED SMOOTH
MUSCLE

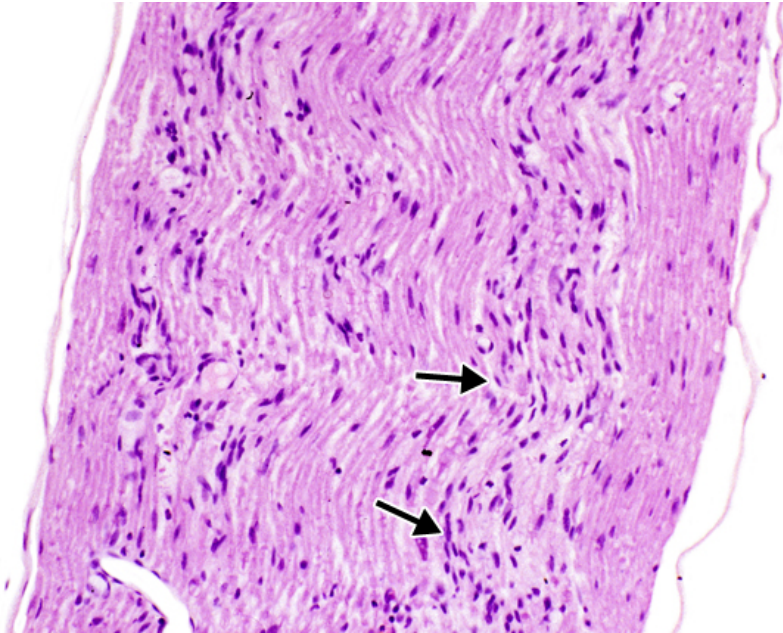


PRACTICAL 10: NERVE TISSUE

Slide 13 TS & LS Sciatic Nerve (H&E) LP



8



Slide 13 TS & LS Sciatic Nerve (H&E) HP

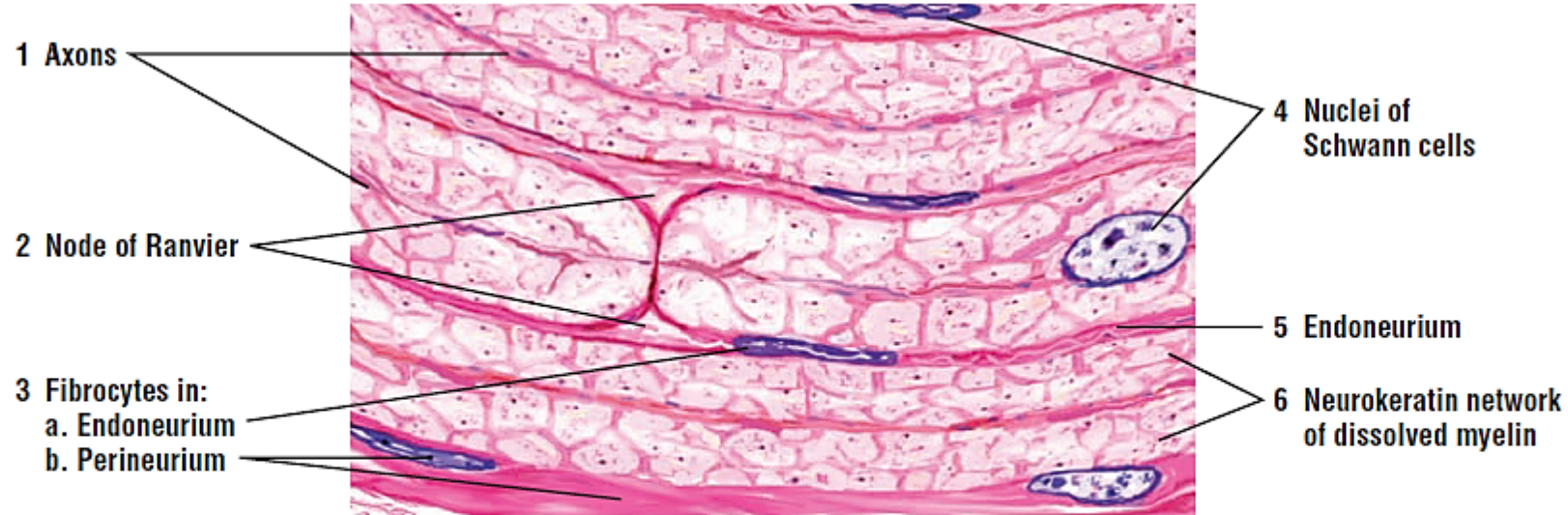


FIGURE 7.18 ■ Sciatic nerve (longitudinal section). Stain: hematoxylin and eosin. High magnification (oil immersion).

Slide 13 TS & LS Sciatic Nerve (H&E) HP

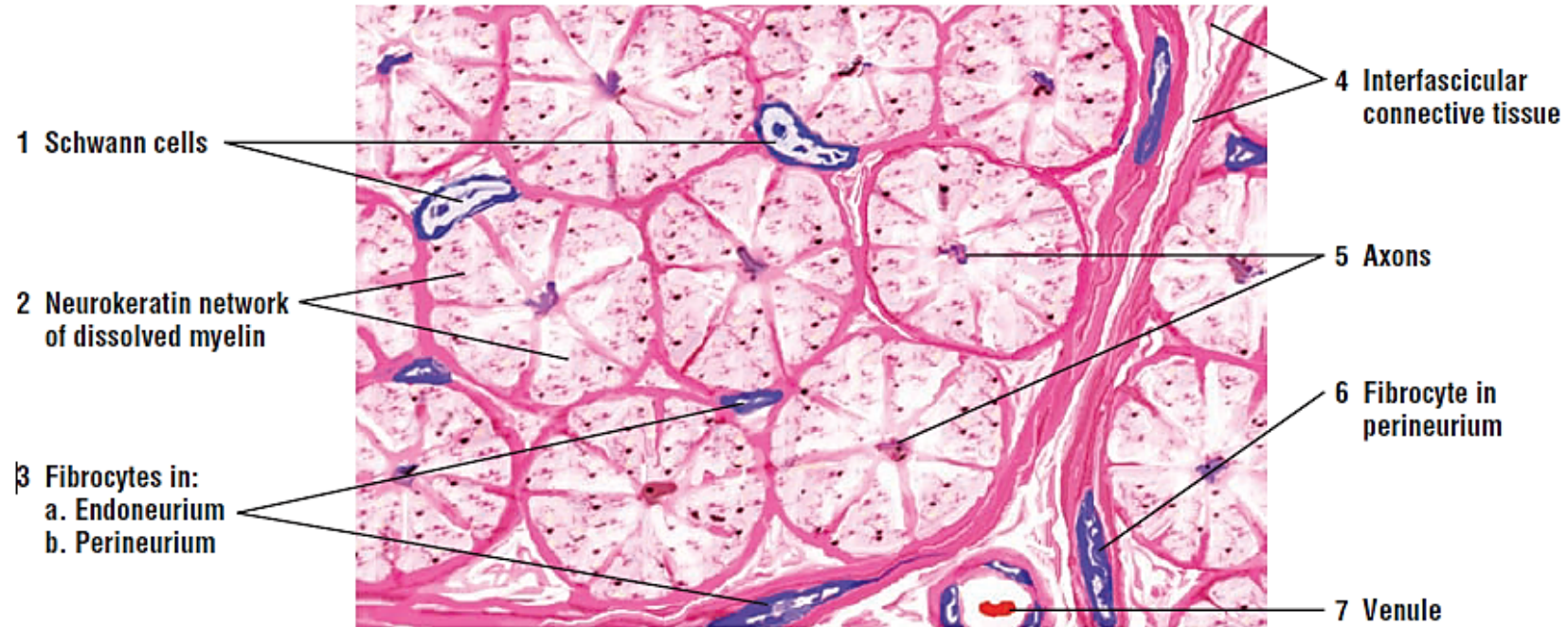
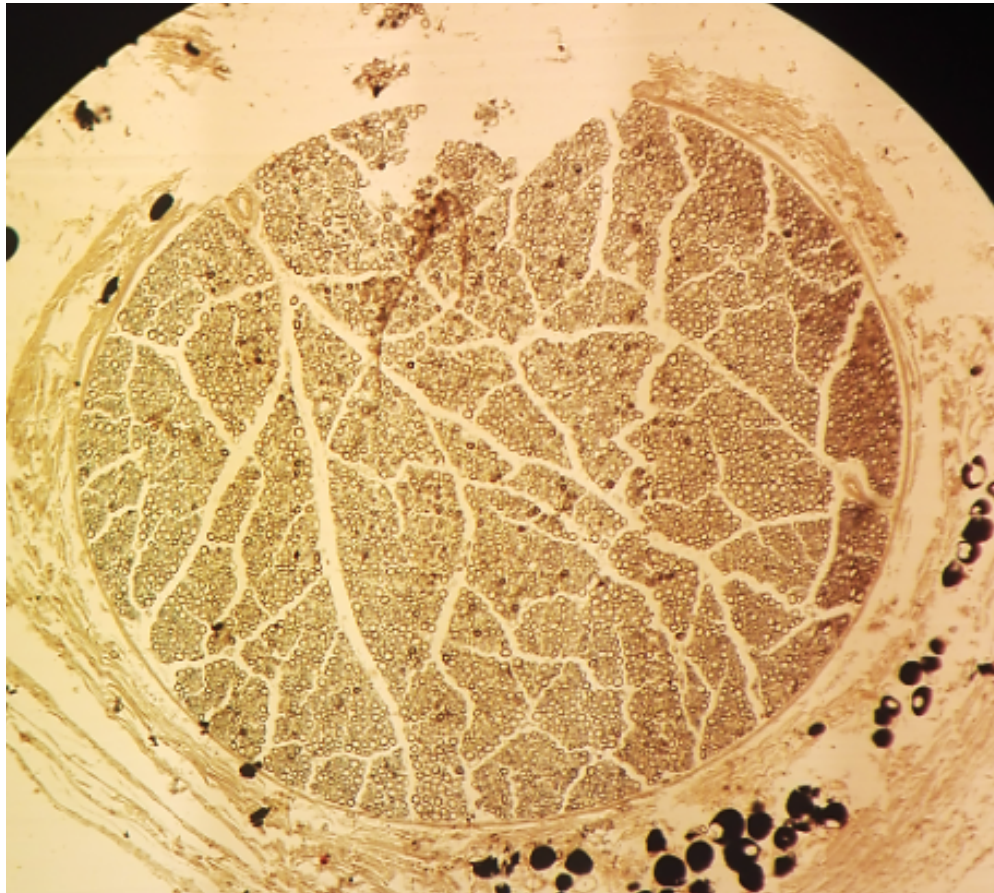
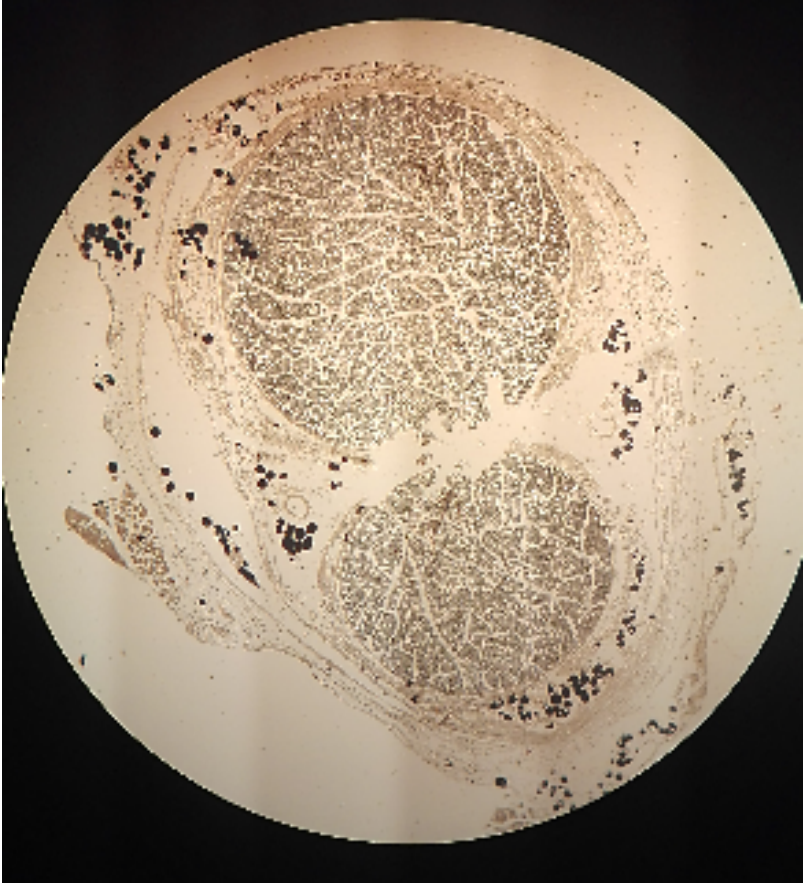
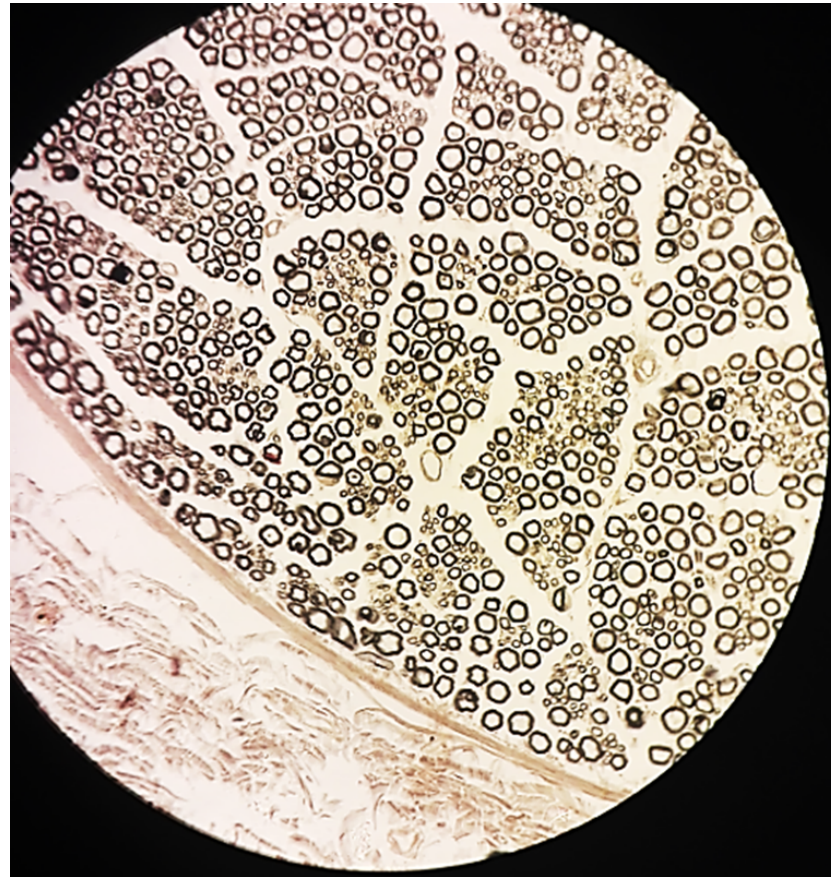


FIGURE 7.19 ■ Sciatic nerve (transverse section). Stain: hematoxylin and eosin. High magnification (oil immersion).

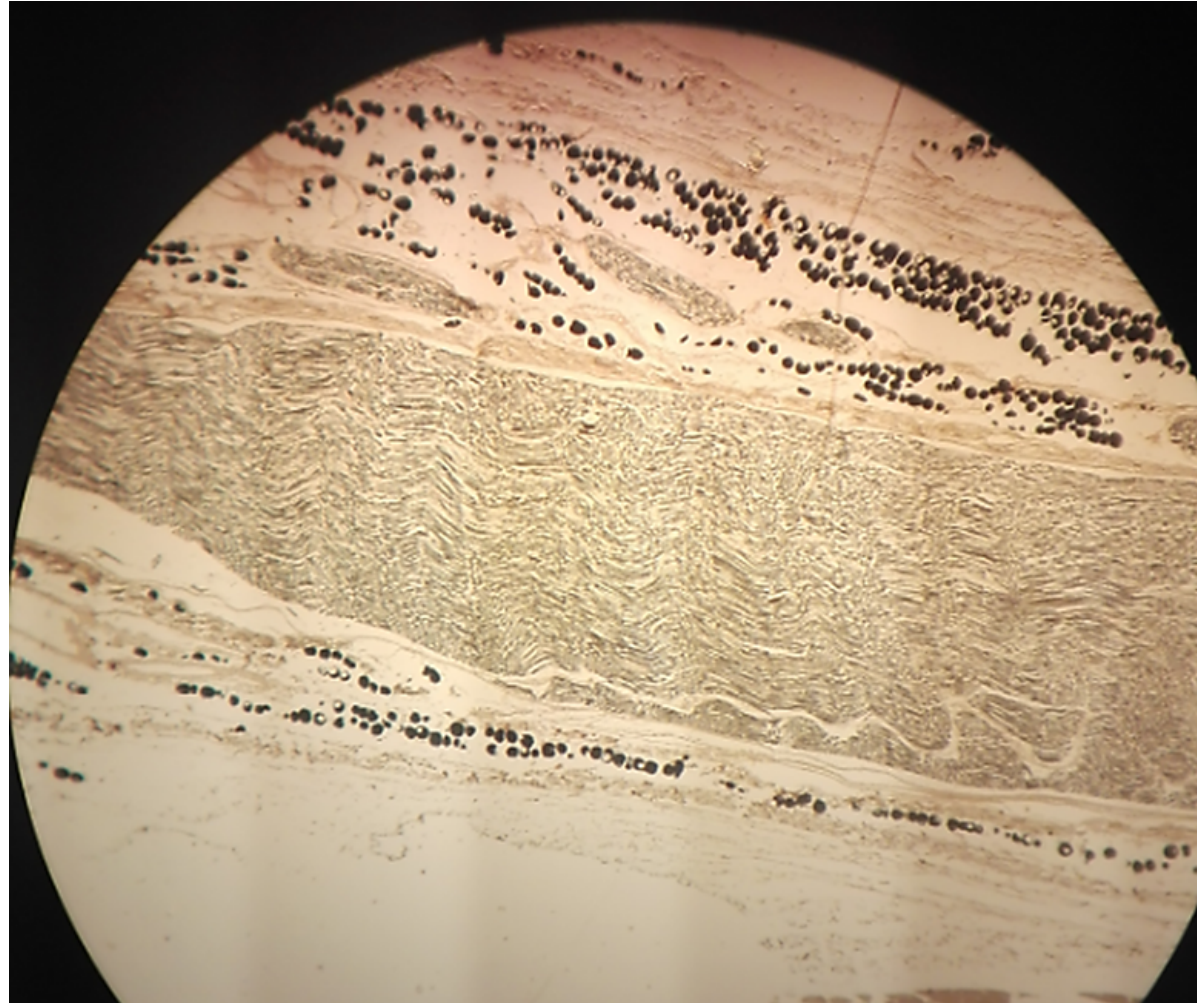
Slide 14: TS & LS Sciatic Nerve LP (TS)



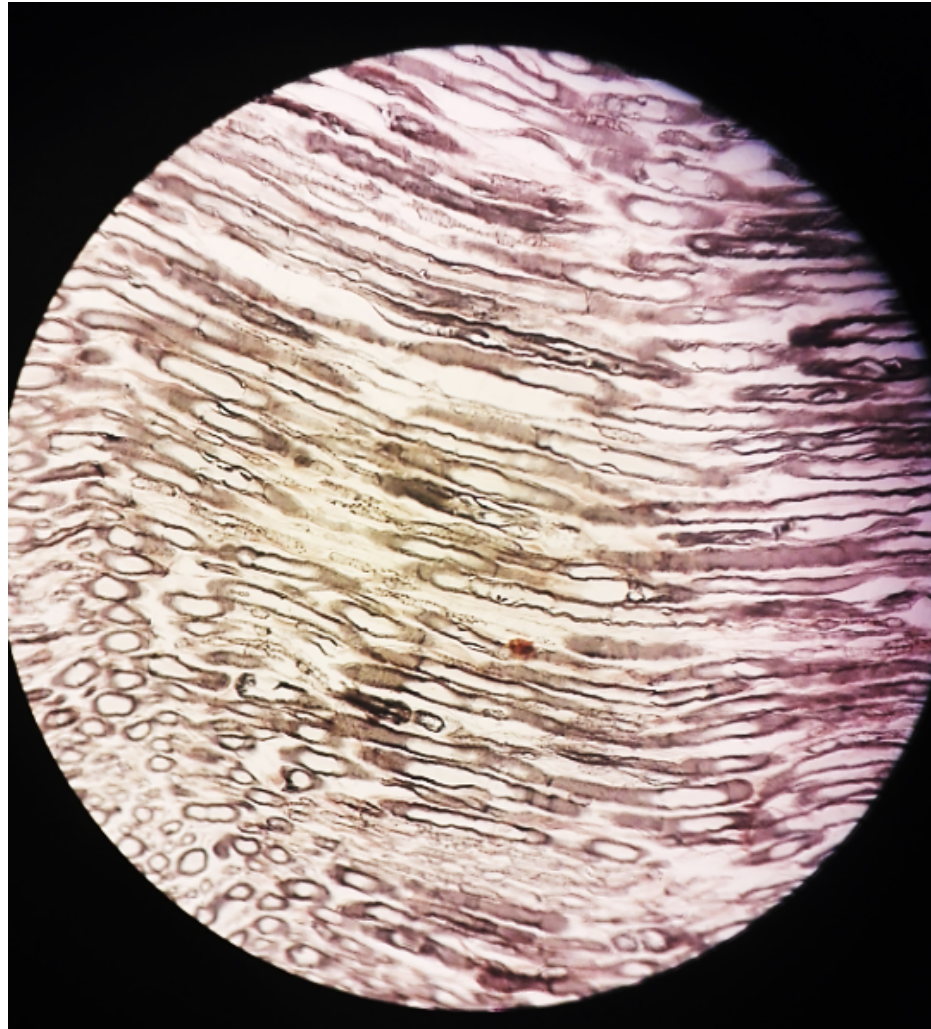
Slide 14: TS & LS Sciatic Nerve LP (TS)



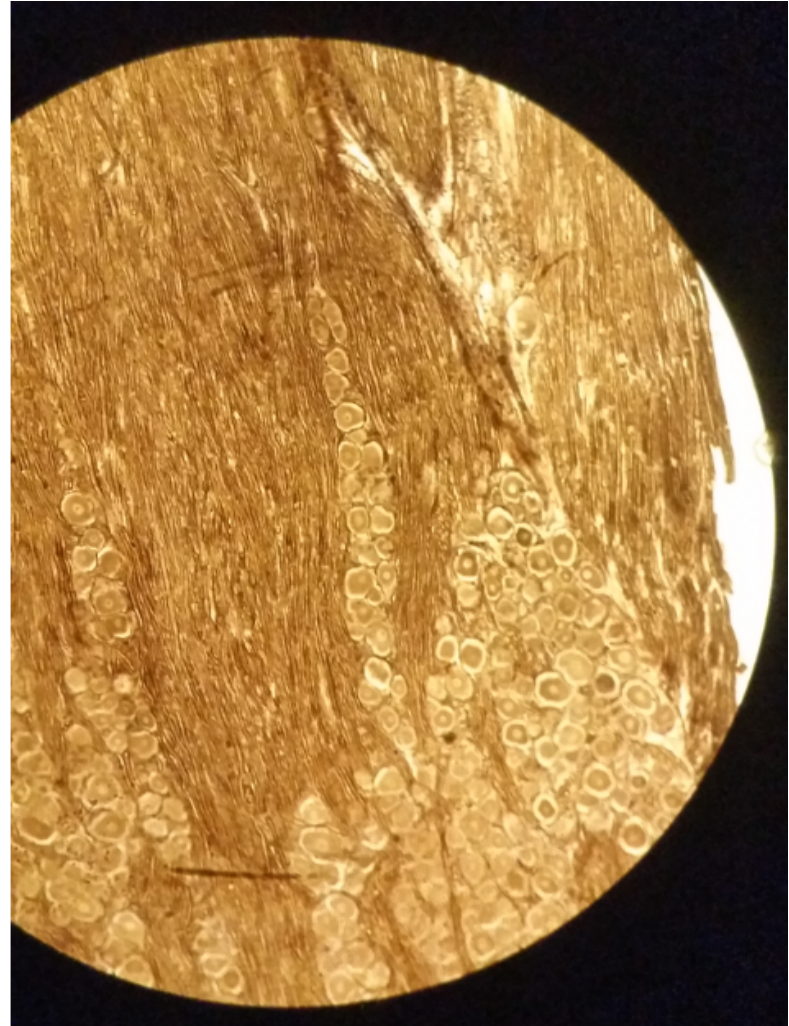
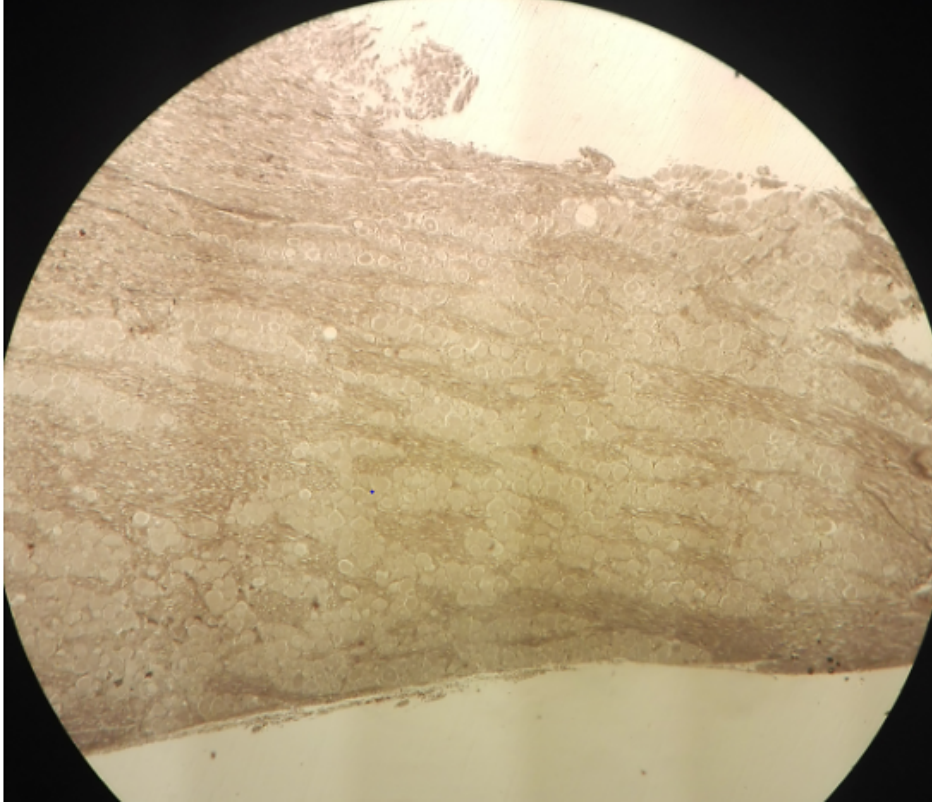
Slide 14: TS & LS Sciatic Nerve LP (LS)



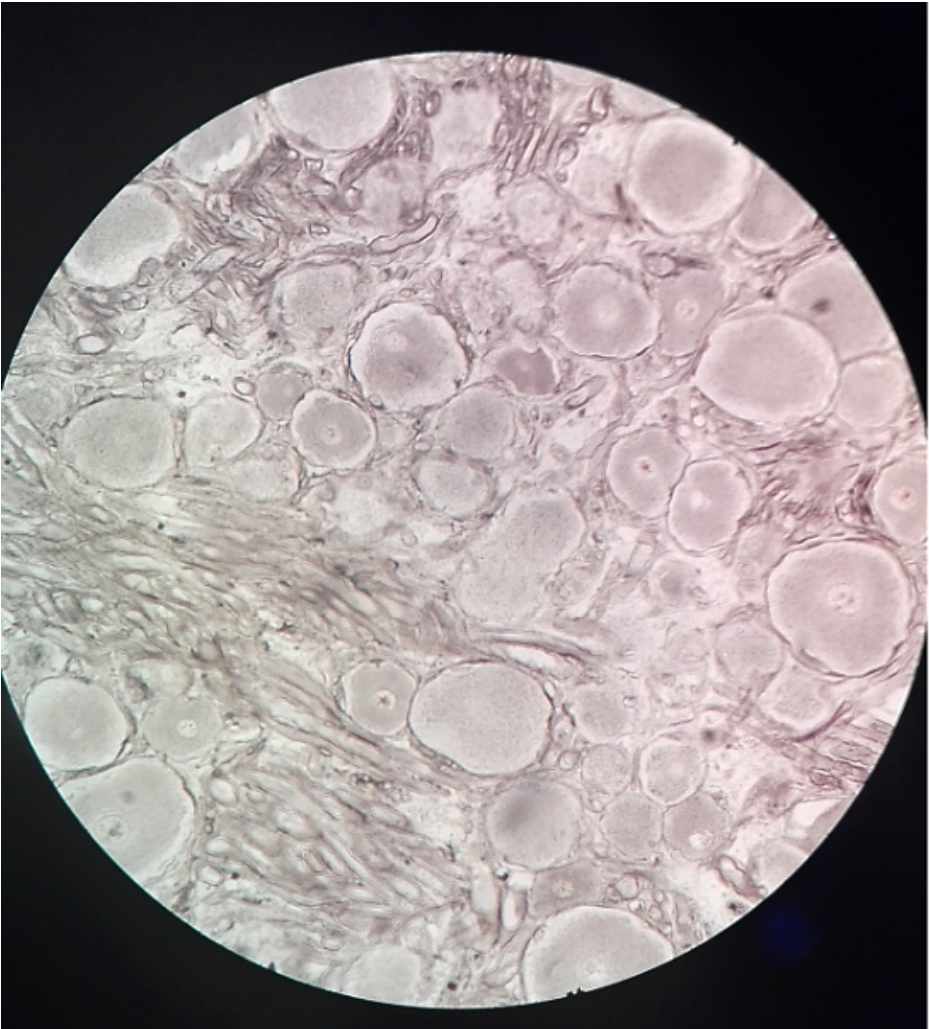
Slide 14: TS & LS Sciatic Nerve HP (LS)



Sensory ganglion: Slide 15 Trigeminal Ganglion LP & MP


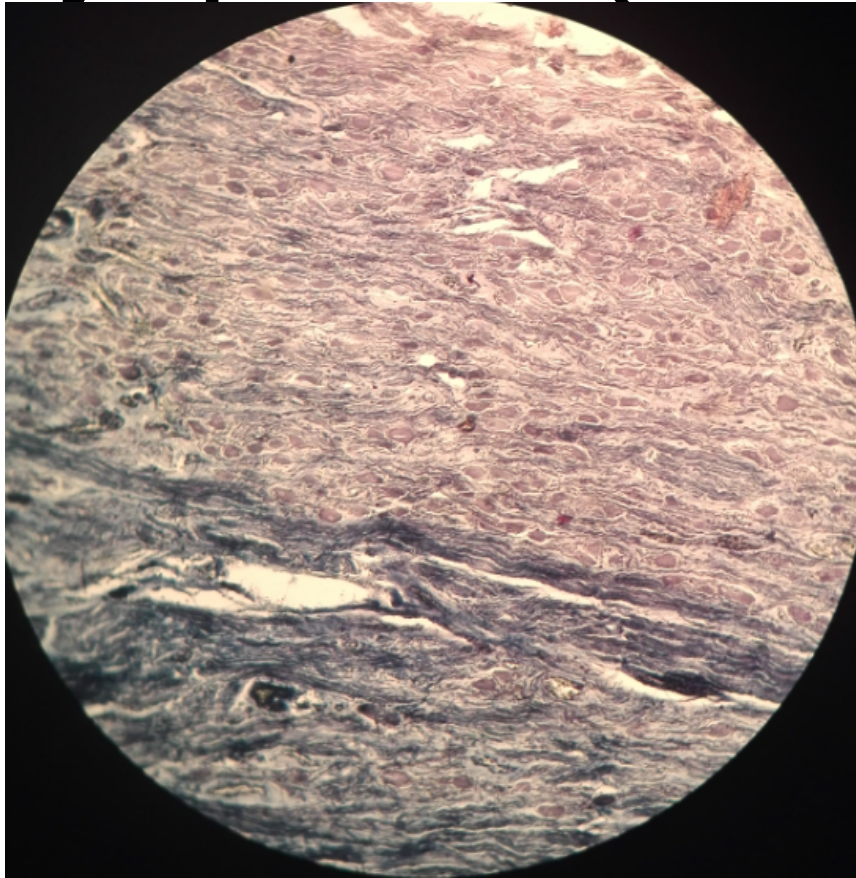


Sensory ganglion: Slide 15 Trigeminal Ganglion HP



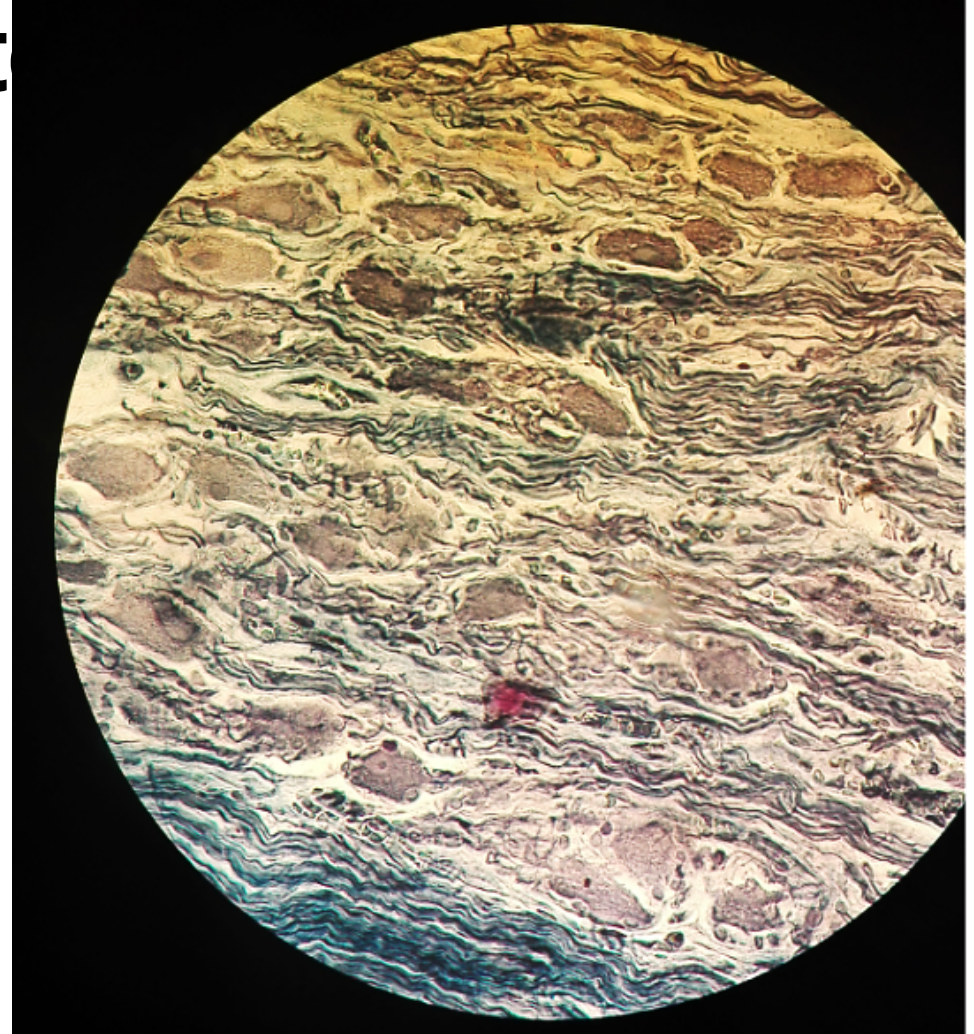
Autonomic Ganglion: Slide 17

Sympathetic (Stellate) Ganglion LP & MP

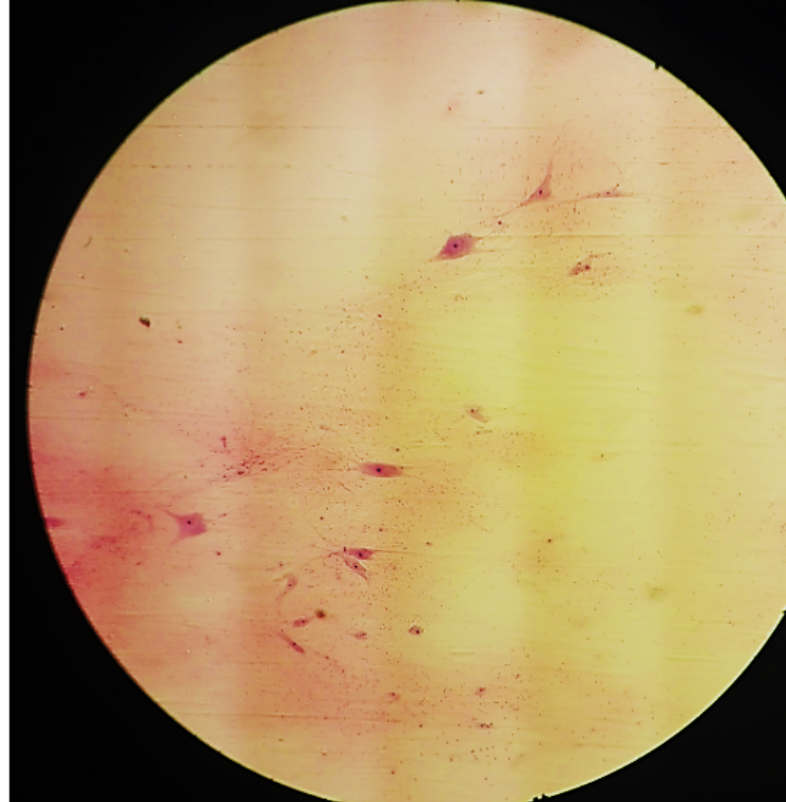


Autonomic Ganglion: Slide 17

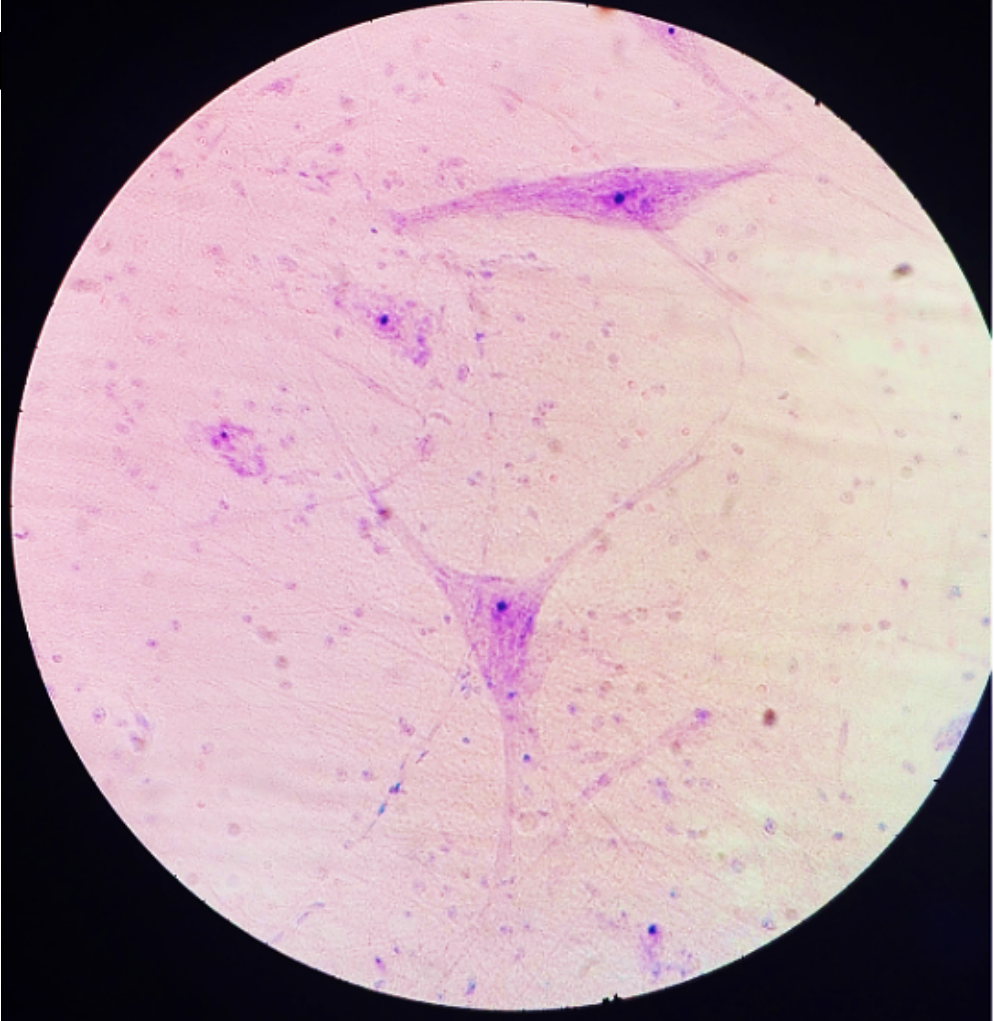
Sympathetic (Stellat



Multipolar Neurons: Slide H4.11 0x Spinal Cord LP



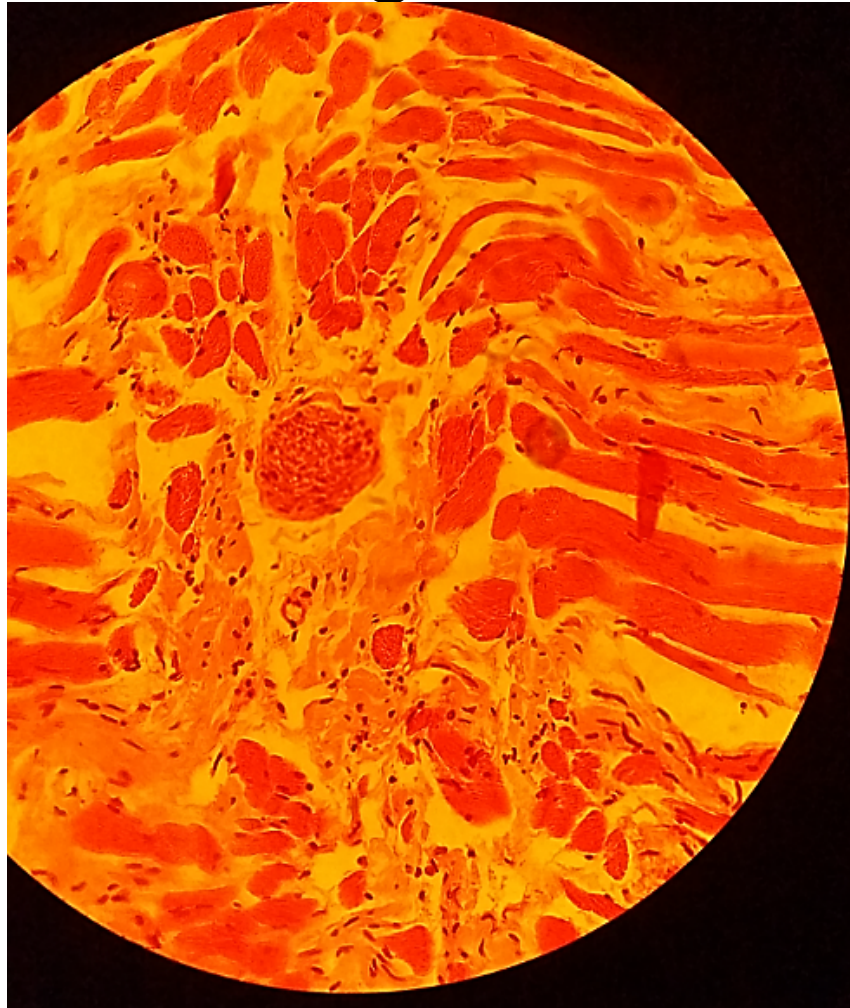
Multipolar Neurons: Slide H4.11 Ox Spinal Cord



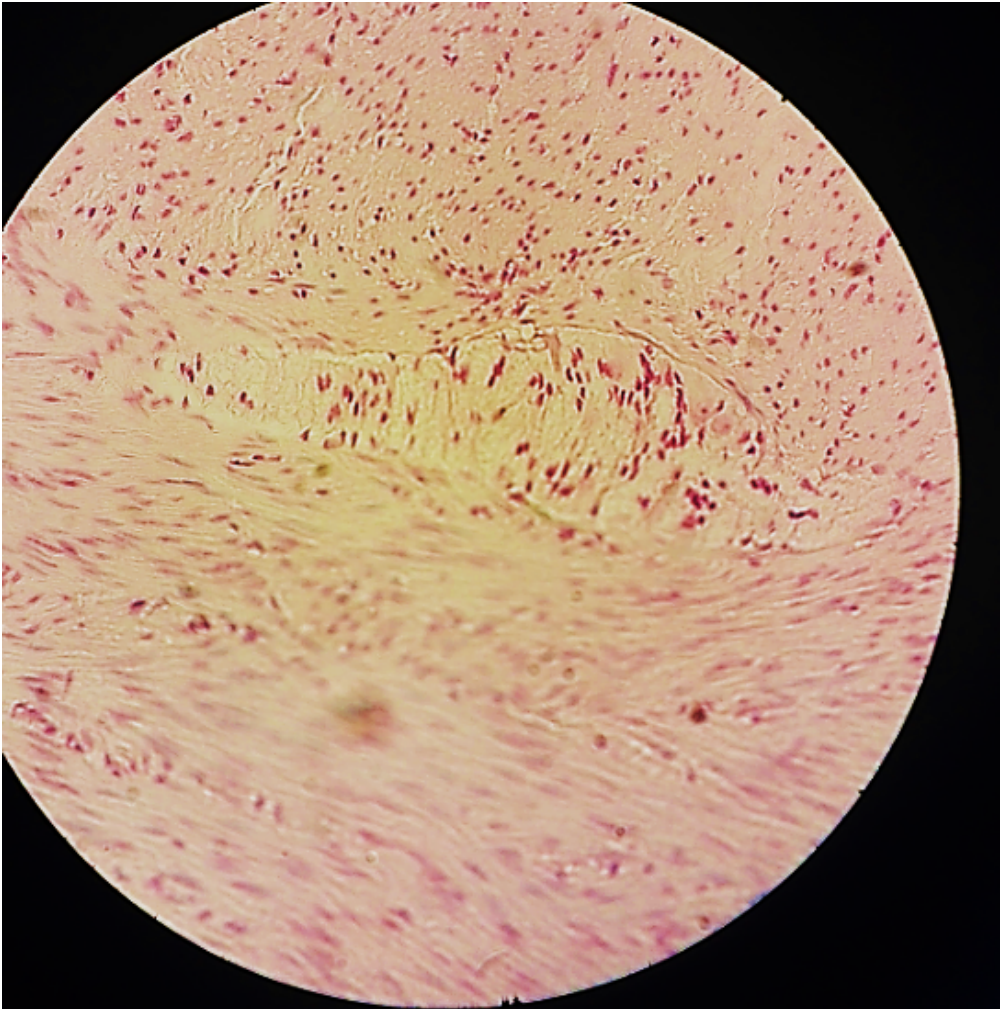
PERIPHERAL AND AUTONOMIC NERVES IN TISSUE

Slide 43/44: Tongue


HP



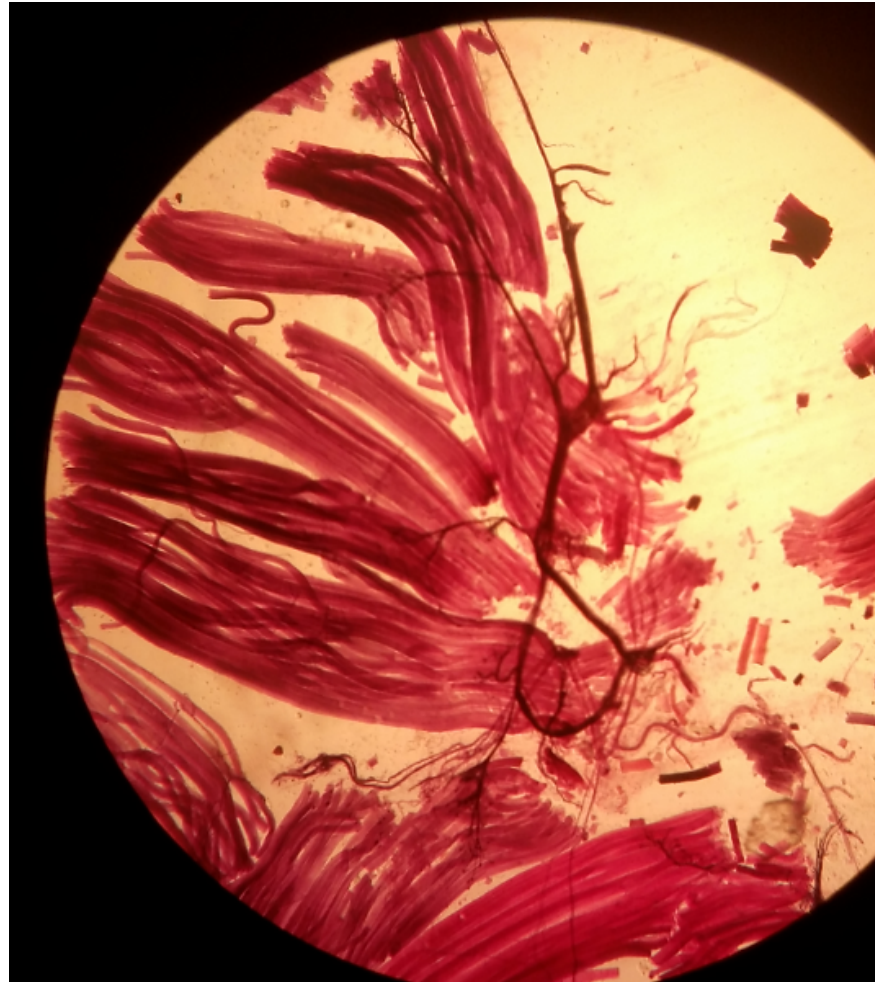
Slide 57: Colon HP



Slide 24: Motor End Plate (Ache reaction) LP (only)



Slide H4.31 Motor Nerve Endings LP (only)

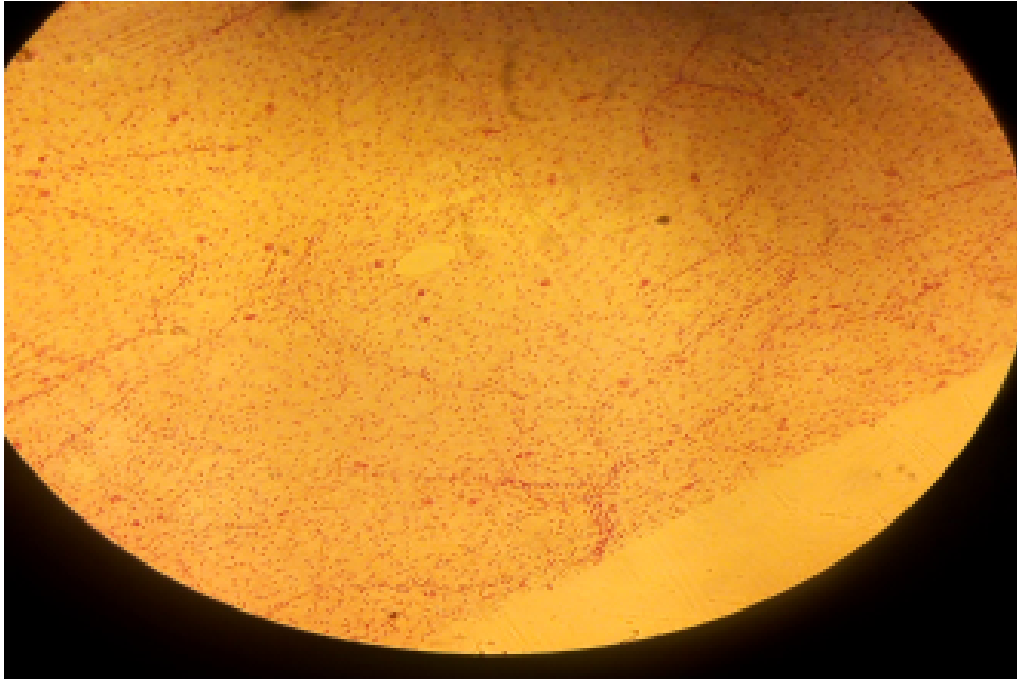


PRACTICAL 11

BLOOD VASCULAR SYSTEM

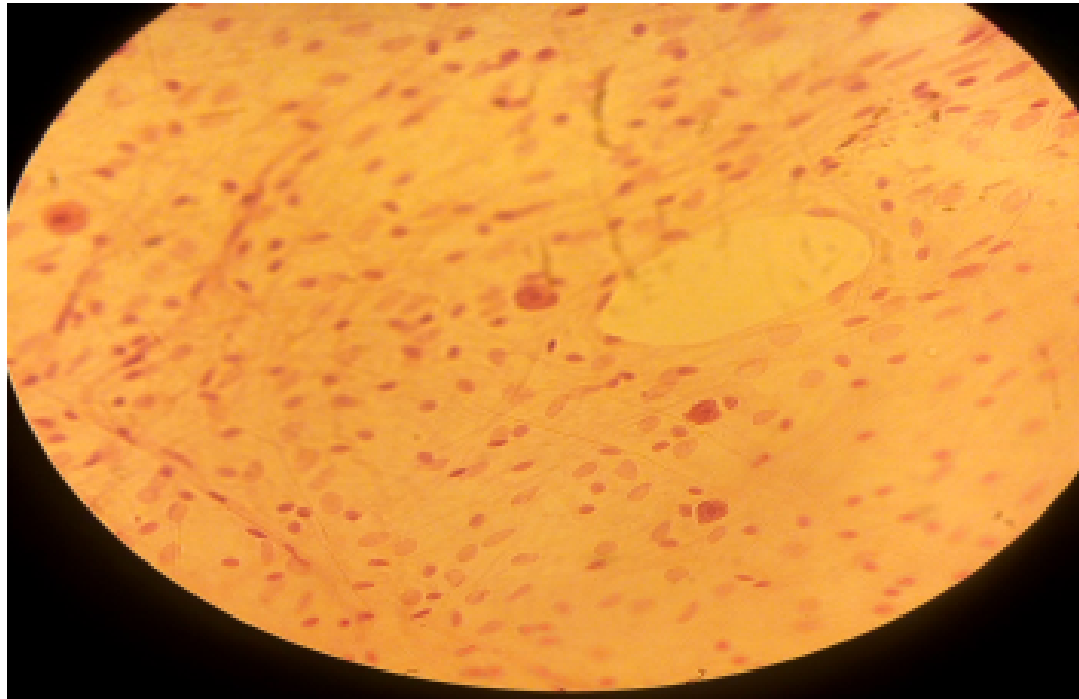
SLIDE 1 SUBCUTANEOUS TISSUE SPREAD (H&E + FERRITIN)

- LP, LOOSE/ AREOLAR CONNECTIVE TISSUE



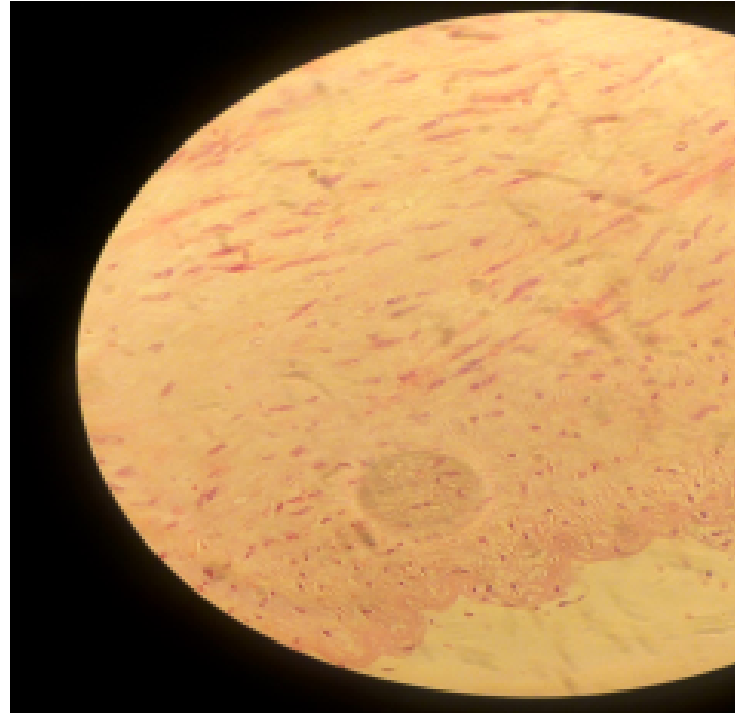
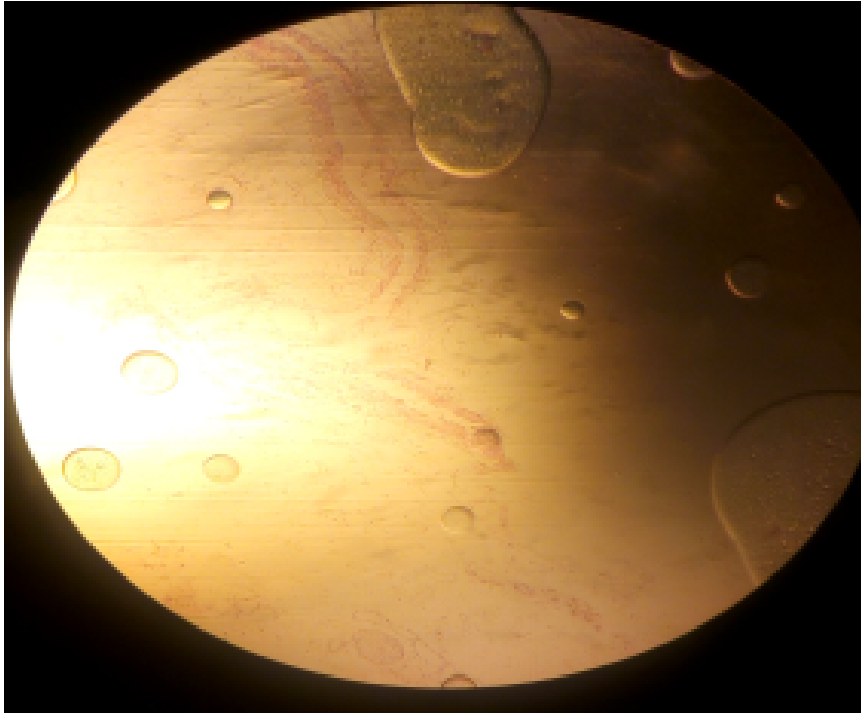
SLIDE 1 SUBCUTANEOUS TISSUE SPREAD (H&E + FERRITIN)

- HP, LOOSE/ AREOLAR CONNECTIVE TISSUE

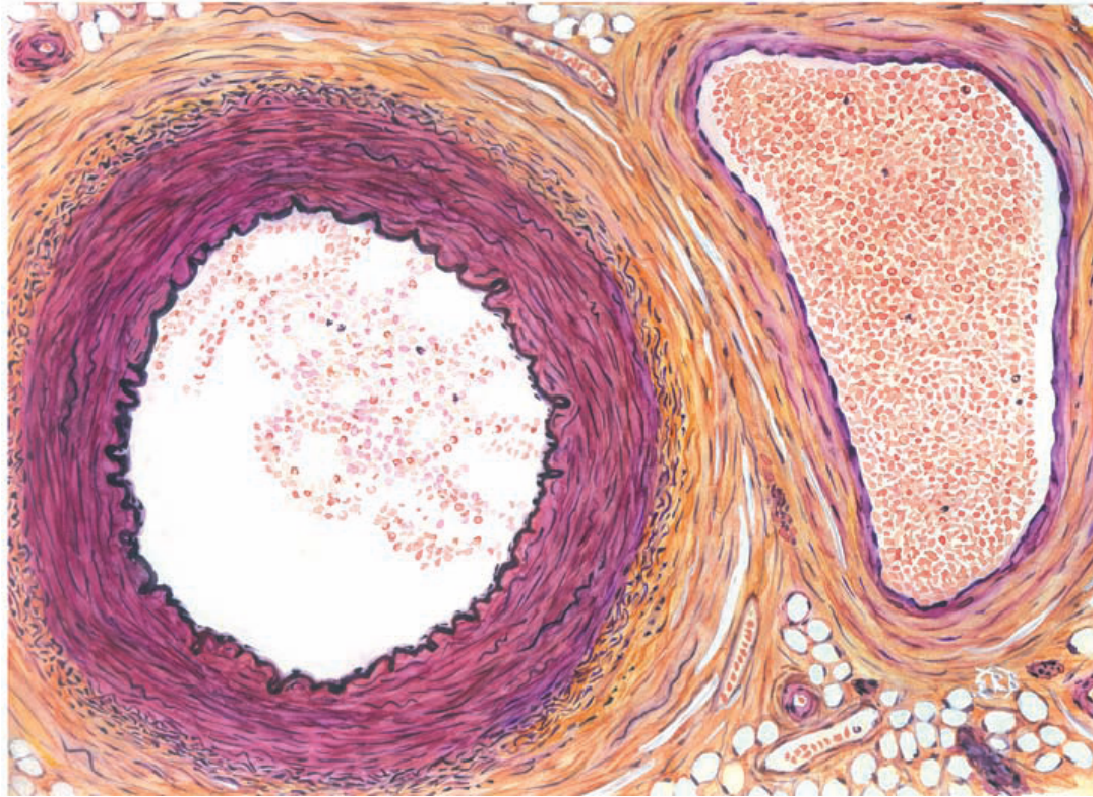


SLIDE 27 AORTA AND VENA CAVA (H&E)

- LP/MP



MUSCULAR ARTERY AND VEIN

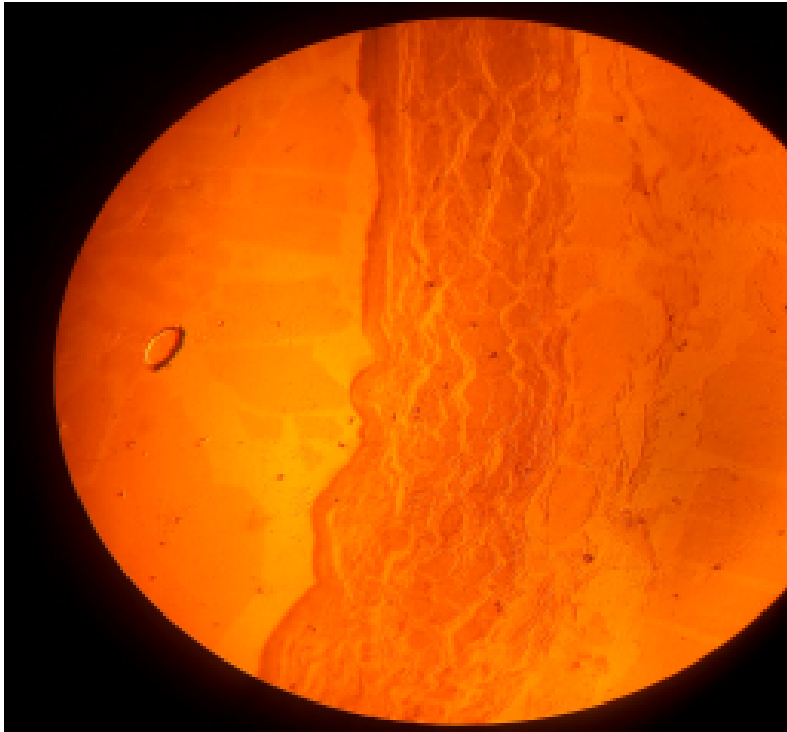


MUSCULAR ARTERY

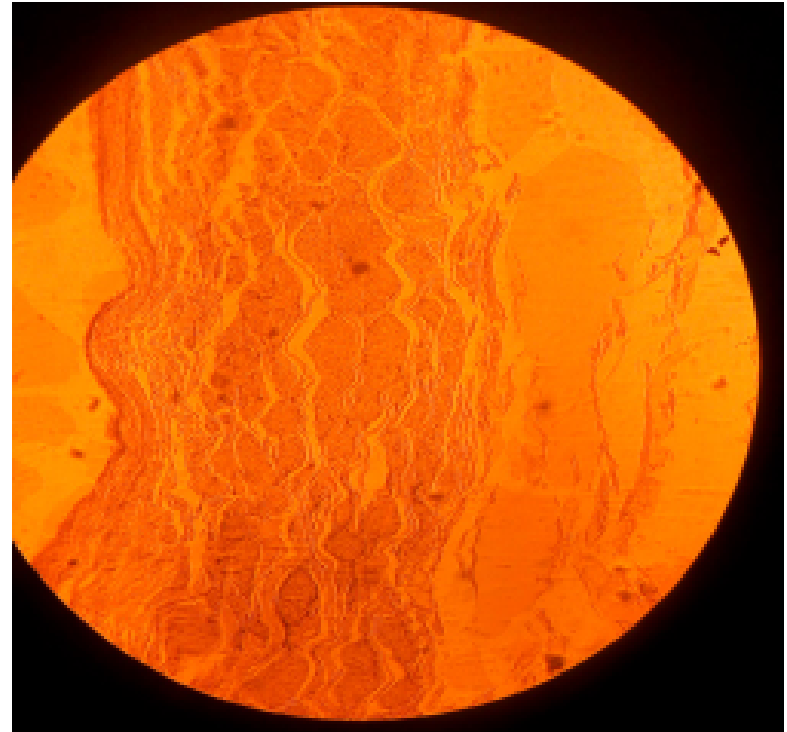


SLIDE H 8.32 VENA CAVA, HUMAN (H&E)

- LP

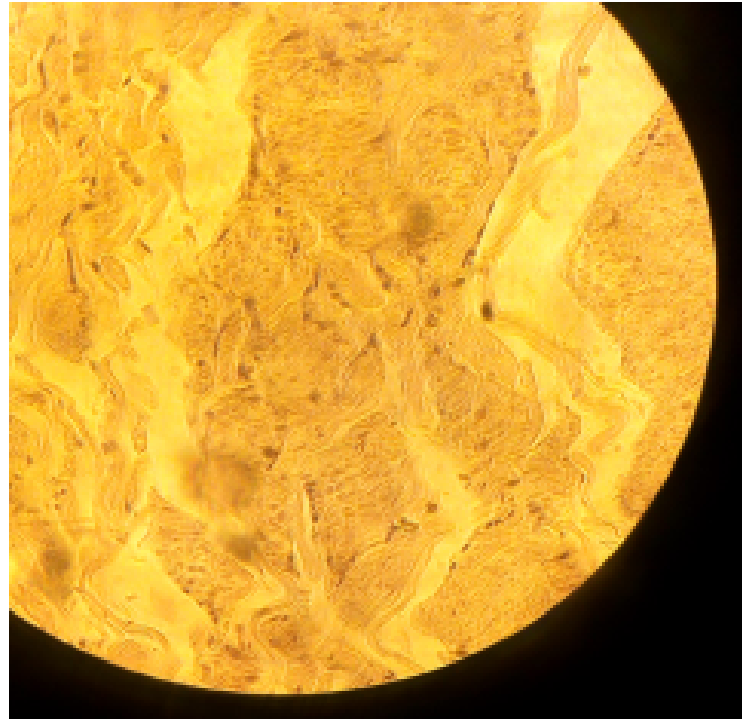
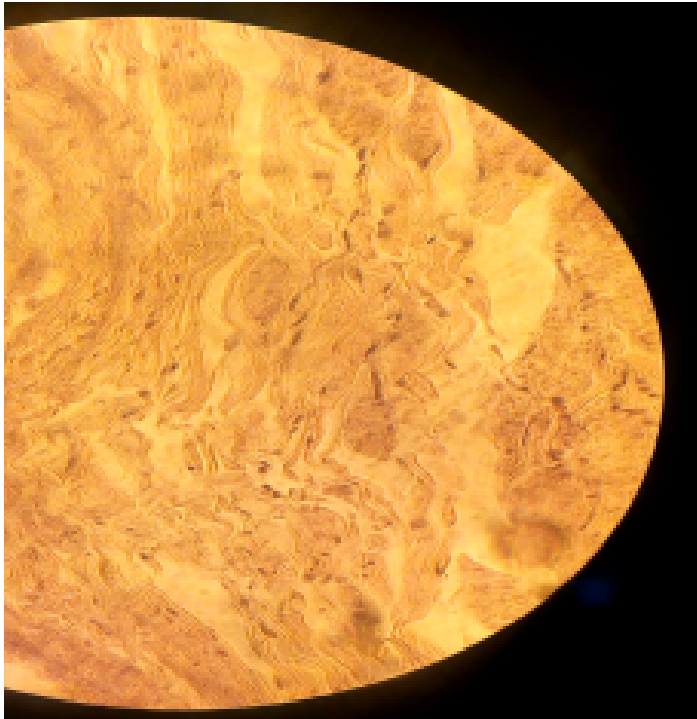


MP

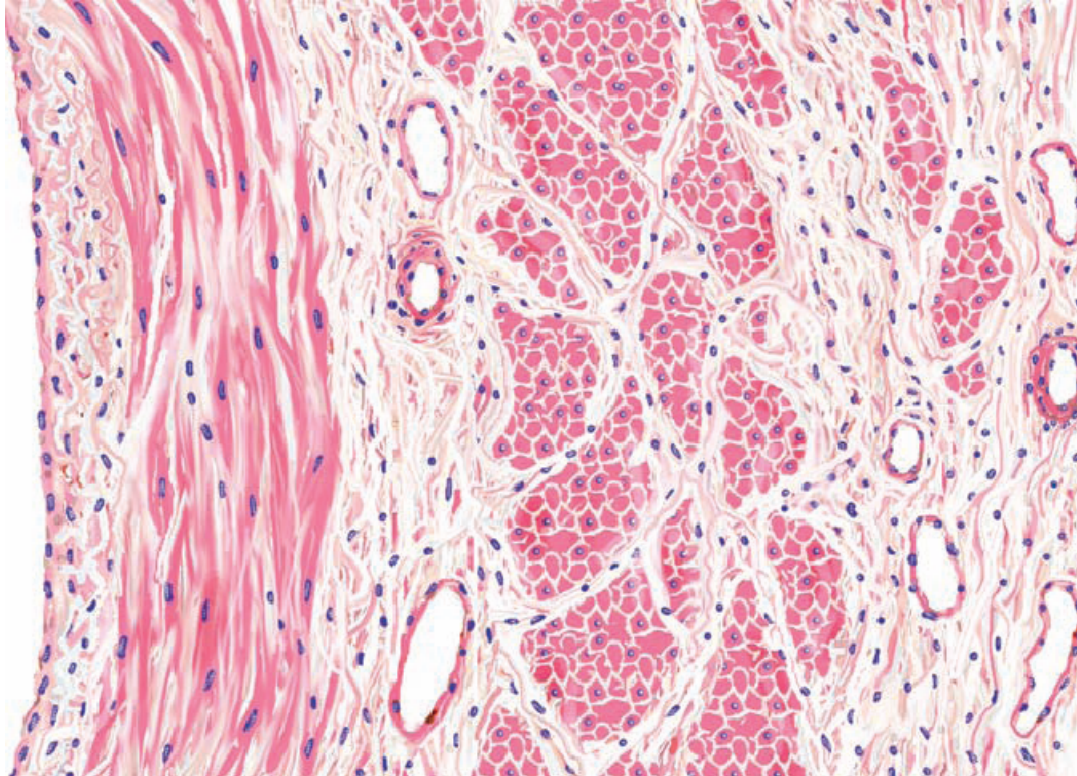


SLIDE H 8.32 VENA CAVA, HUMAN (H&E)

- HP, TUNICA ADVENTITIA WITH SMOOTH MUSCLES

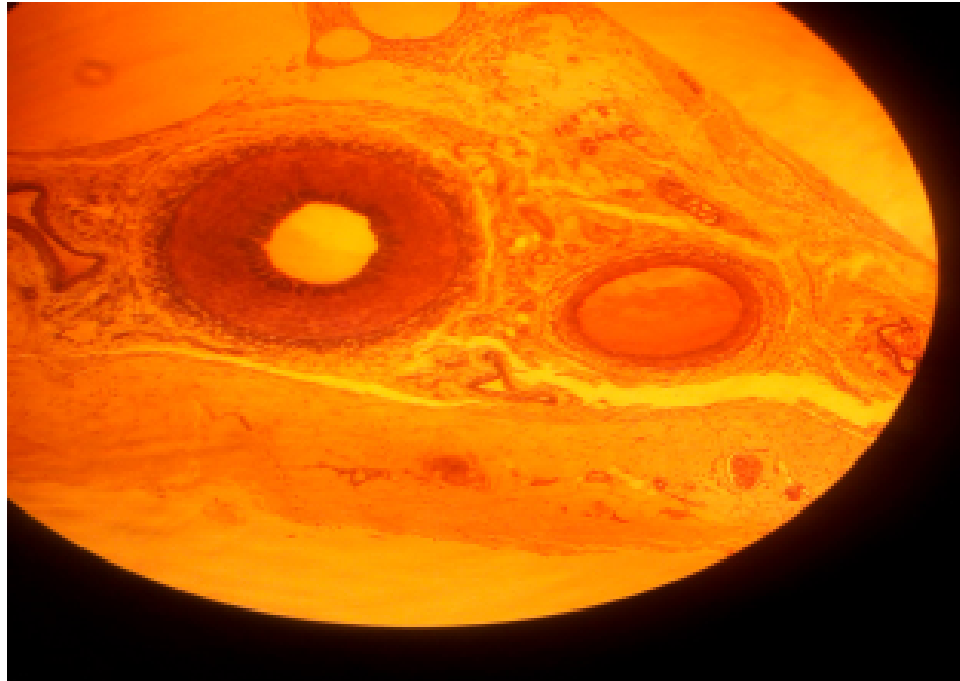


LARGE VEIN



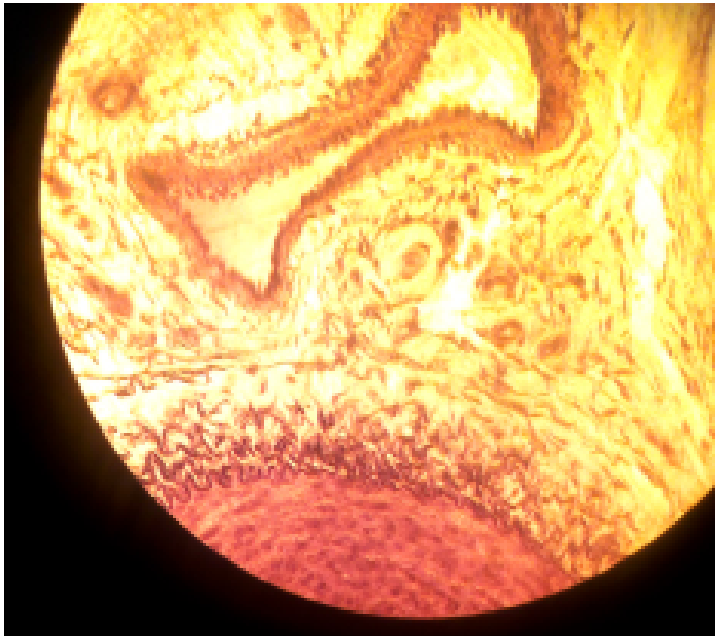
SLIDE H 8.23 ARTERY, VEIN AND NERVE

- LP

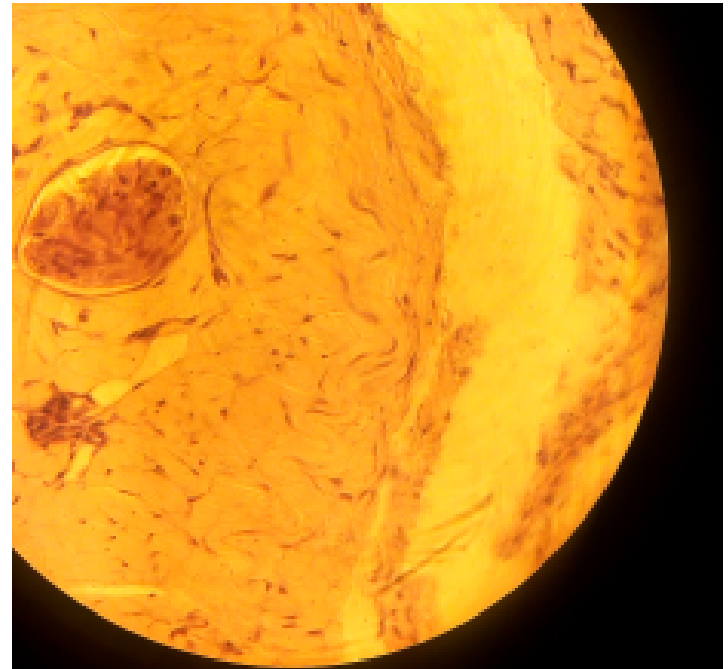


SLIDE H 8.23 ARTERY, VEIN AND NERVE

• MP VEIN

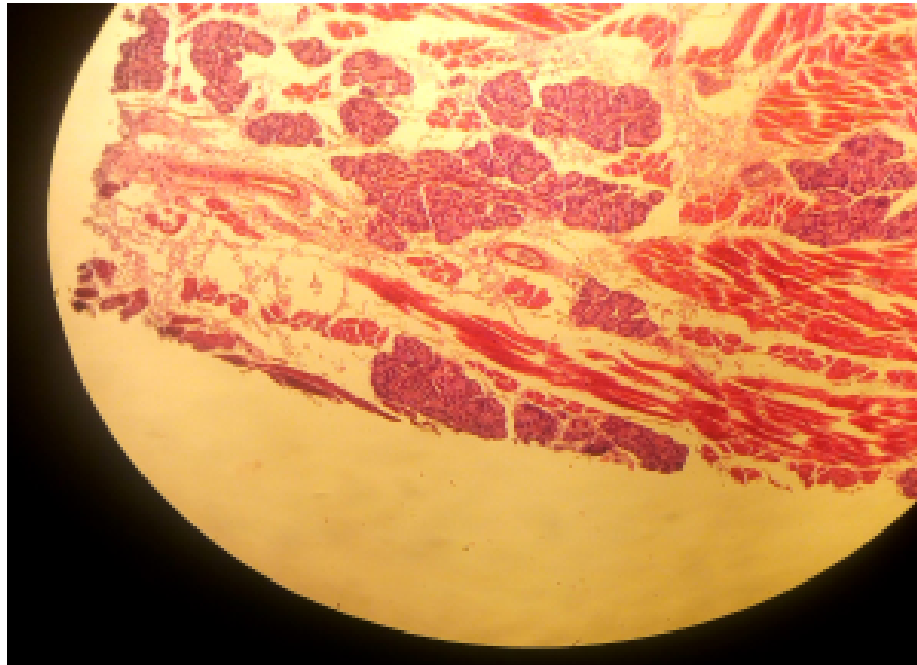


NERVE



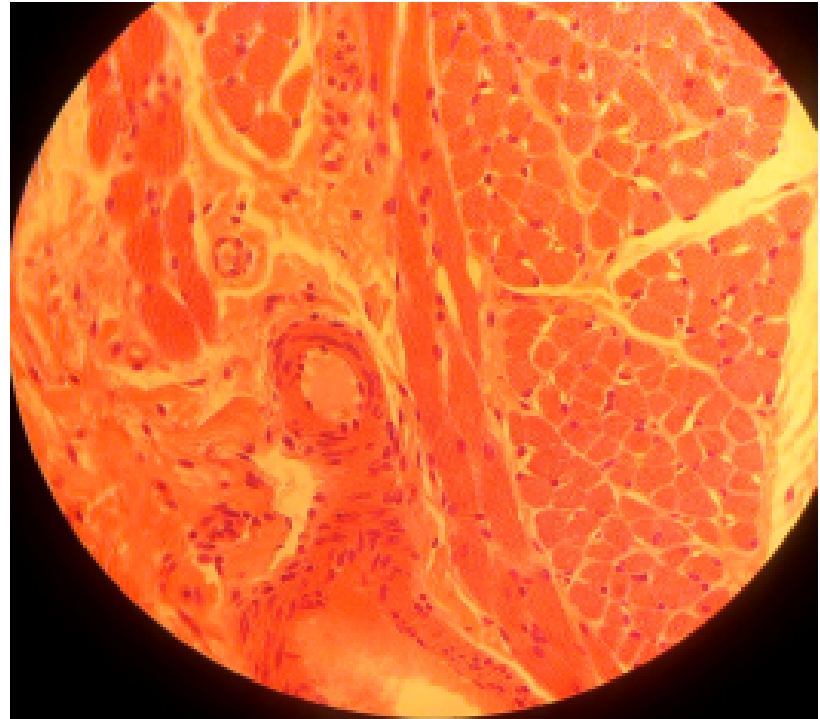
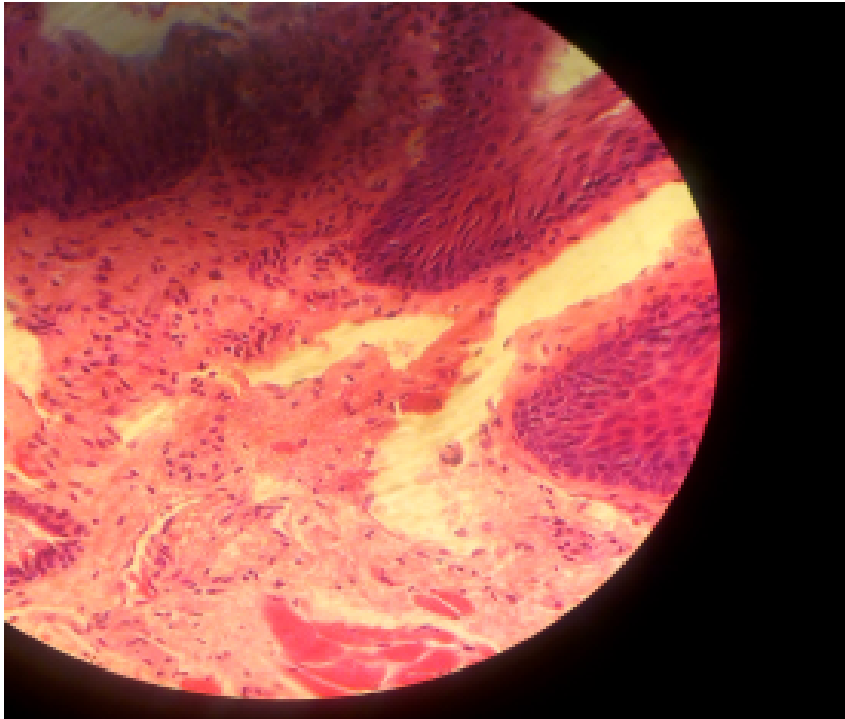
SLIDE 44 TONGUE, RABBIT (MALLORY)

- LP



SLIDE 44 TONGUE, RABBIT (MALLORY)

- HP

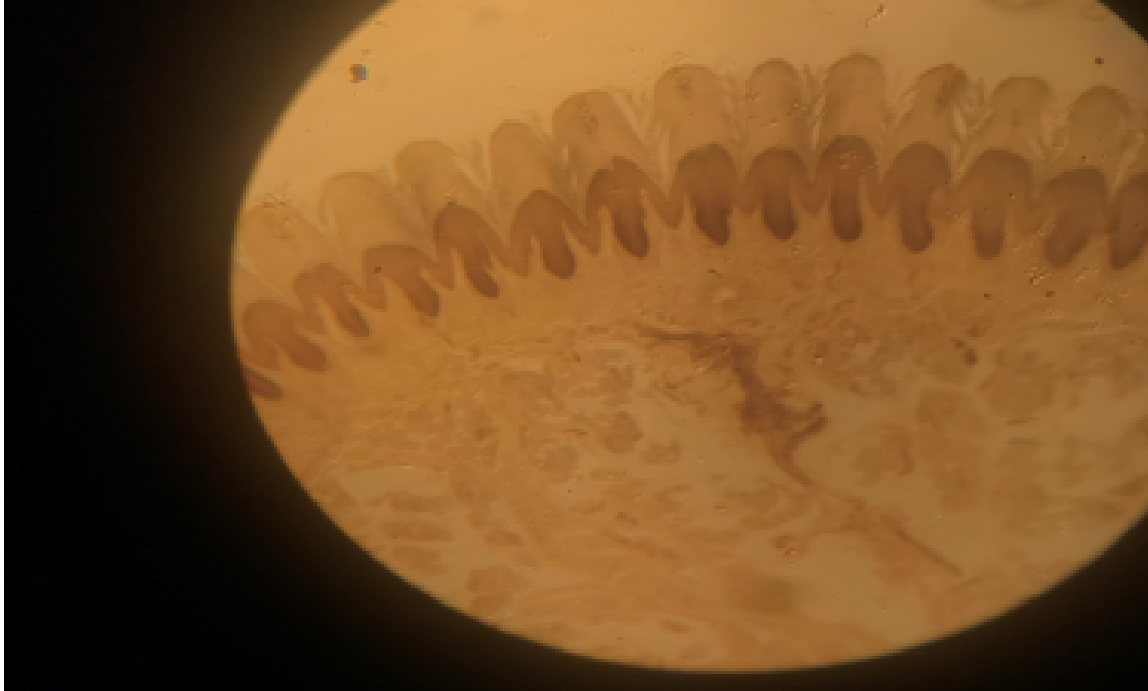

PRACTICAL 13

INTEGUMENTARY SYSTEM

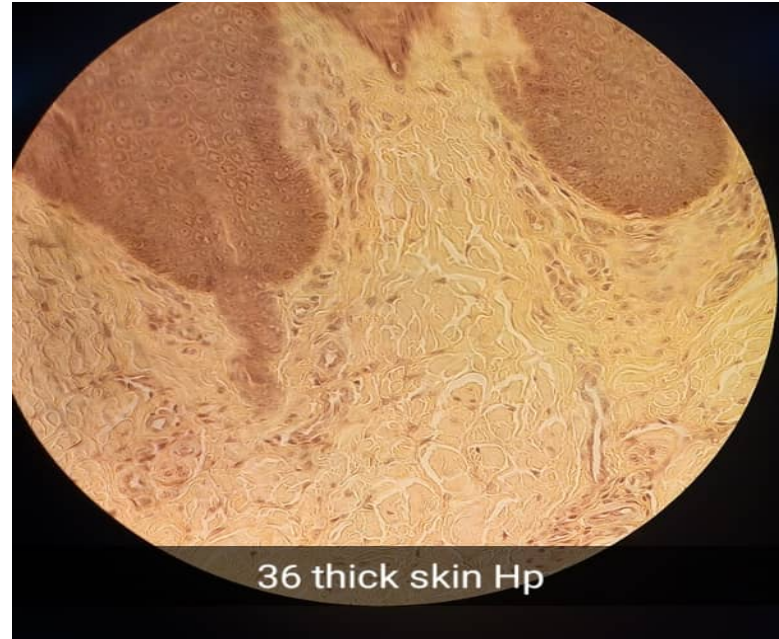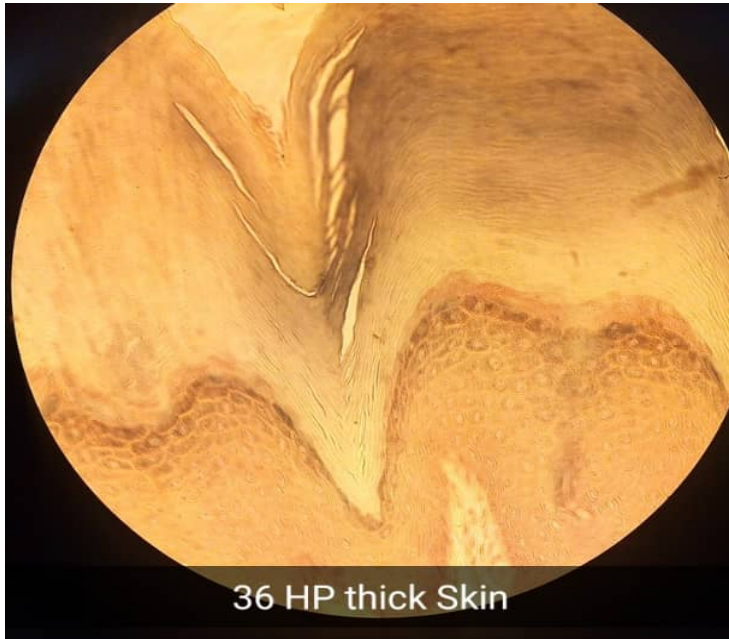SLIDE 36 THICK SKIN, HEEL (H & E)

- LP



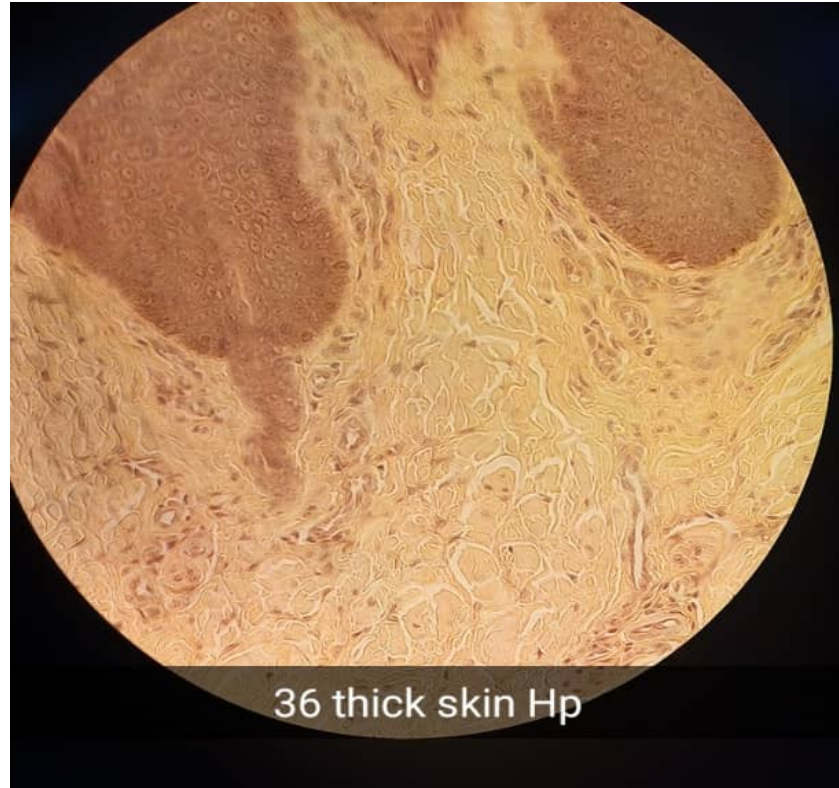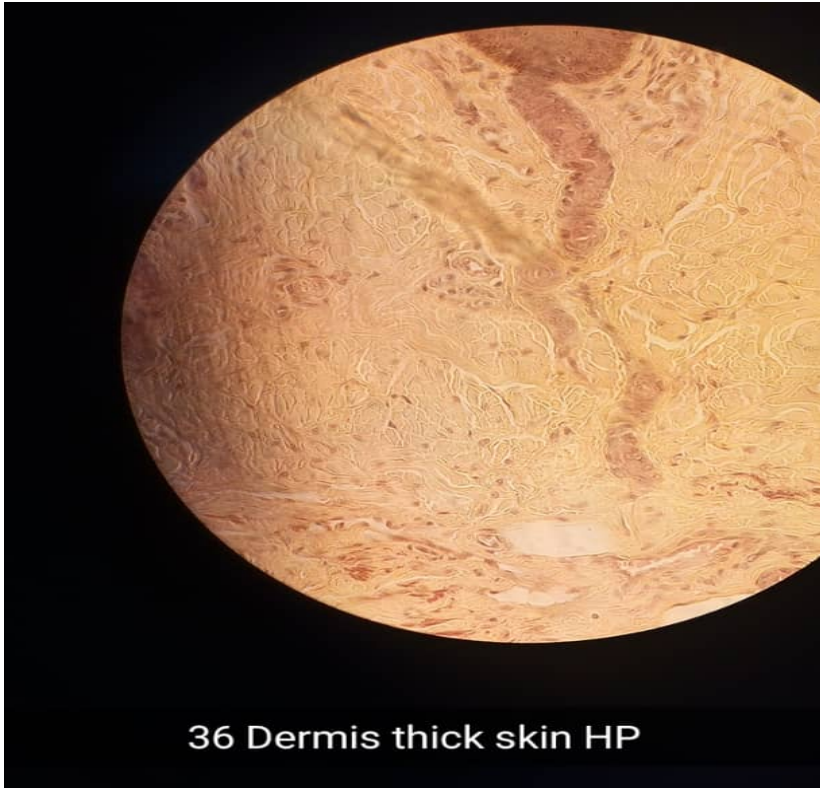
SLIDE 36 THICK SKIN, HEEL (H & E)

- HP



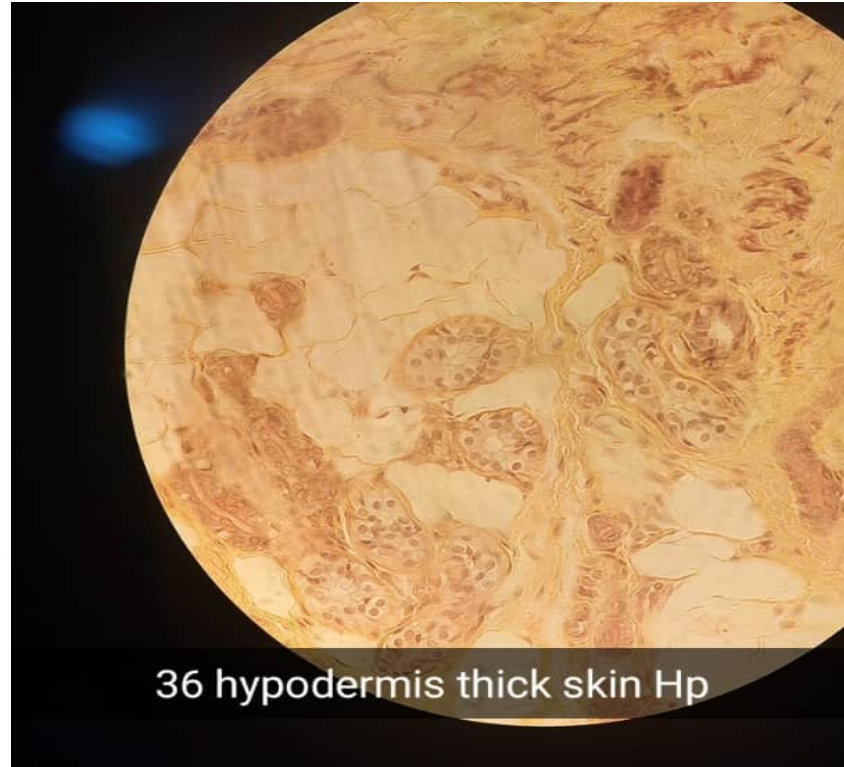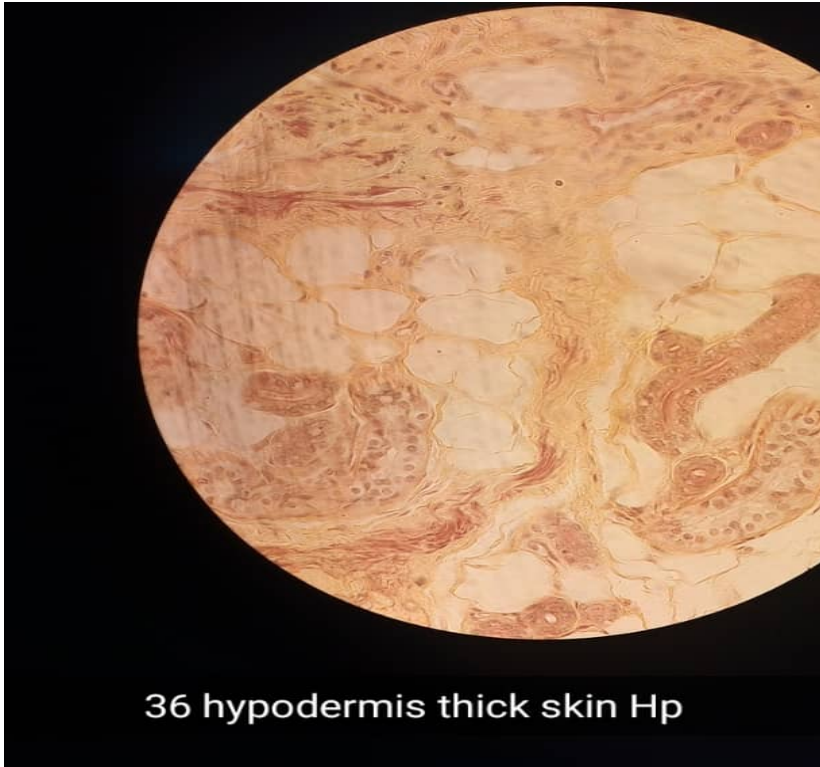SLIDE 36 THICK SKIN, HEEL (H & E)

- HP



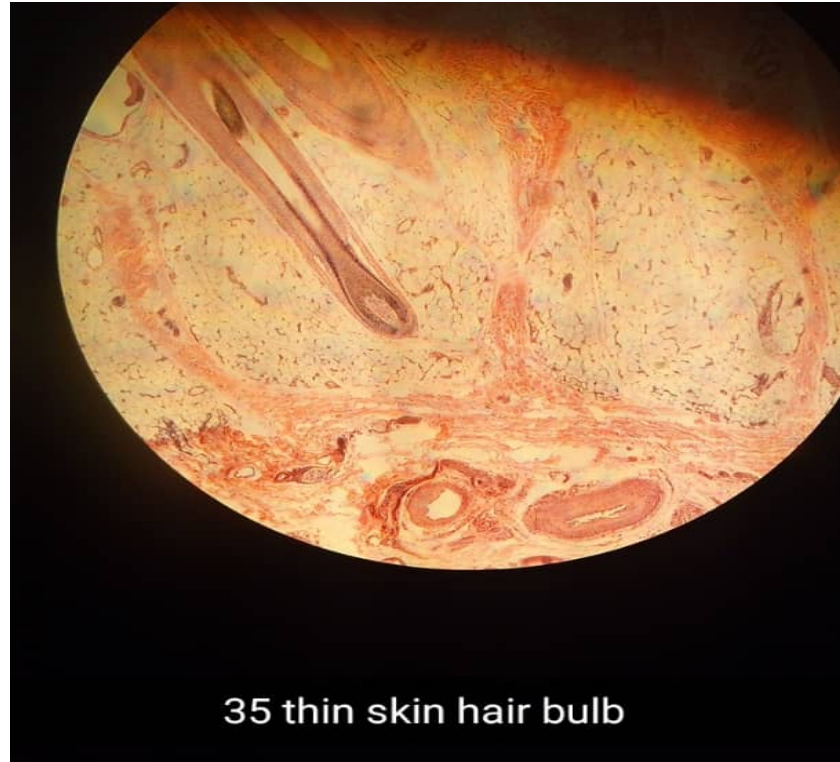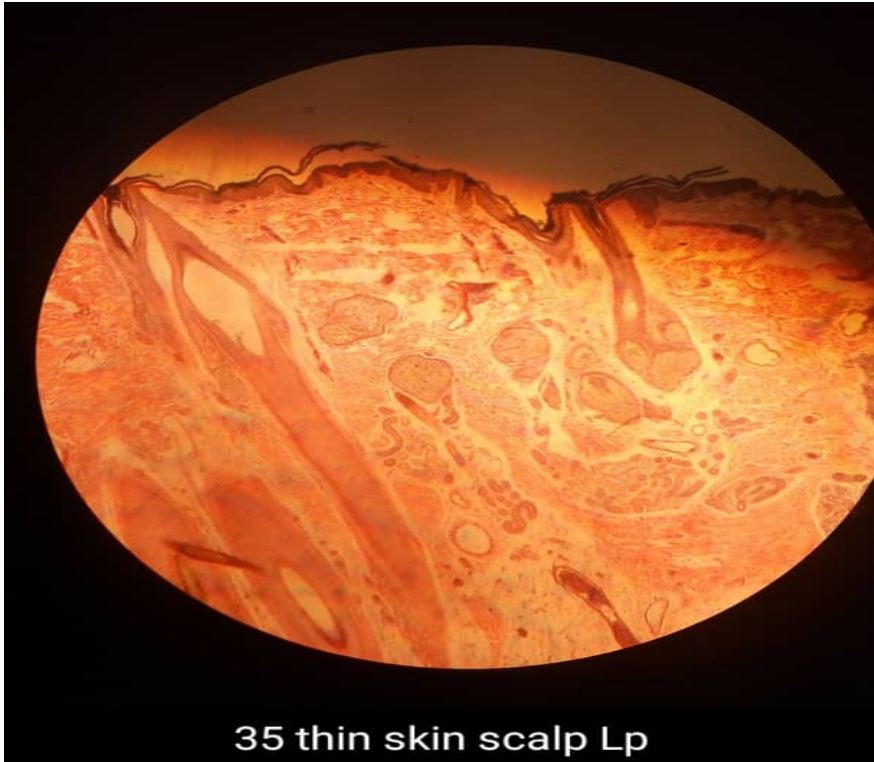SLIDE 36 THICK SKIN, HEEL (H & E)

- HP



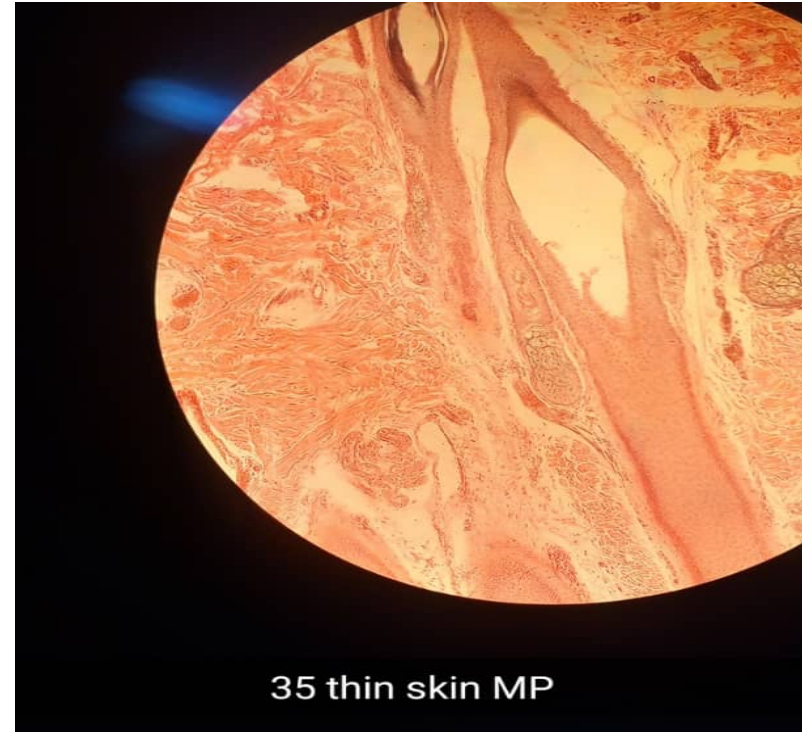
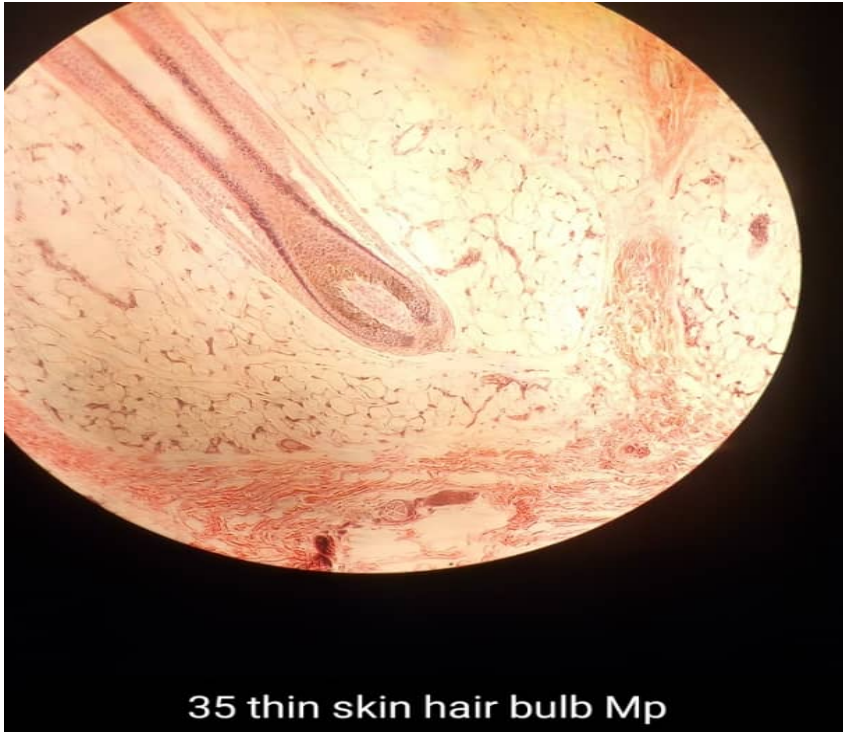SLIDE 35 THIN SKIN, SCALP (H & E)

- LP



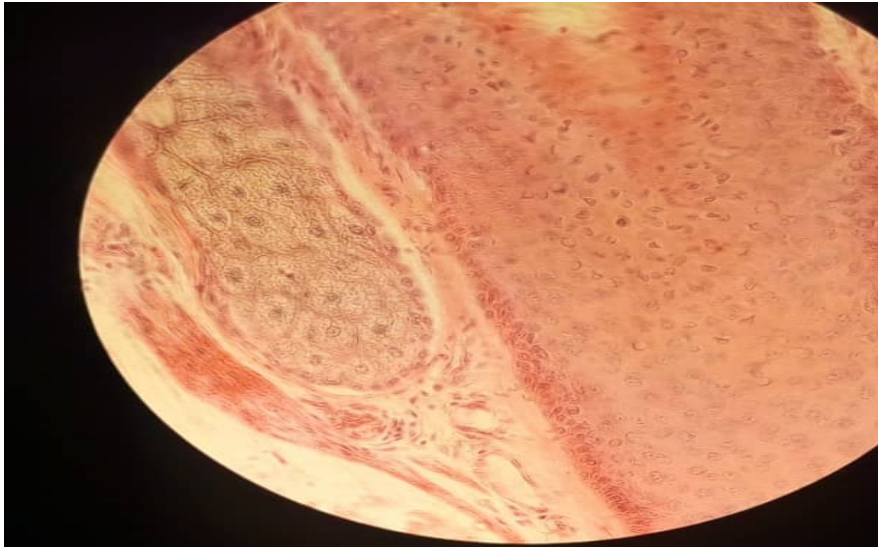
SLIDE 35 THIN SKIN, SCALP (H & E)

- MP

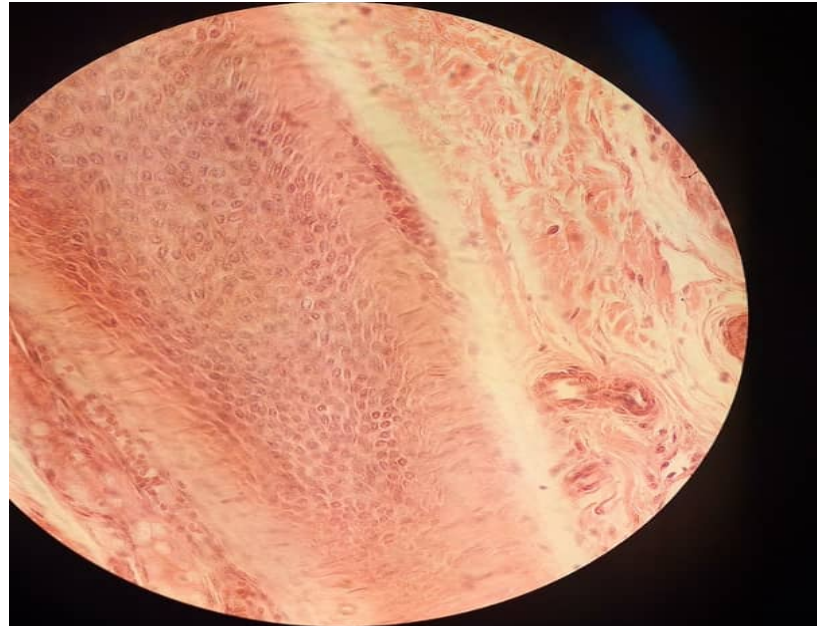


SLIDE 35 THIN SKIN, SCALP (H & E)

- HP



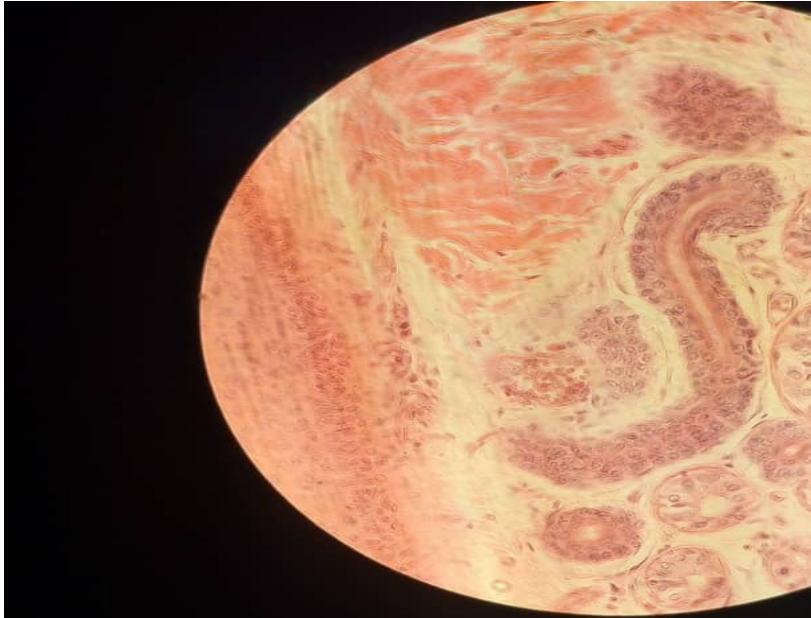
35 thin skin hair follicle + arrector pili
muscle



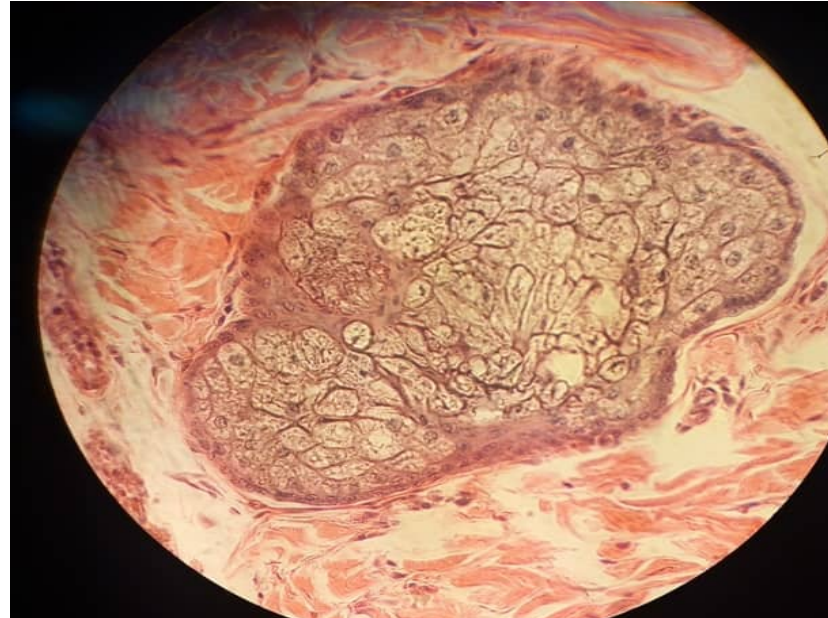
35 thin skin hair follicle Hp

SLIDE 35 THIN SKIN, SCALP (H & E)

- HP



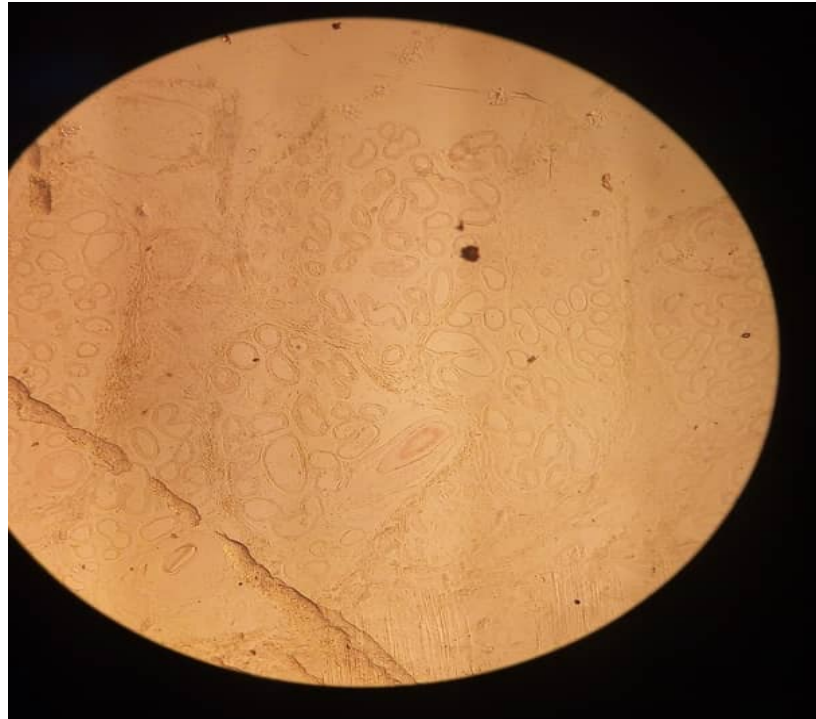
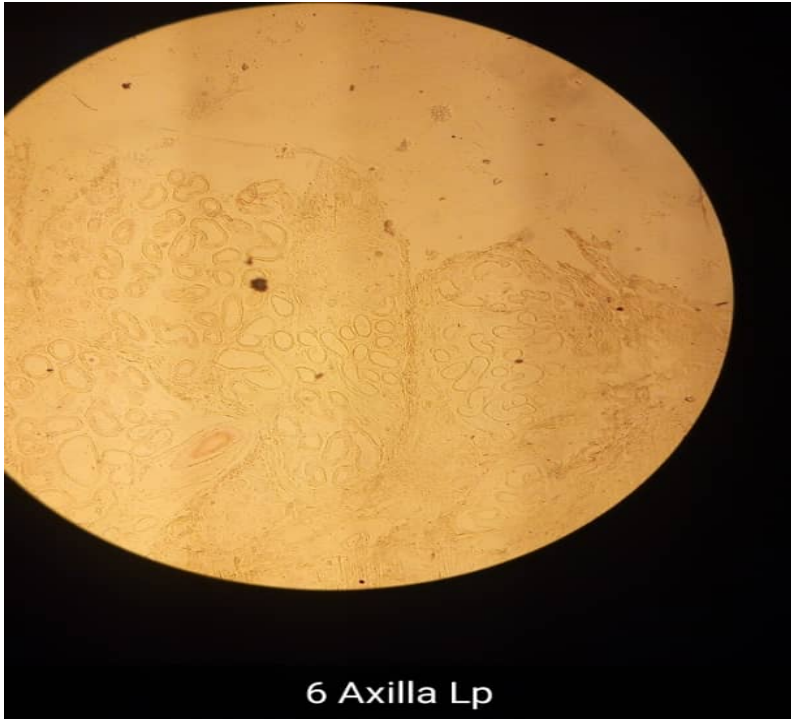Thin skin sweat eccrine sweat gland duct



Sebaceous gland

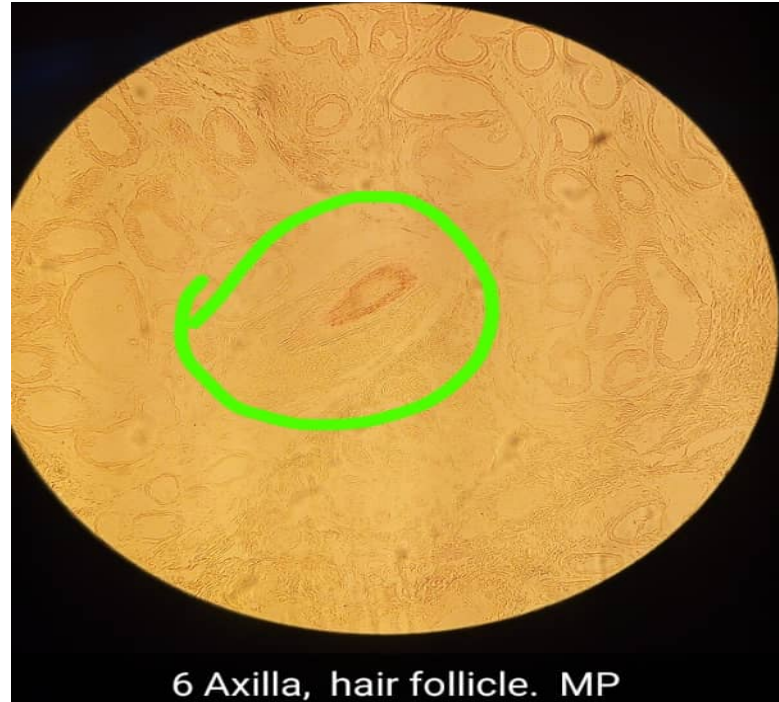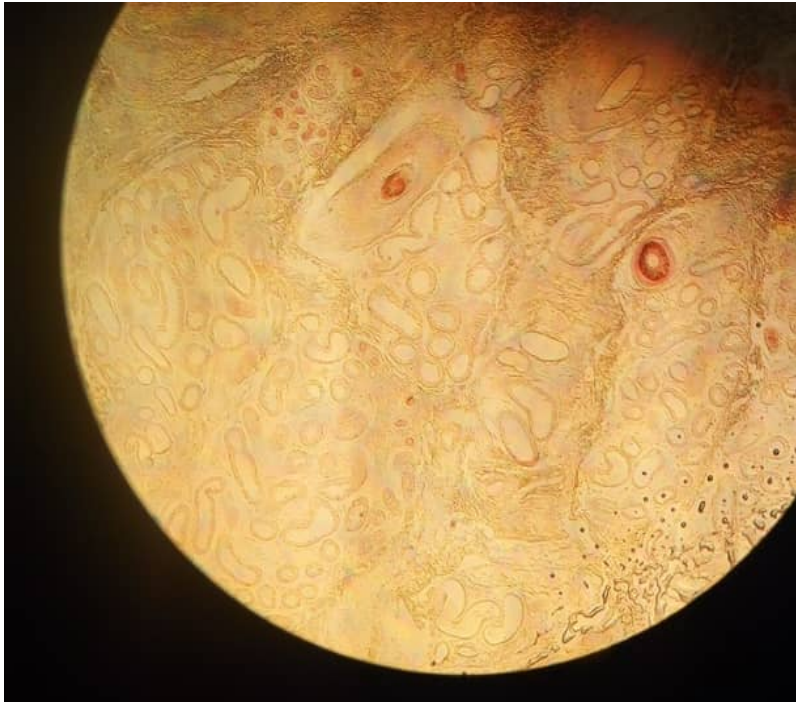SLIDE 40 SKIN OF AXILLA (H&E)

- LP



SLIDE 40 SKIN OF AXILLA (H&E)

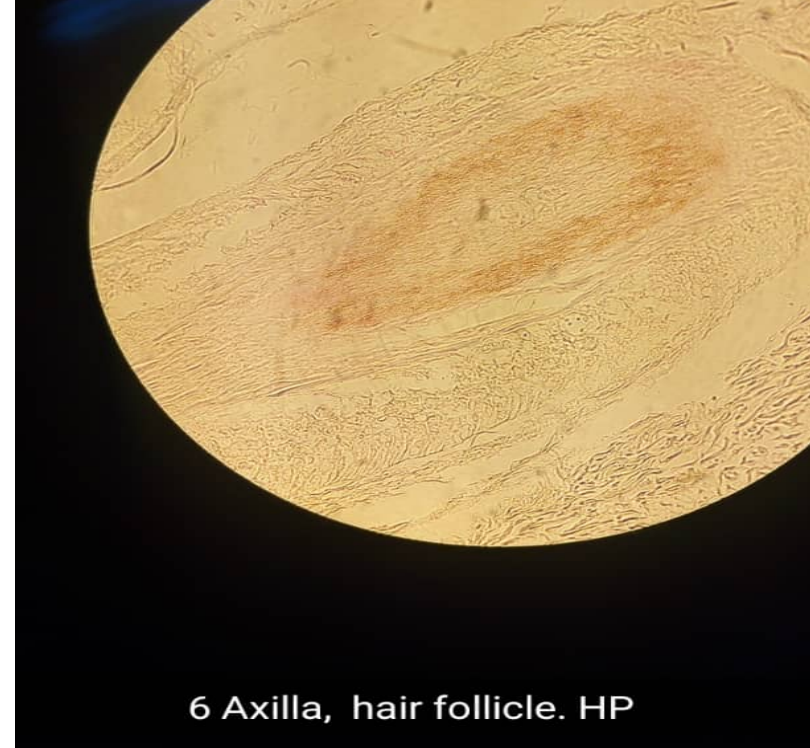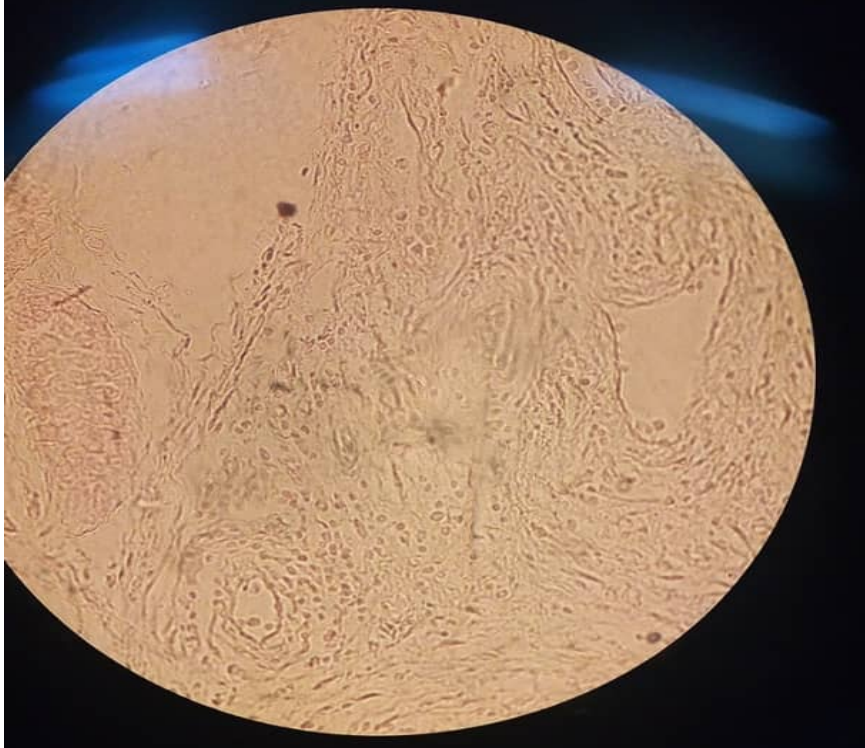- MP



6 Axilla, hair follicle. MP

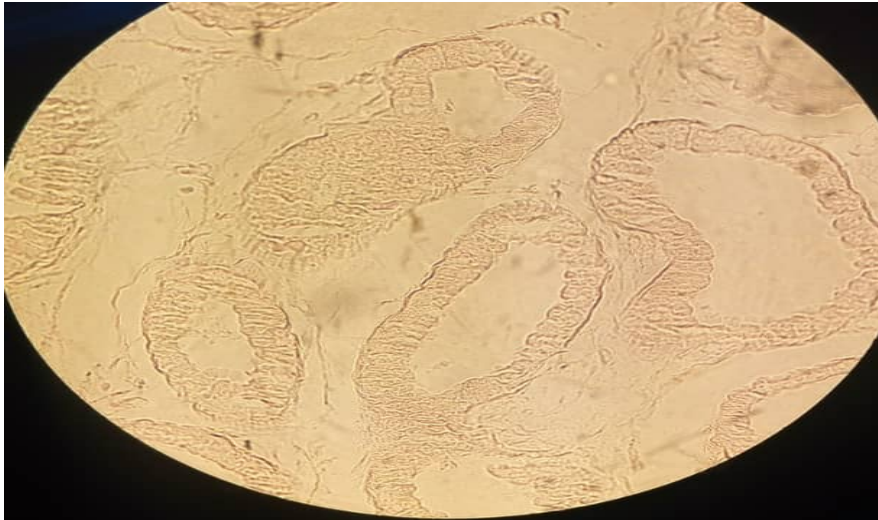
SLIDE 40 SKIN OF AXILLA (H&E)

- HP

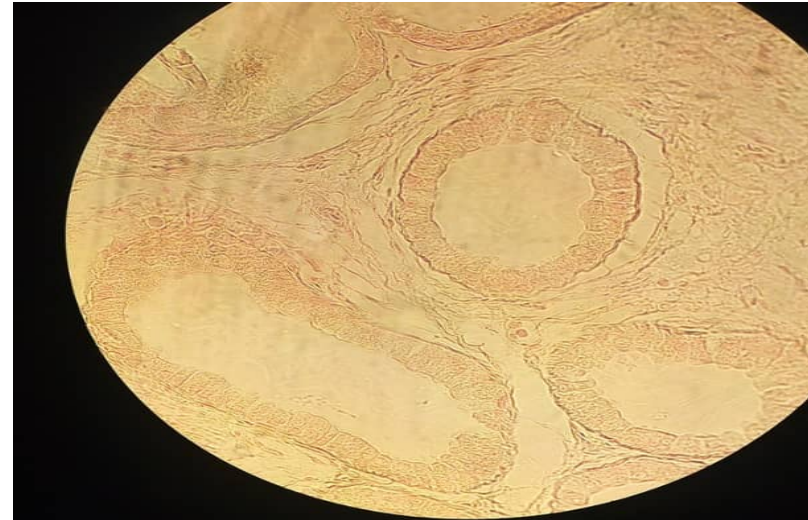


SLIDE 40 SKIN OF AXILLA (H&E)

- HP



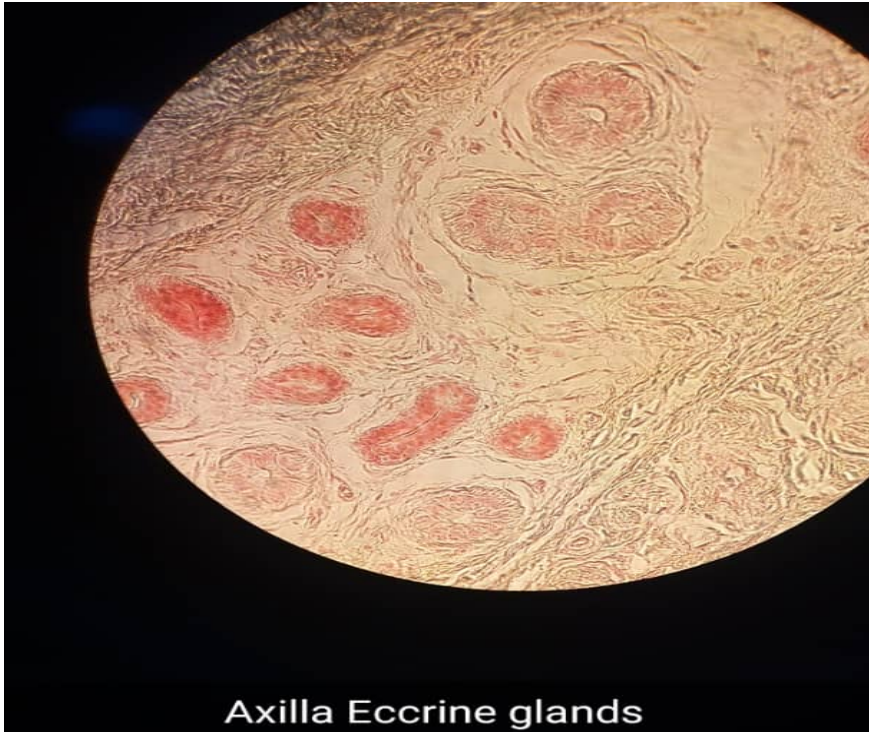6 Axilla, glands. HP



Axilla Apocrine glands HP

SLIDE 40 SKIN OF AXILLA (H&E)

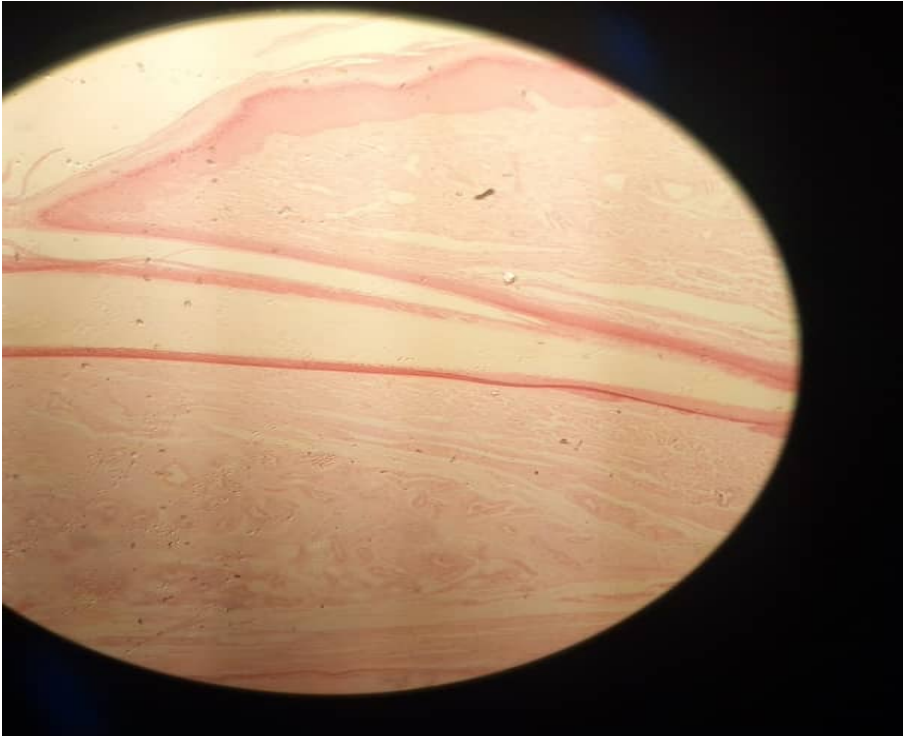
- HP



Axilla Eccrine glands

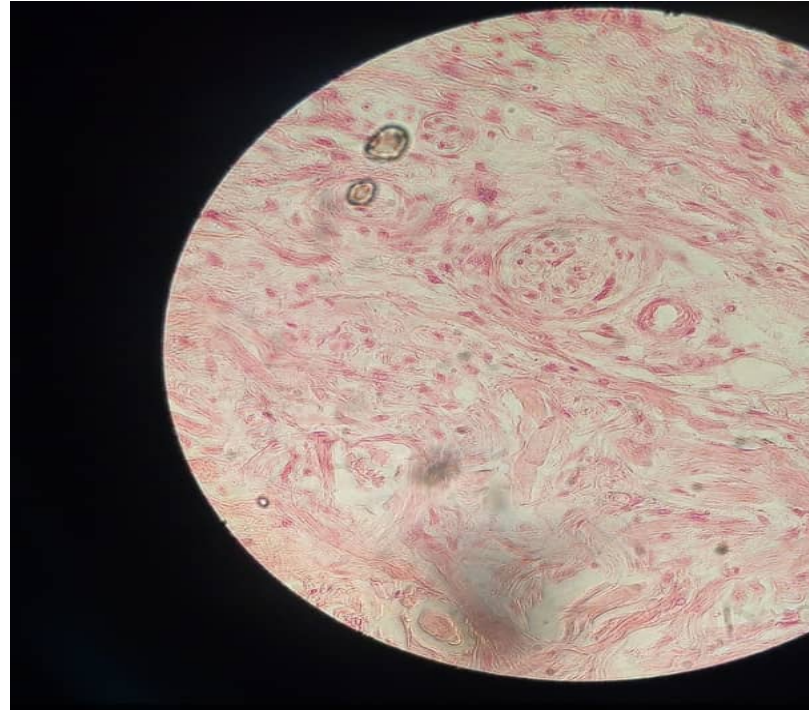
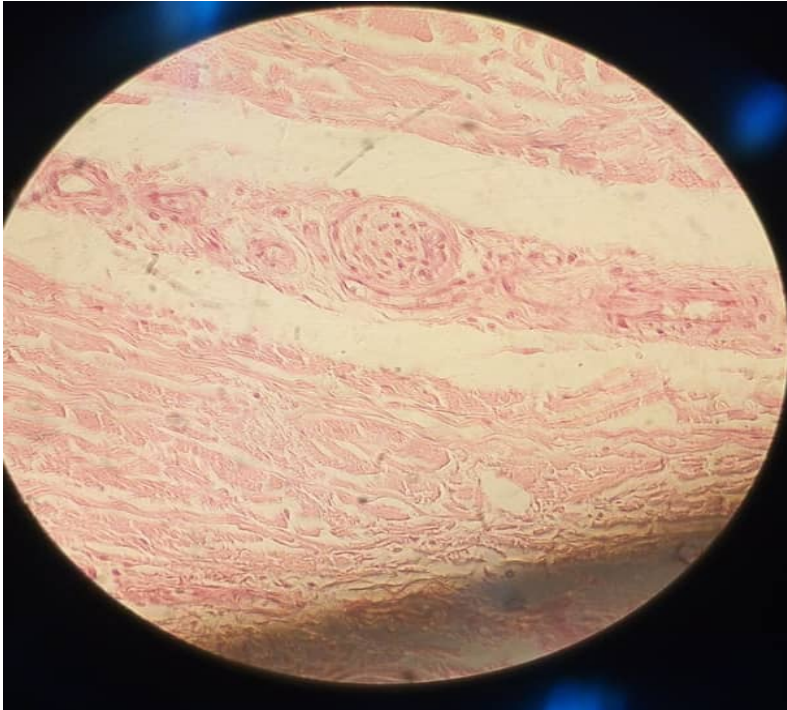
SLIDE 11.36 NAIL, LS (FINGER OR TOE)

- LP



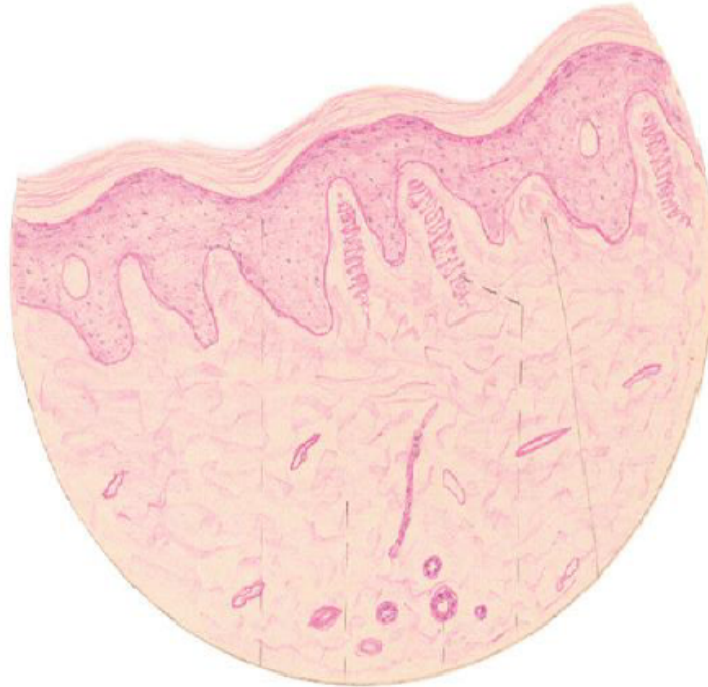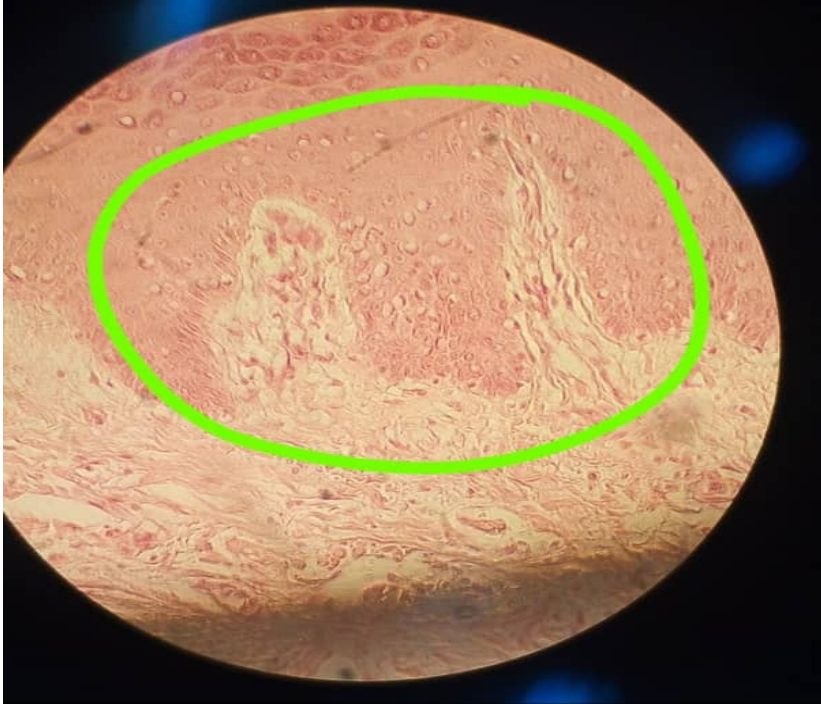SLIDE 11.36 NAIL, LS (FINGER OR TOE)

- HP, LAMELLATED OR PANCINIAN CORPUSCLES



SLIDE 11.36 NAIL, LS (FINGER OR TOE)

- HP, MEISSNER'S CORPUSCLES



PRACTICAL 20: MALE REPRODUCTIVE SYSTEM

PRESENTER: ROZALIA NJOBVU

Male reproductive system

- Responsible for production of *spermatozoa* and their delivery into female reproductive tract; Divided four major functional areas;
- Testis
- Ducts
- Seminal vesicles and Prostate gland
- Penis.

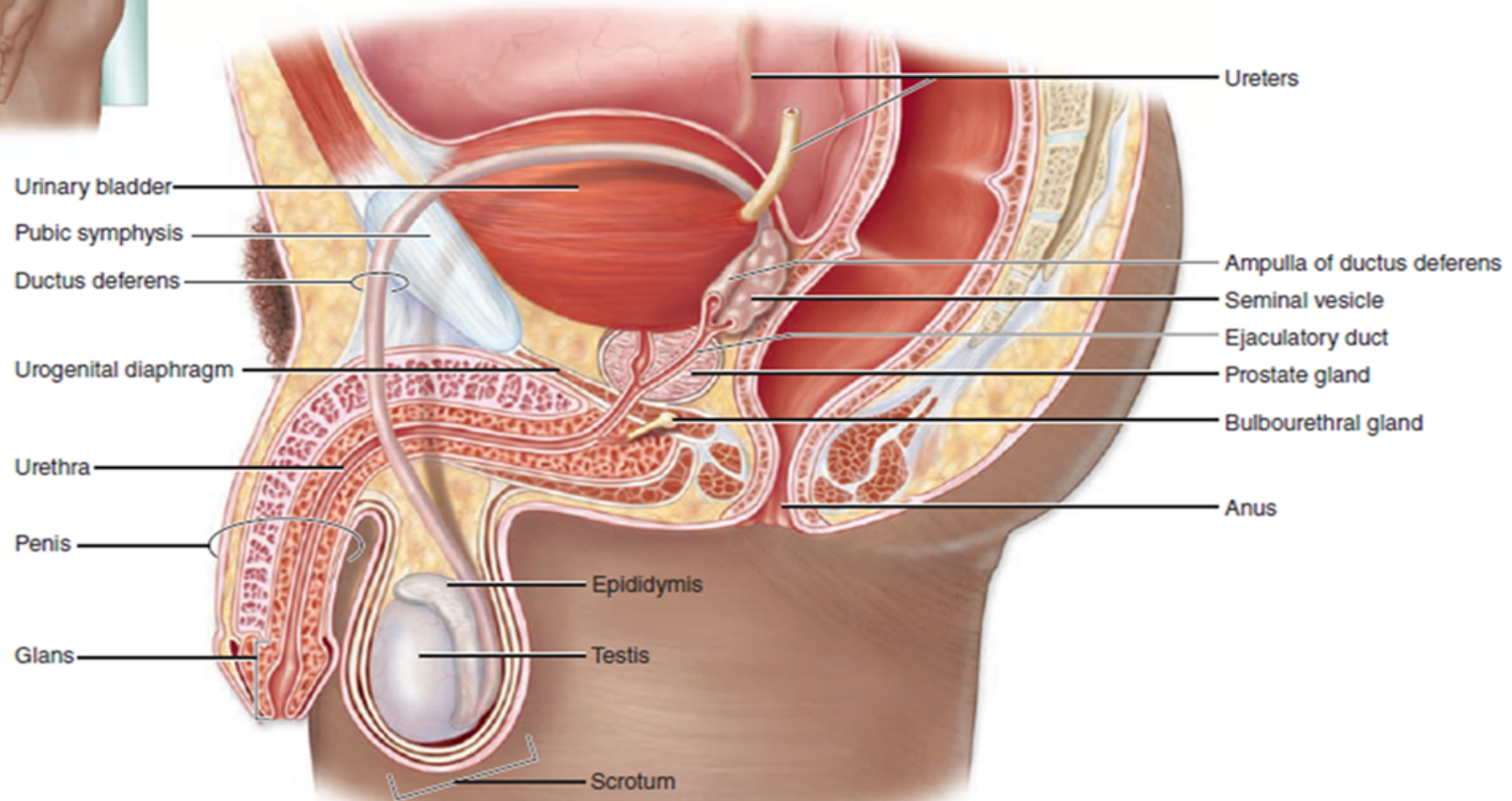
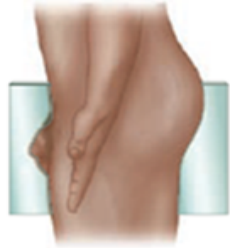Function of Male Reproductive organs

- **1. *Testes*** or male gonads, paired organs lying in the ***scrotal sac***, responsible for production of the male gametes, ***spermatozoa***, and secretion of male sex hormones, principally ***testosterone***.
- **2. A system of ducts - *ductuli efferentes, epididymis, ductus (vas) deferens* and *ejaculatory duct***;
- Stores and carries spermatozoa from each testis.
- Ejaculatory ducts converge on the urethra, where spermatozoa are expelled into female reproductive tract during copulation.

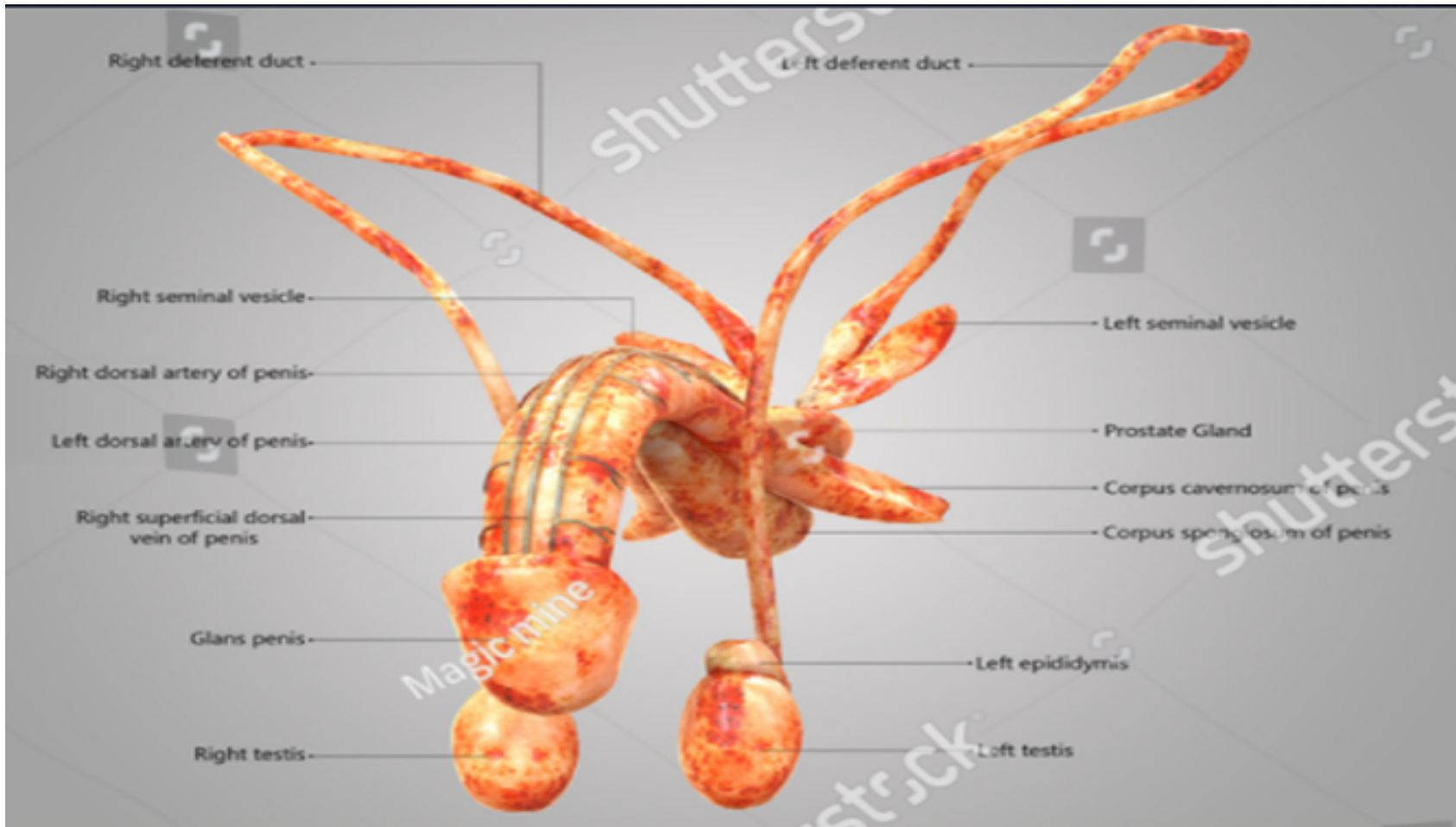
Contd

- **3. Paired seminal vesicles** and single **prostate gland**, secrete a nutritive and lubricating fluid - **seminal fluid** where spermatozoa are conveyed to female reproductive tract. **Semen**, fluid expelled during ejaculation, consists of seminal fluid, spermatozoa, and some desquamated duct lining cells.
- **4. Penis** organ of copulation, pair of small **bulbourethral glands of Cowper**, secrete lubricating fluid - passage of semen at ejaculation.

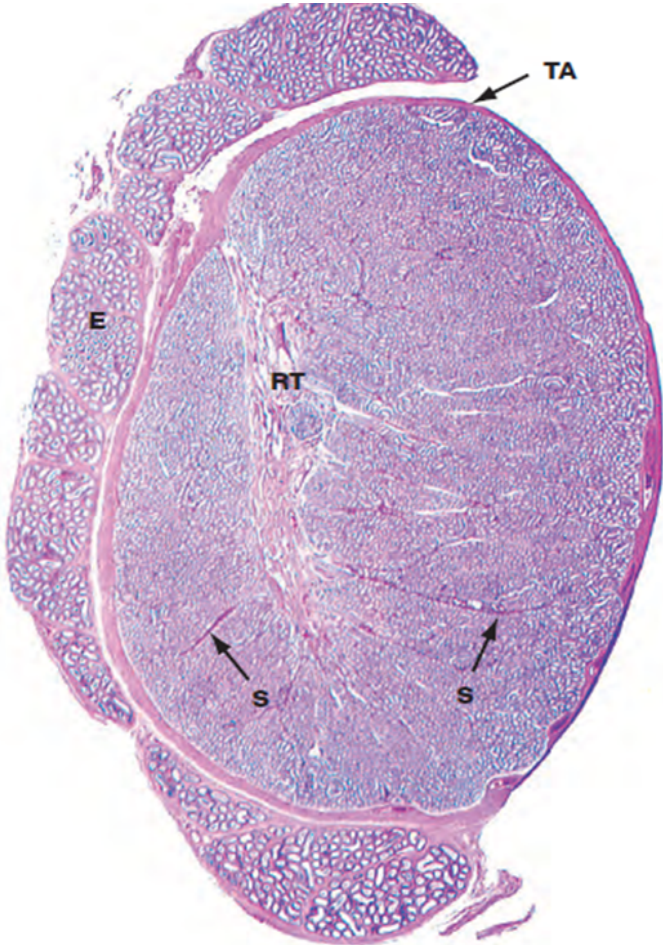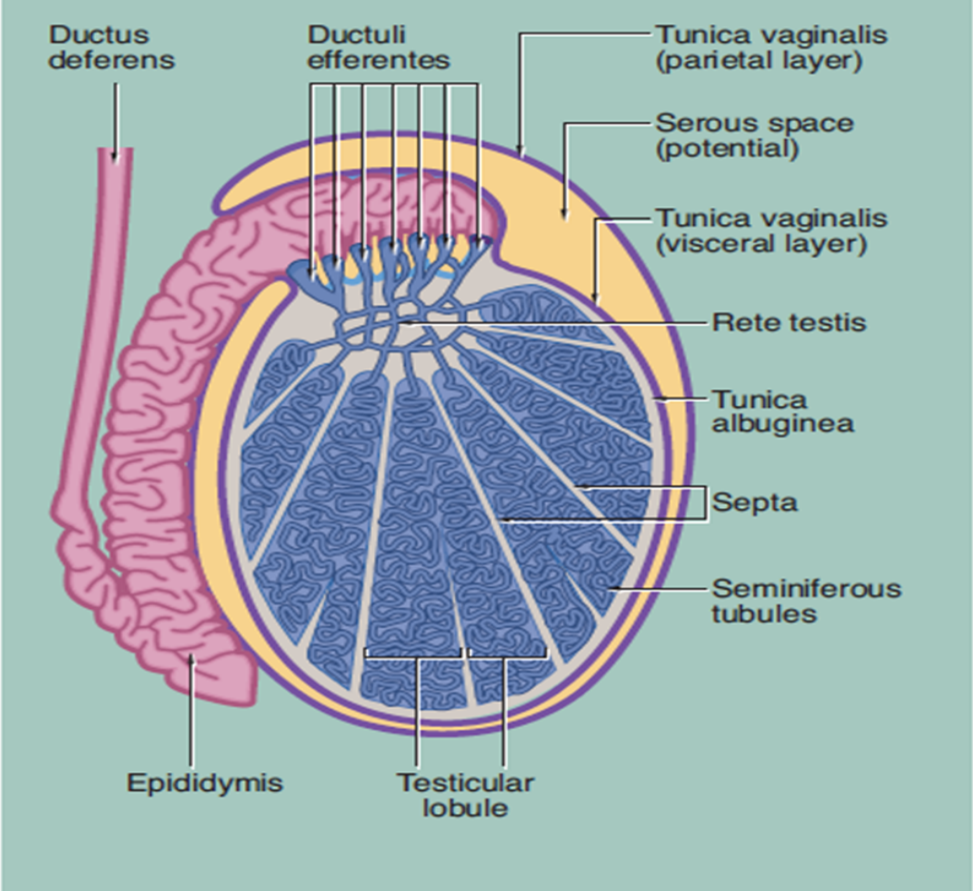
Male reproductive organs



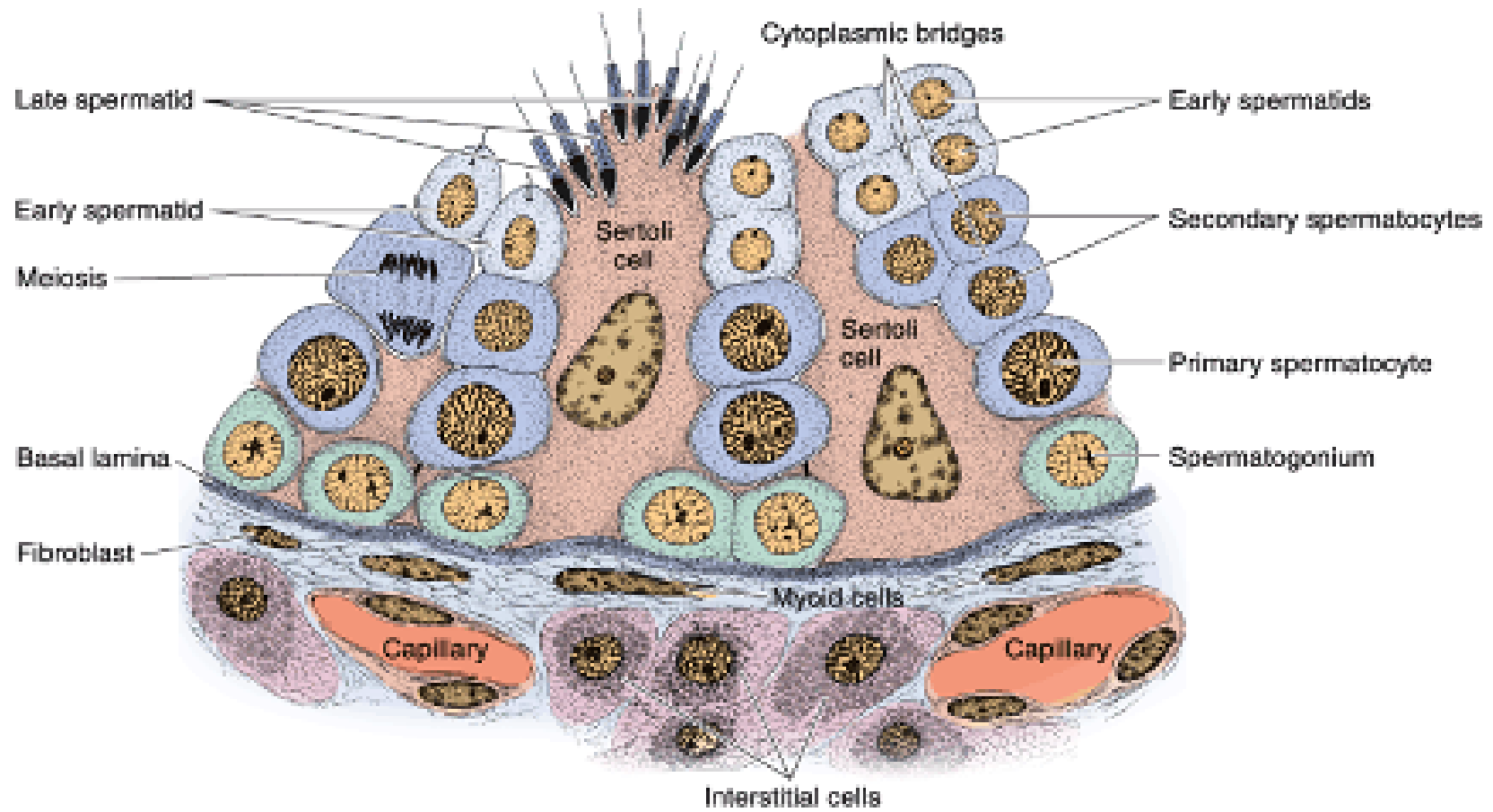
Male reproductive organs



Testis

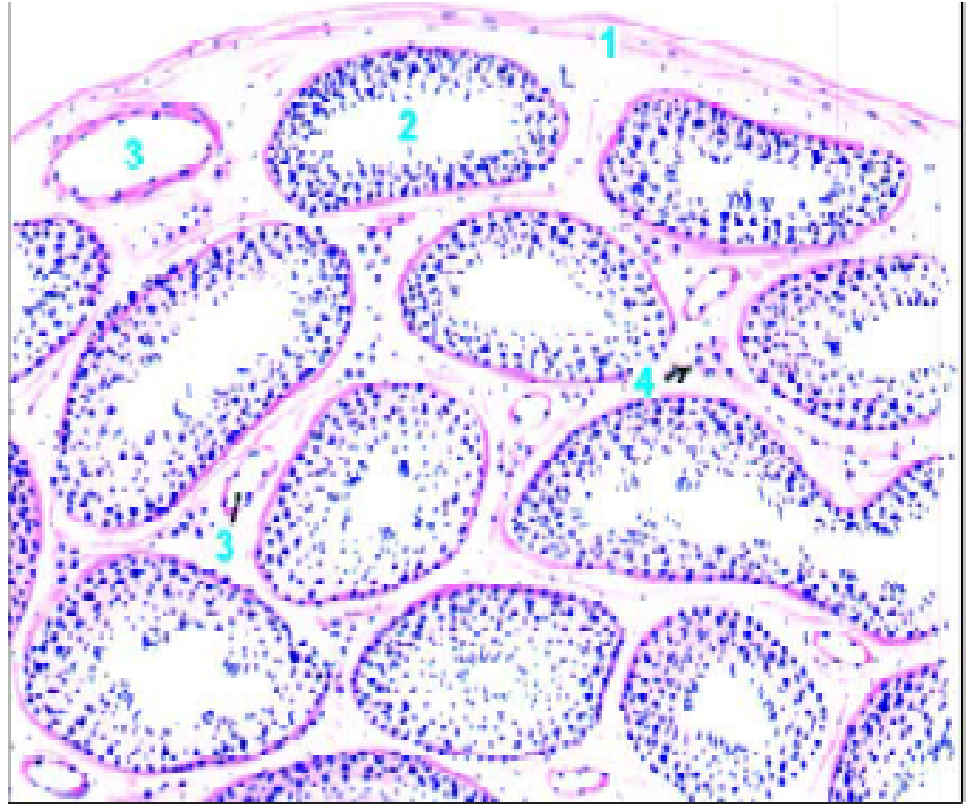


Spermatogenic cells

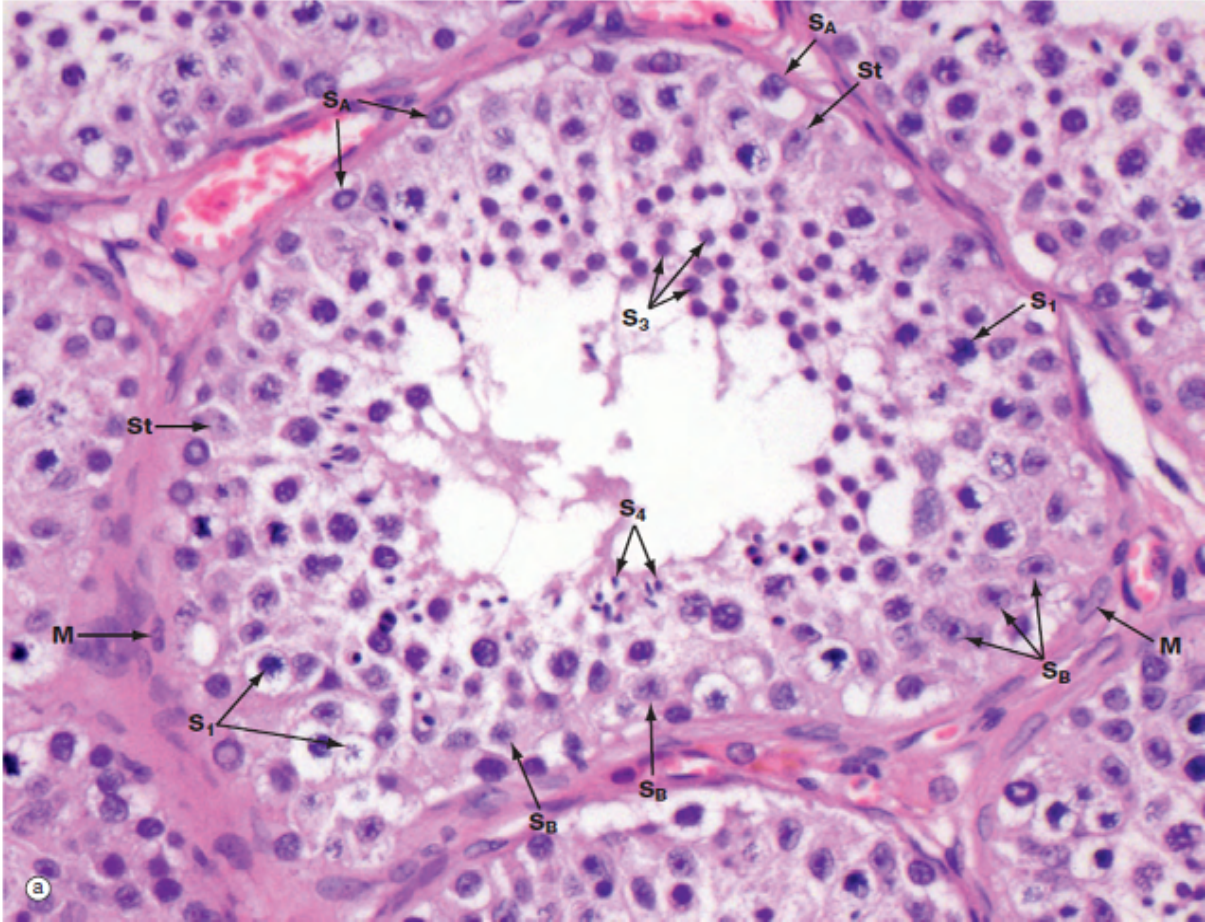


Testis drawing LP.

- 1-Tunica albuginea.
- 2-Seminiferous tubule.
- 3-Blood vessel.
- 4-Interstitial cells (leydig cells – clusters).



Slide H9.411: Testis Human (H&E) HP -



Key for identifying testis

- 1. A large number of seminiferous tubules seen
- 2. Spermatogenic cells and sertoli cells seen
- 3. Presence of leydig cells – in clusters in between seminiferous tubules

Epididymis – 4-5 m Maturation of spermatozoa

Epididymis- comma shaped elongated

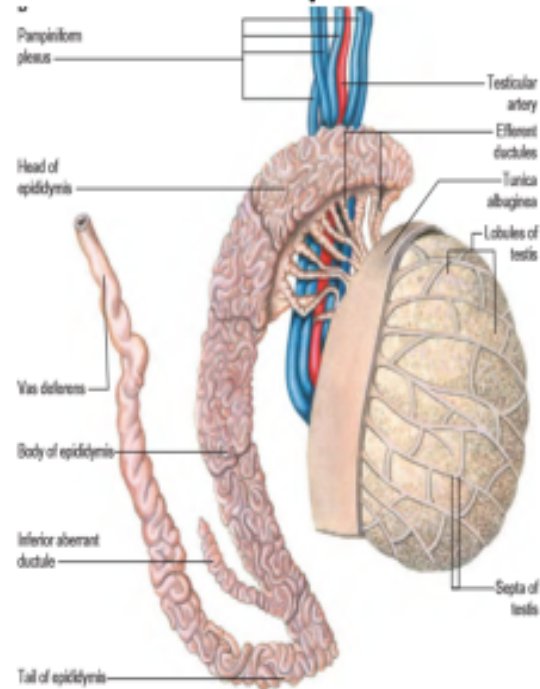
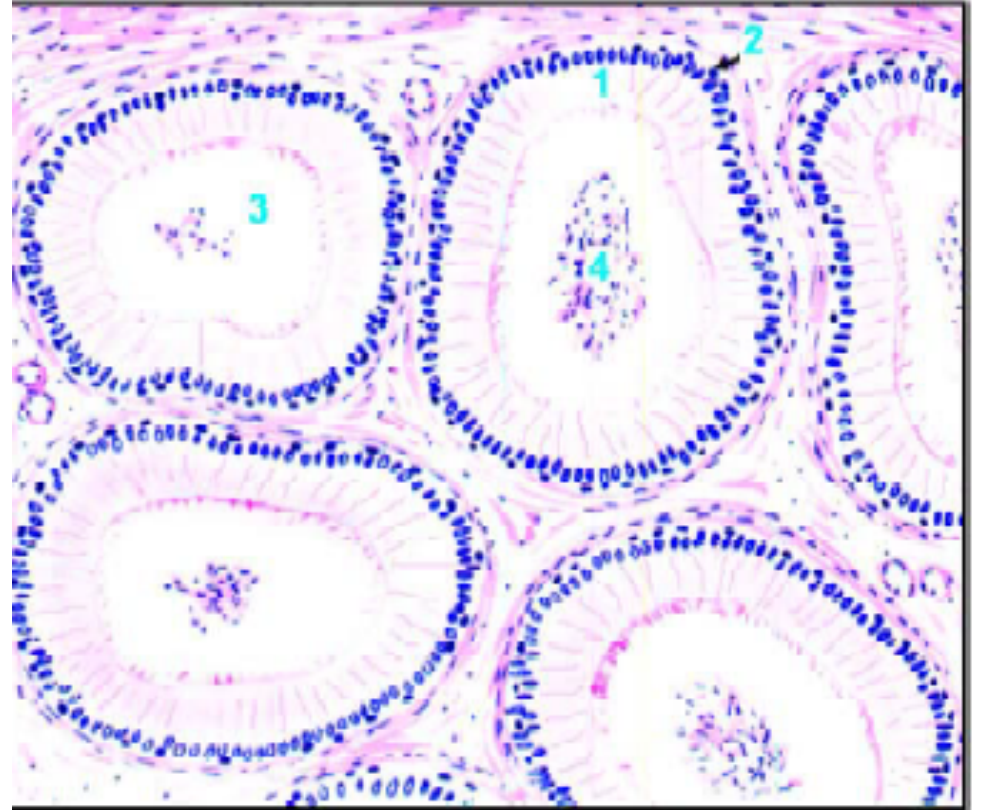
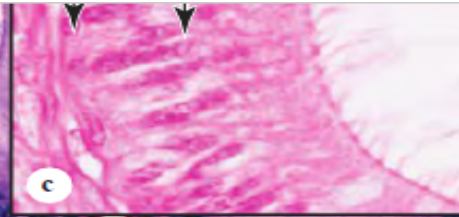
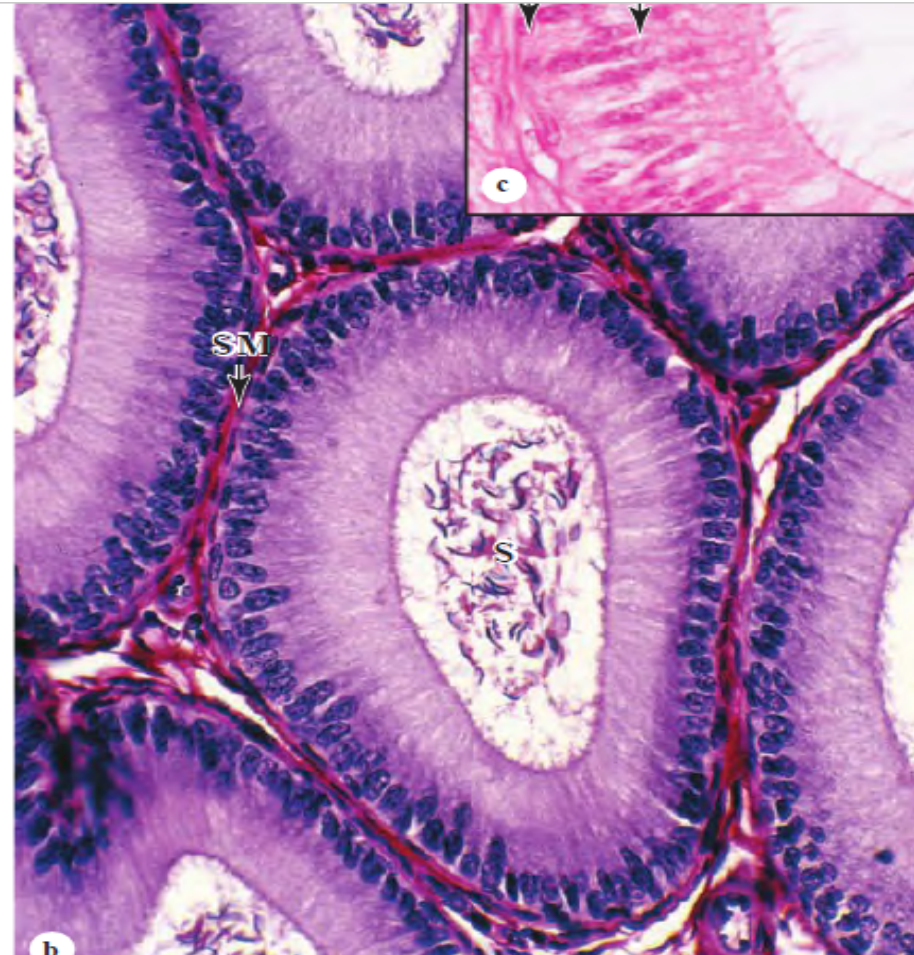
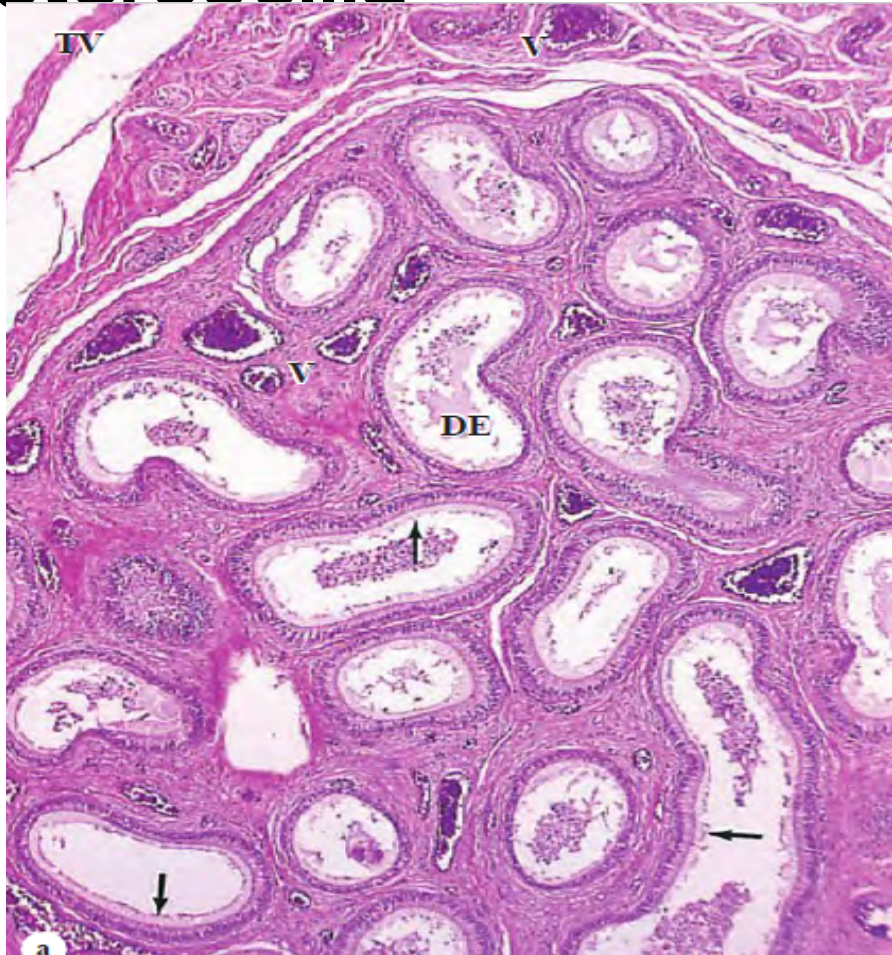

Fig. 18.9. Epidydimis (drawing).

- 1-Lining of tall columnar cells.
- 2-Basal cell.
- 3-Stereocilia.
- 4-Clump of spermatozoa.



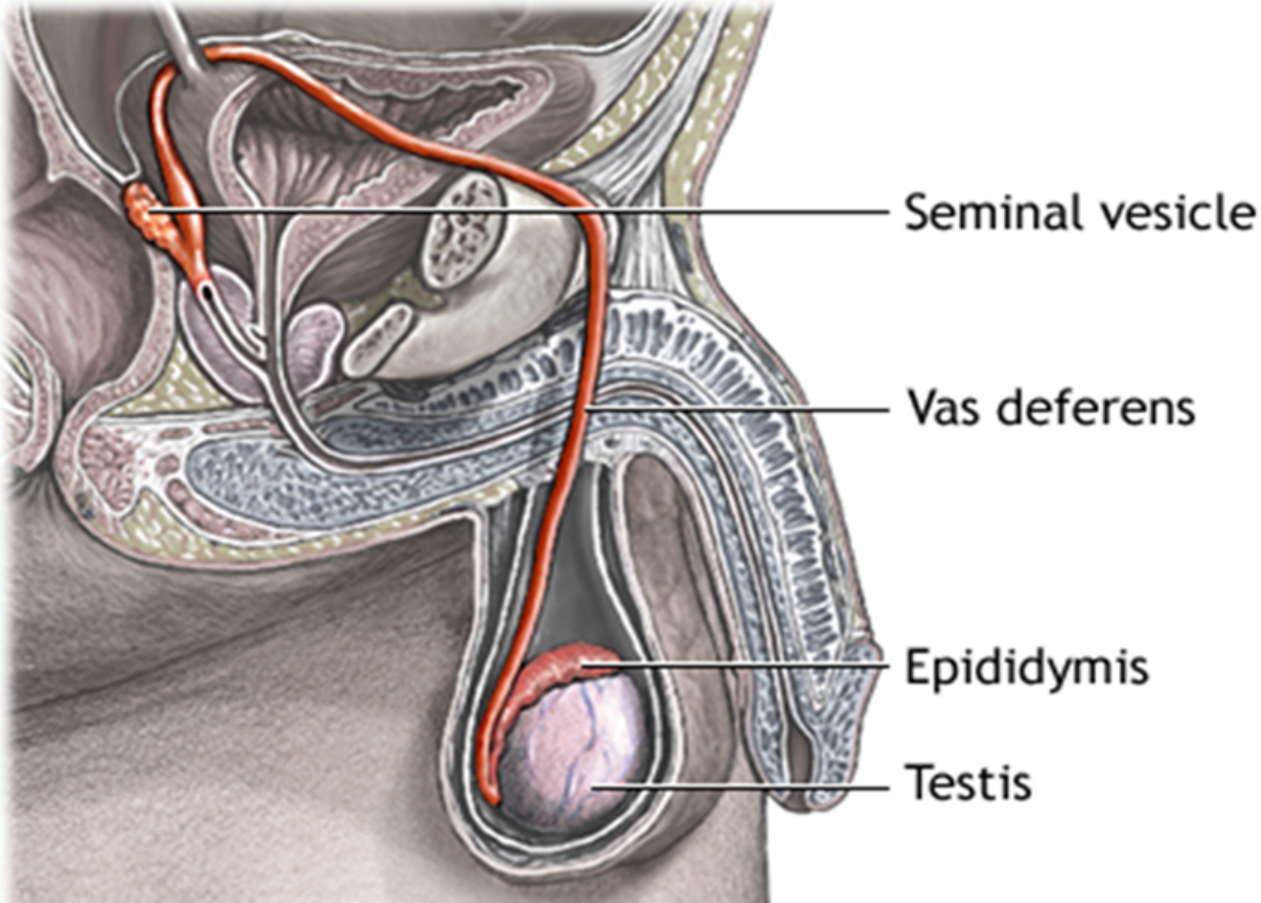
Pseudostratified columnar epithelium - stereocilia



Key for identifying Epididymis

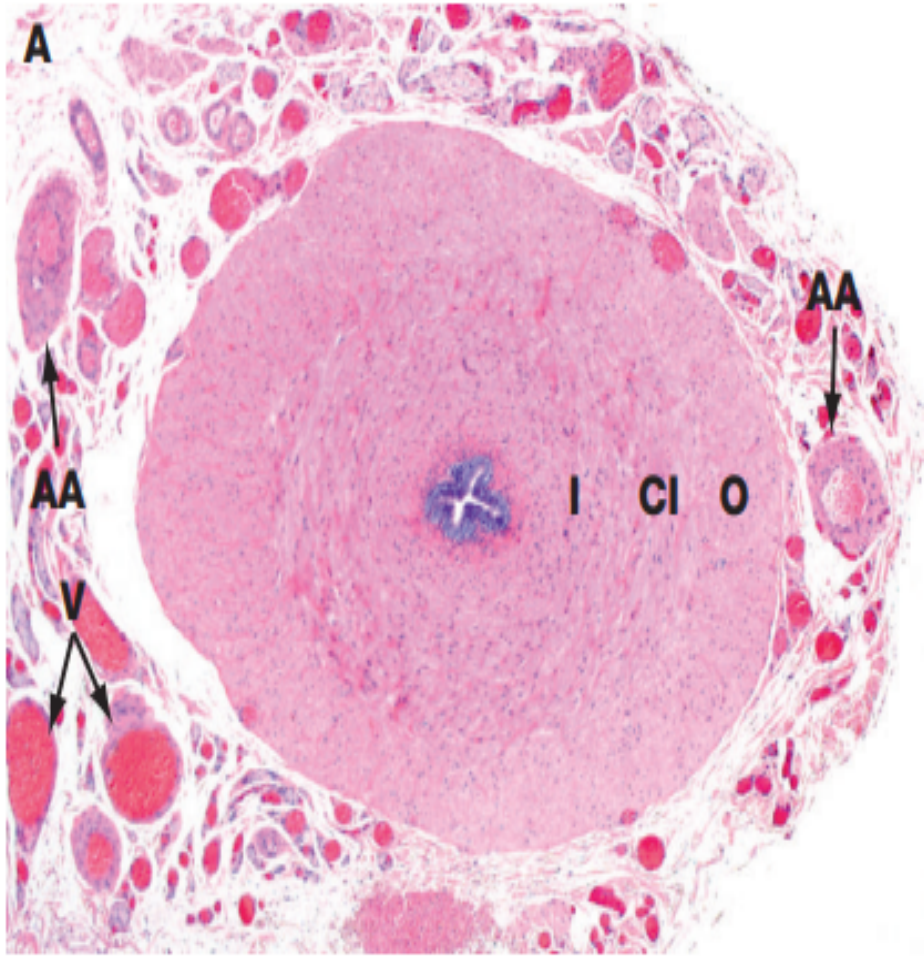
- Tubules lined with stereocilia – Two types of cells seen;
- 1. Columnar with elongated nuclei secretory in nature –nourish sperms in lumen, Stereocilia absorbs testicular fluid, prevent capacitation of sperm in male reproductive system
- 2. Basal cells – with round nucleus close to basement membrane
- In the lumen sperms are seen
- Smooth muscles fibres surround the tubules

Vas deferens – Parts



Histology- mucosa, Lamina Propria, muscularis, & adventitia NB: No Submucosa!

- Narrow lumen and a thick layer of smooth muscle.
- Mucosa is folded longitudinally, lined along most of its length by **pseudostratified columnar epithelium** with **sparse stereocilia**.
- The **lamina propria** is rich in **elastic fibers** and the very **thick muscularis** consists of **longitudinal inner and outer layers** and a **middle circular layer**.
- The muscles produce strong peristaltic contractions during ejaculation which rapidly move sperm along this duct from the epididymis.



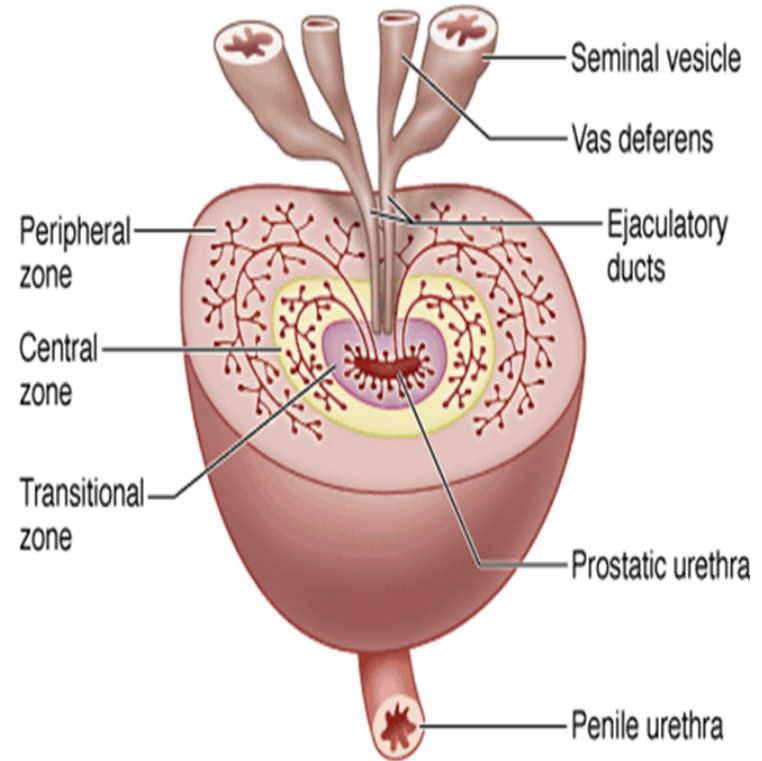
- The *vas* (or *ductus*) *deferens*, which conducts spermatozoa from the epididymis to the urethra, is a thick-walled muscular tube consisting of inner **I** and outer **O** longitudinal layers and a thick intermediate circular layer **CI**.

Slide H9. 431 Vas deferens Human H&E

- Lined by a pseudostratified columnar epithelium similar to that of the epididymis;
- Epithelial lining and its supporting lamina propria are thrown into longitudinal folds permitting expansion of the duct during ejaculation.
- **Key for identifying Vas deferens**
- **1. Pseudostratified columnar epithelium with sparse stereocilia.**
- 2. Thick muscle coat
- 3. Stellate lumen – Small and irregular lumen

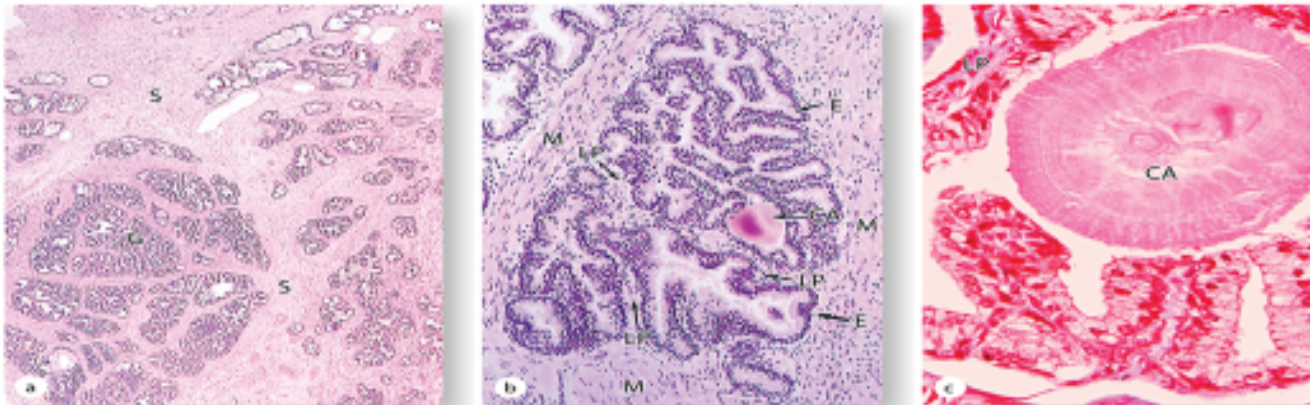
Prostate Gland

- Anatomically; glandular tissue subdivided into three distinct zones:
- Peripheral (70% by volume)
- Central (25% by volume)
- Transitional (5% by volume)
- Non-glandular tissue (fibromuscular stroma) fills up space between peripheral zones anterior to the preprostatic urethra

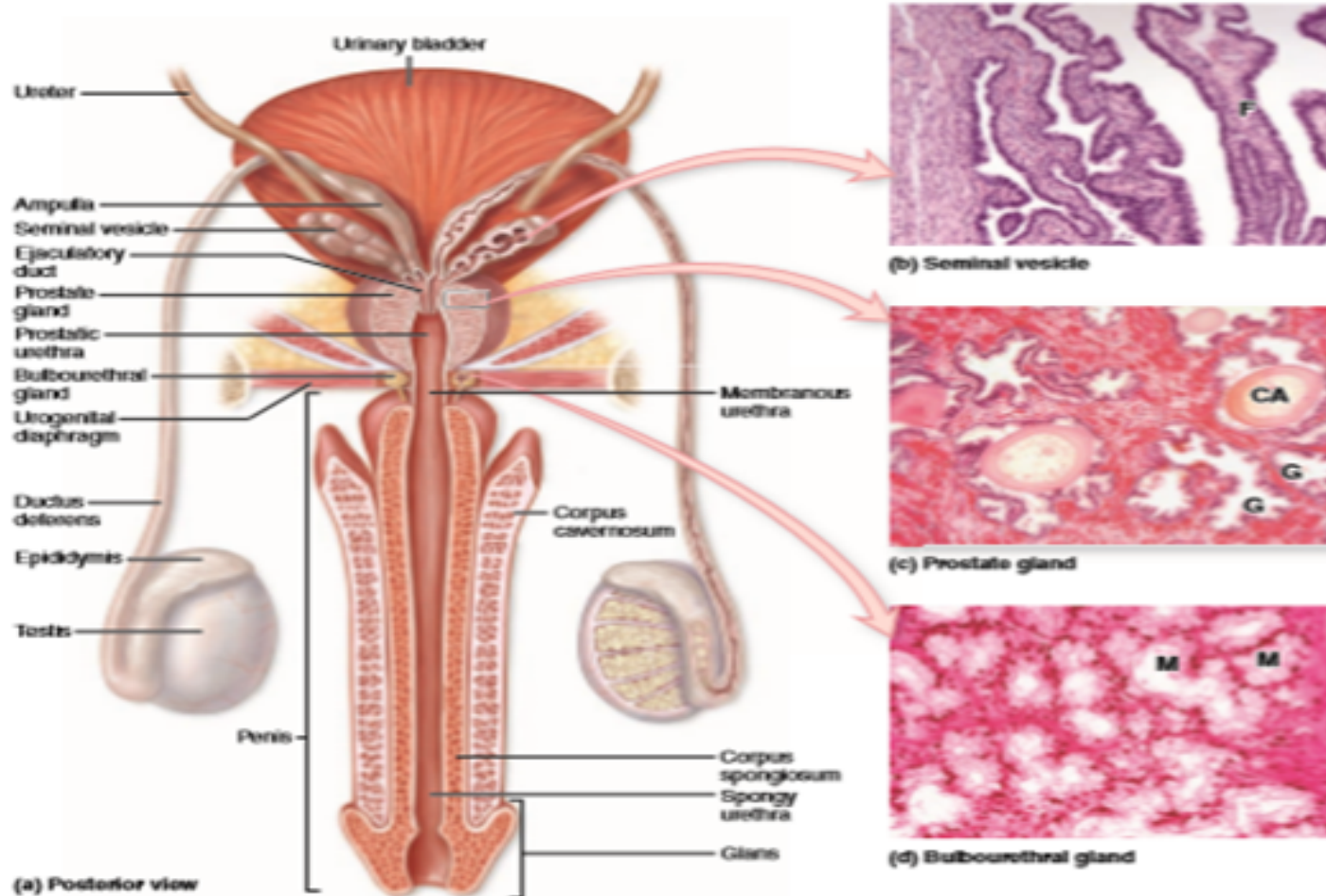


Slide 81: Prostate gland (Mallory- Azan)

Prostate gland - Histology



Prostate gland

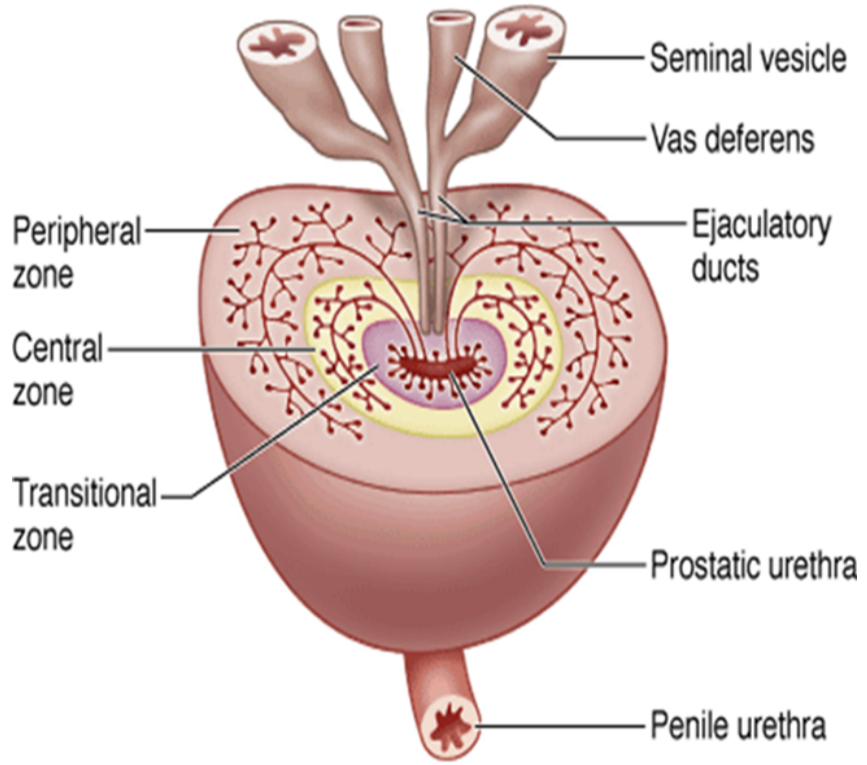


Key for identifying Prostate gland

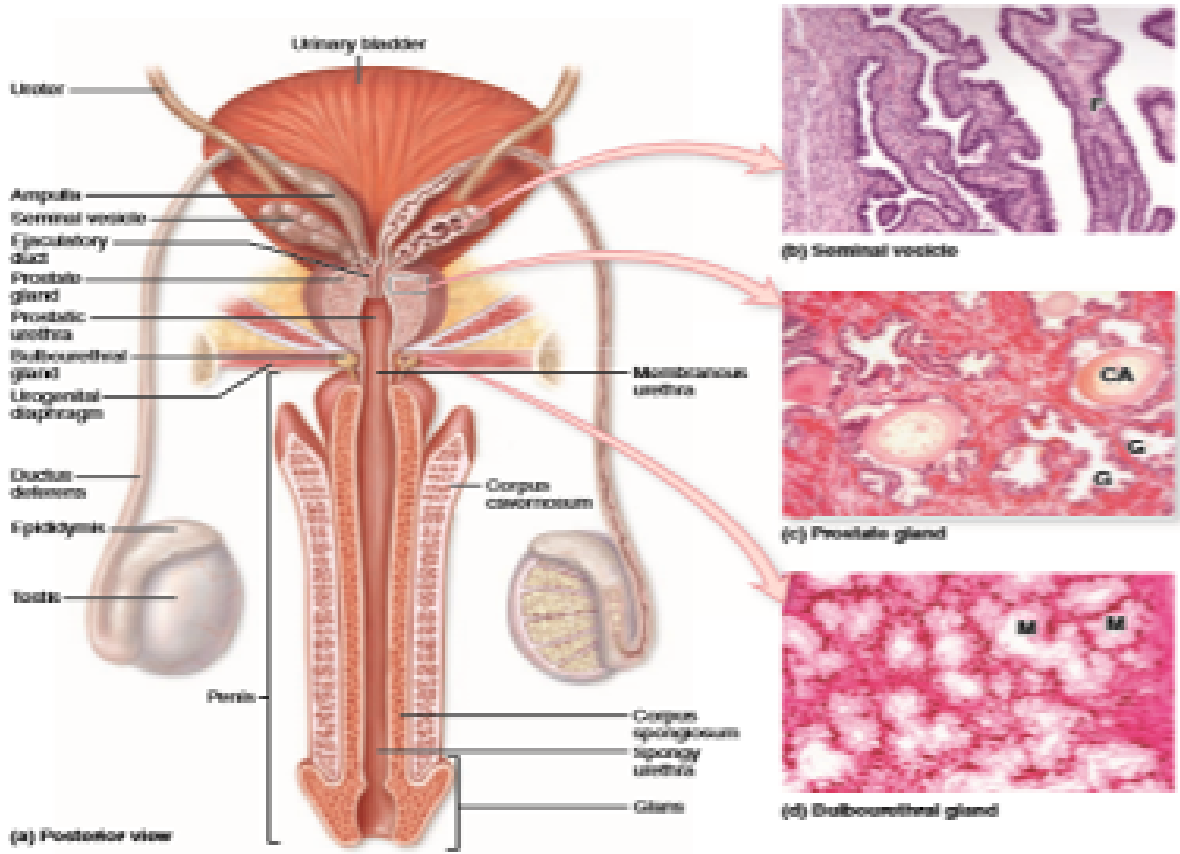
- 1. Irregular acini with epithelium folded inwards seen
- 2. Stroma is of fibromuscular
- 3. Acini are filled with corpora amylacea

Slide H9. 422: Seminal vesicle (H&E)-Tightly closed tube, many recesses seen - honey comb.

- Complex glandular dicerticulum of ductus deferens. Secretes up to 85% of seminal fluids into ductus deferens – an alkaline fluid – neutralizes acid in the vagina, fructose provides energy for sperm, prostaglandins increase sperm viability & stimulate female uterine contraction – help sperm move into uterus.



Slide H9. 422 Seminal vesicle (H&E)



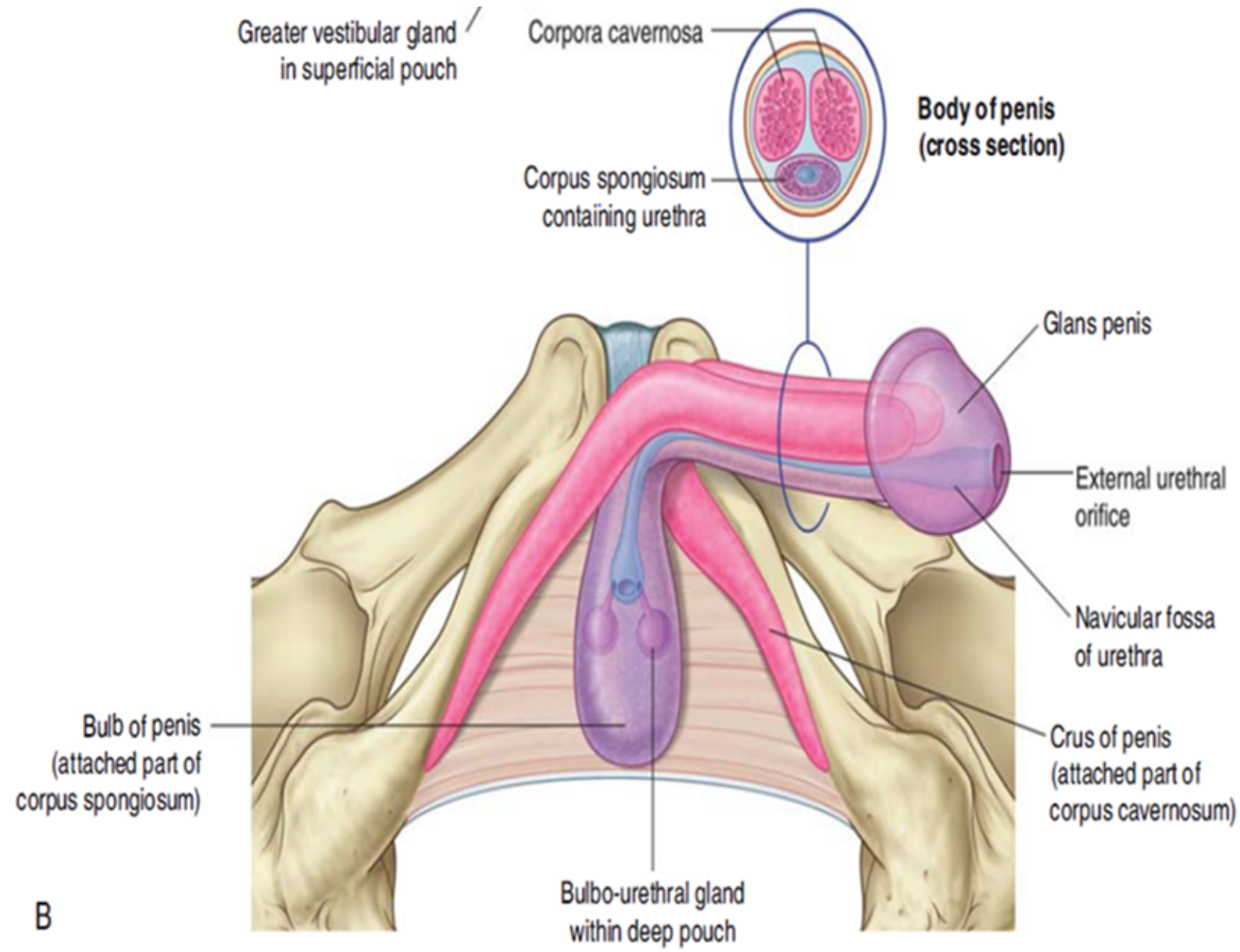
Key for identifying Seminal vesicle slide

- 1. Mucosa is highly branched having anastomosing folds
- 2. No sperm in the lumen
- 3. Well developed muscle layer

Penis

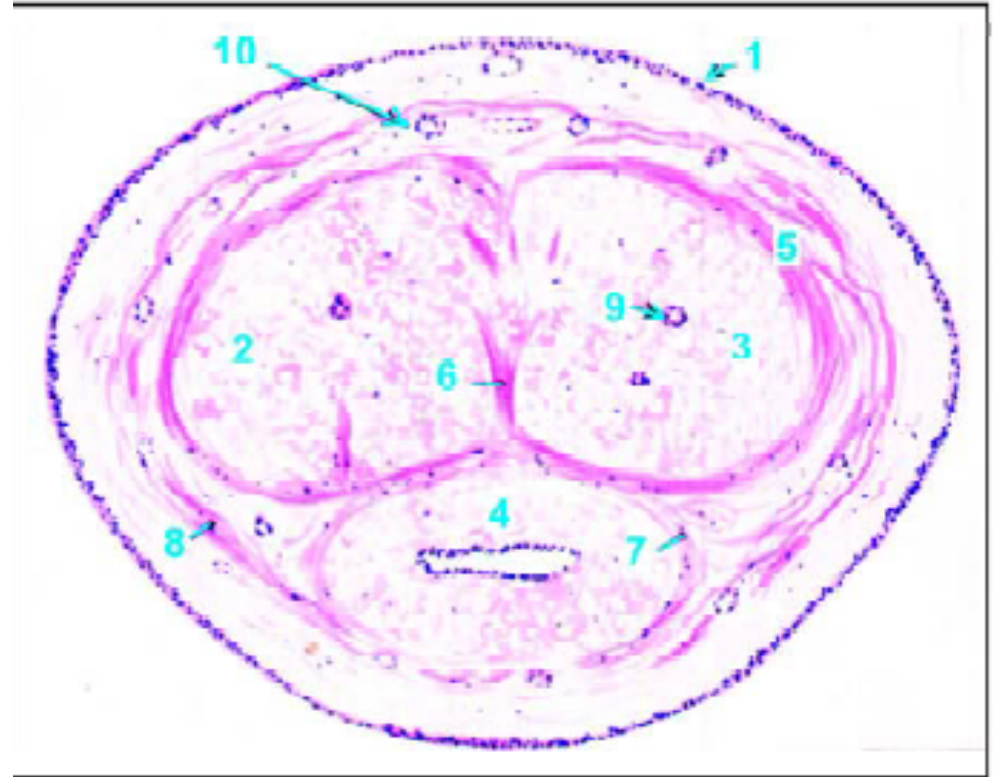
- Attached root (radix) in the perineum and a free pendulous body (corpus) which is completely enveloped in skin.

Slide 84: Penis Monkey (H & E)

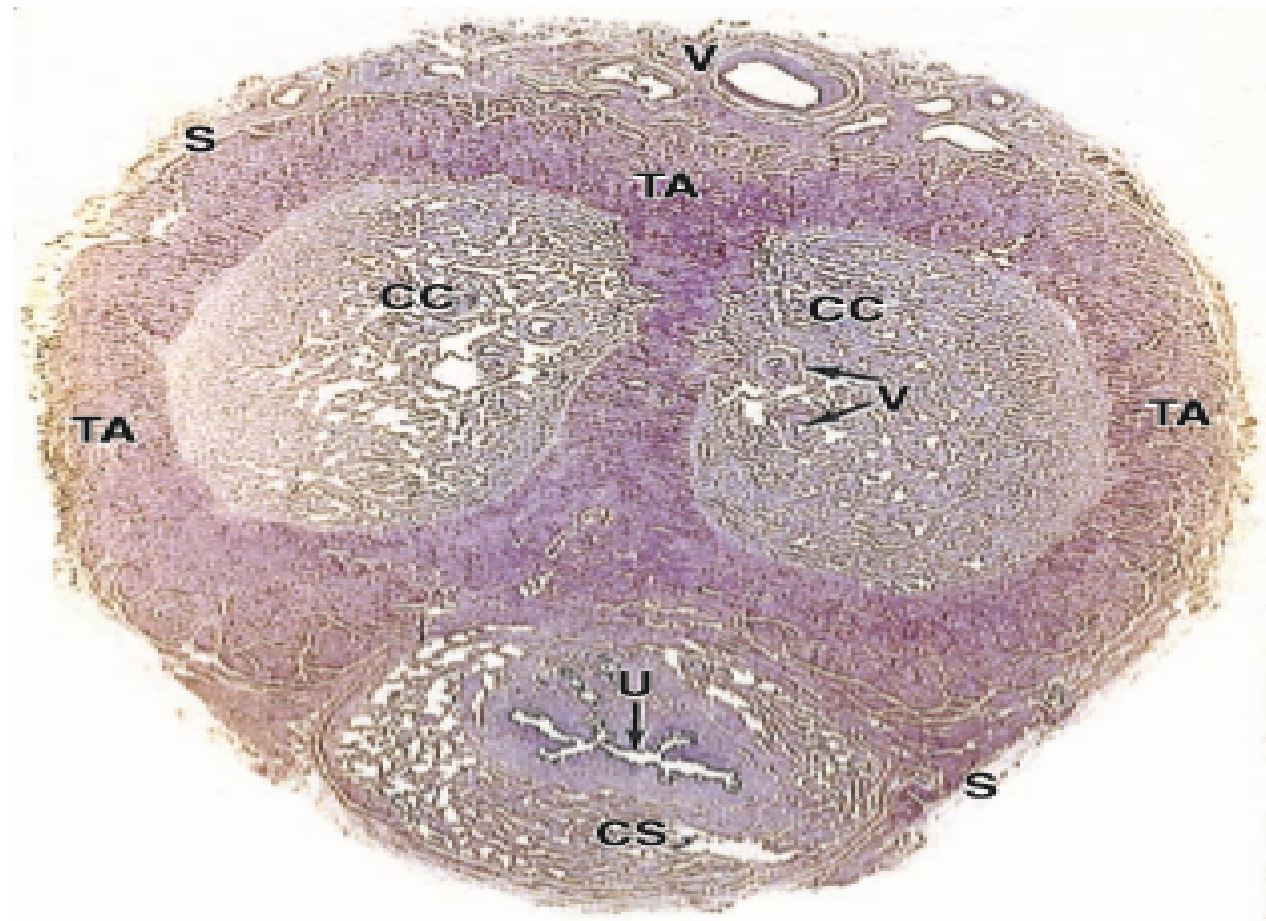


Penis

- 1-Skin.
- 2, 3, 5-Corpora cavernosa and sheaths for them.
- 6-Median septum.
- 4,7-Corpus spongiosum and its sheath.
- 8-Common sheath.
- 10-Dorsal artery.



Penis - Slide

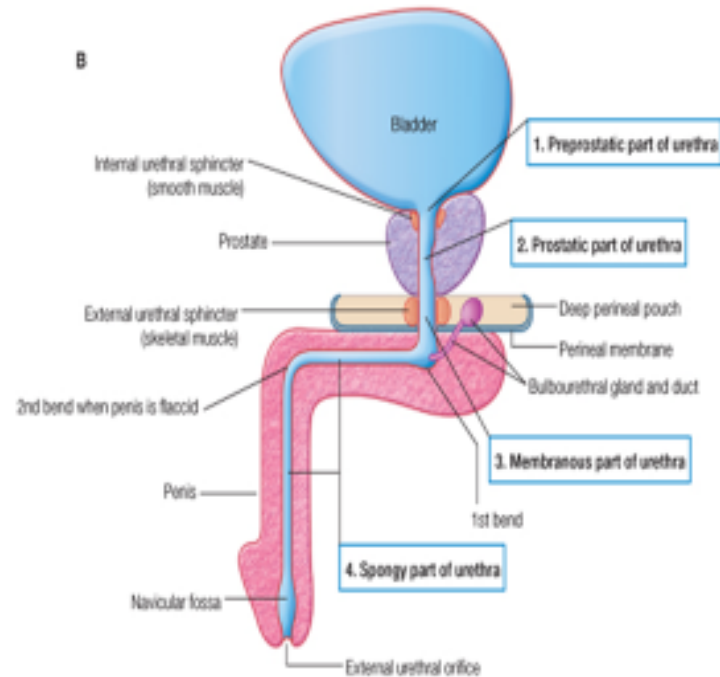


Key for identifying Penis

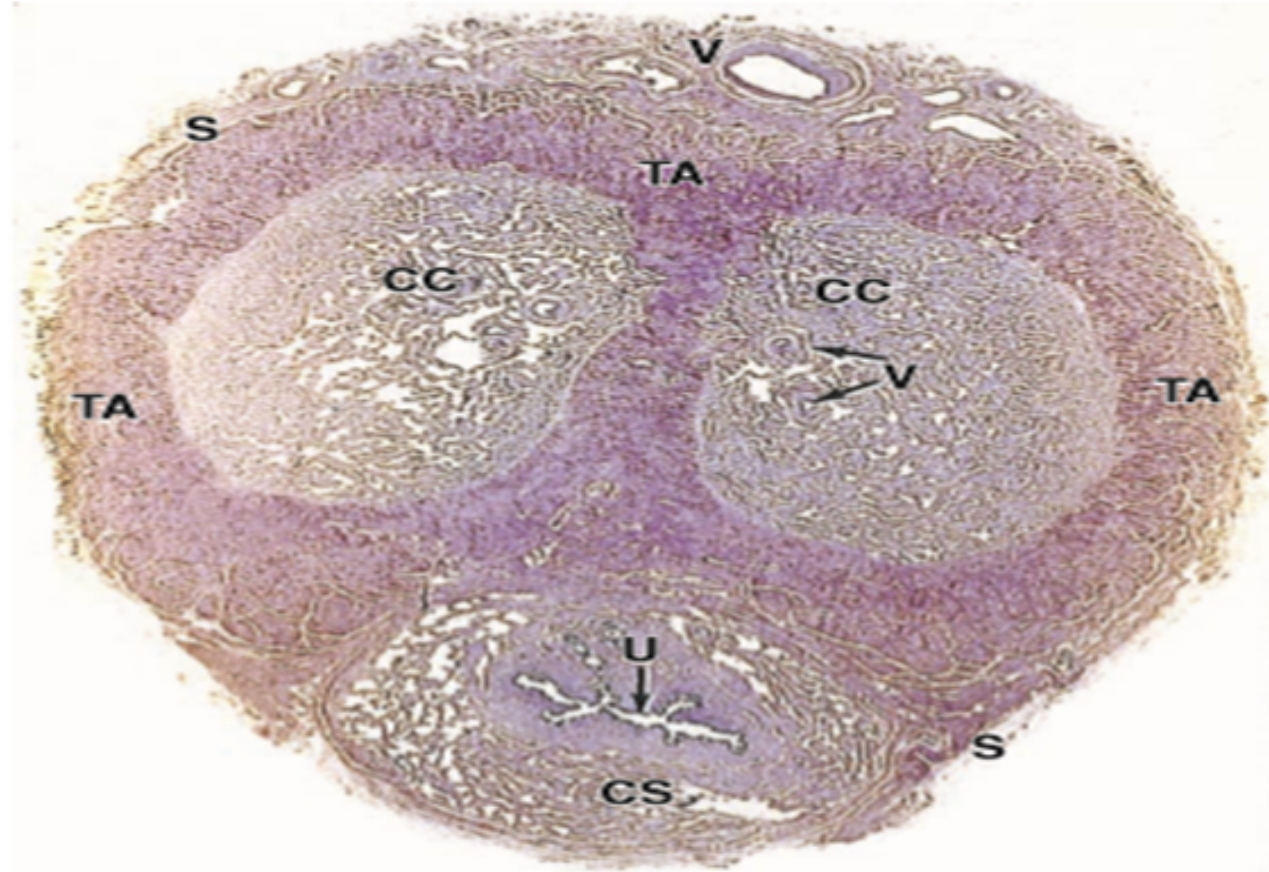
- 1. Two dorsal corpora cavernosa traversed by a deep artery of the penis covered by tunica albuginea.
- 2. A ventral corpus spongiosum traversed by penile urethra seen
- 3. Outer covering of skin seen.

Slide X: Male urethra (Ihab)

Anterior urethra



Male urethra



Key for identifying a male urethra

- 1. Mucosa lined by transitional or pseudo columnar epithelium
- 2. Lumen is irregular
- 3. Irregular venous spaces surround the lumen.

References

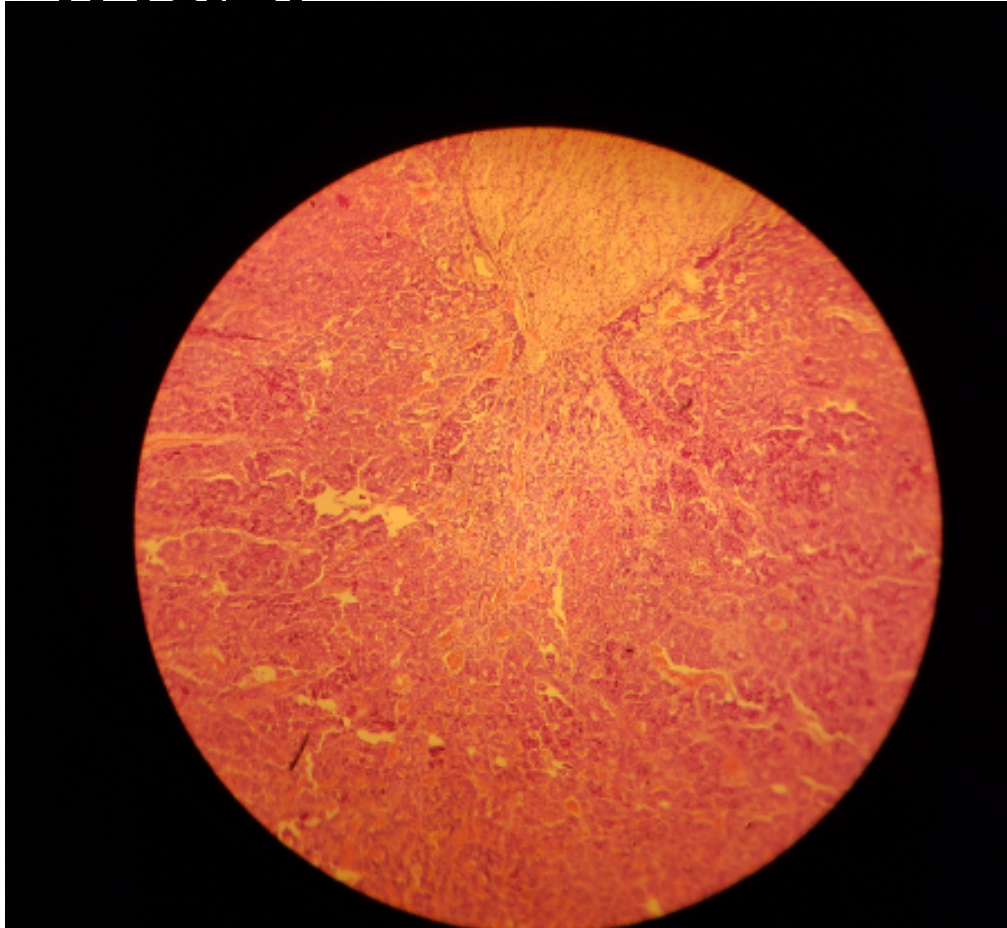
- Junqueira's Basic Histology Text
- Wheaters' Functional Histology A text and Colour Atlas.

ENDOCRINE SYSTEM

LAB 22

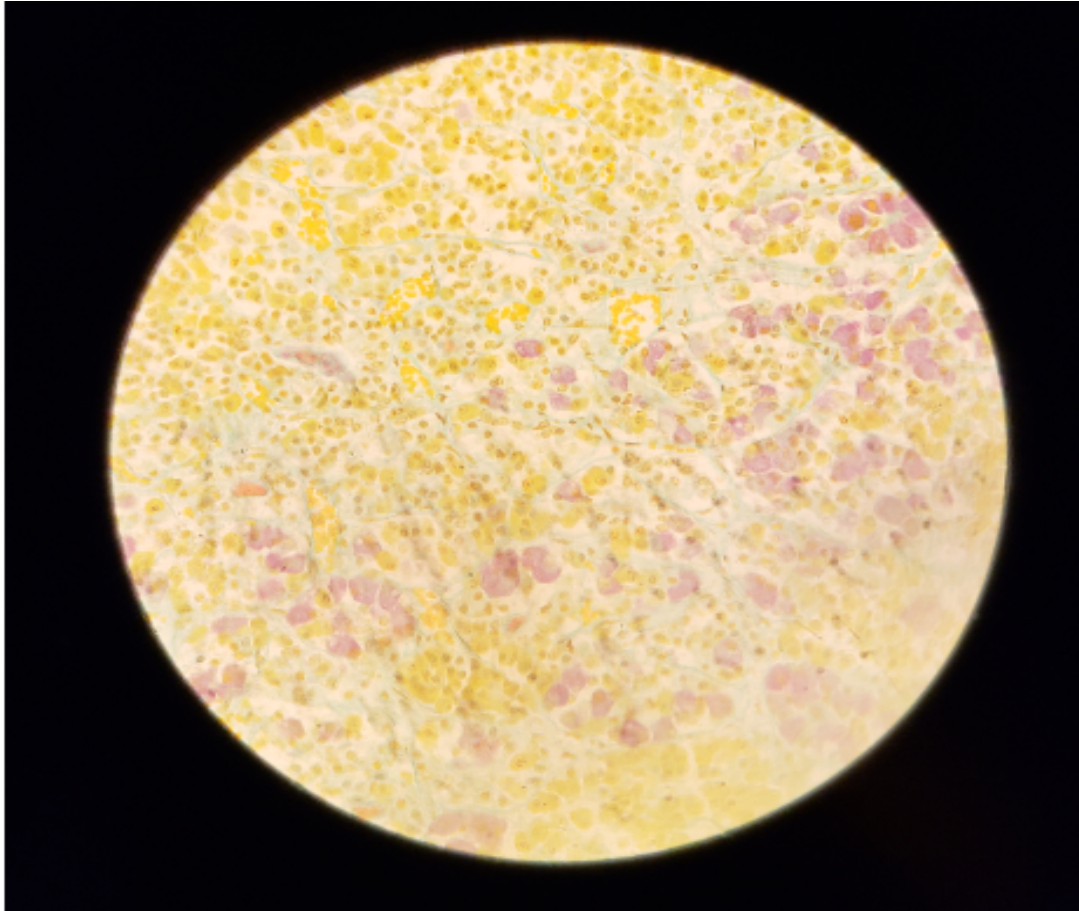
MR Richwell HAKACHA

SLIDE H14.31 HYPOPHYSIS,HUMAN (H&E)



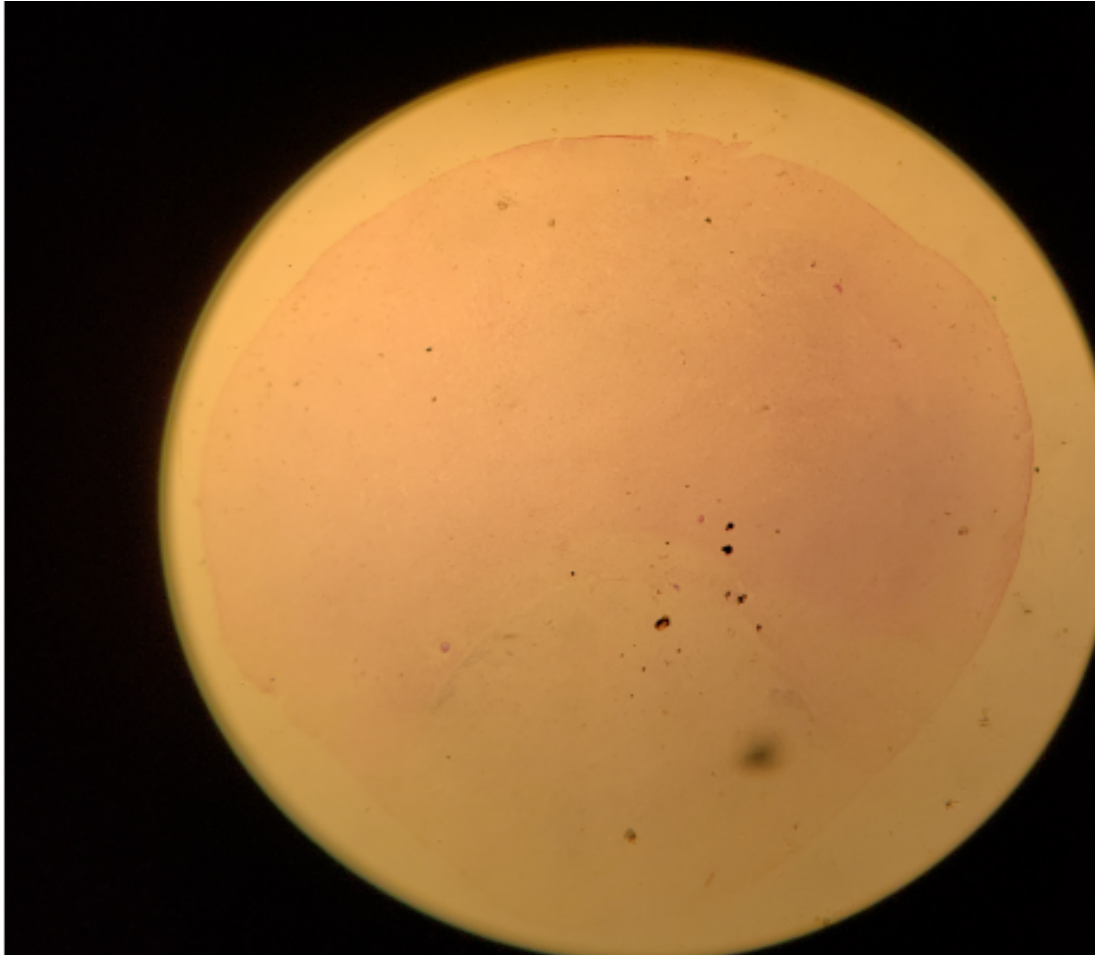
- Pars distalis (dark)
- Pars nervosa (Light)
- Numerous blood sinusoids

SLIDERS



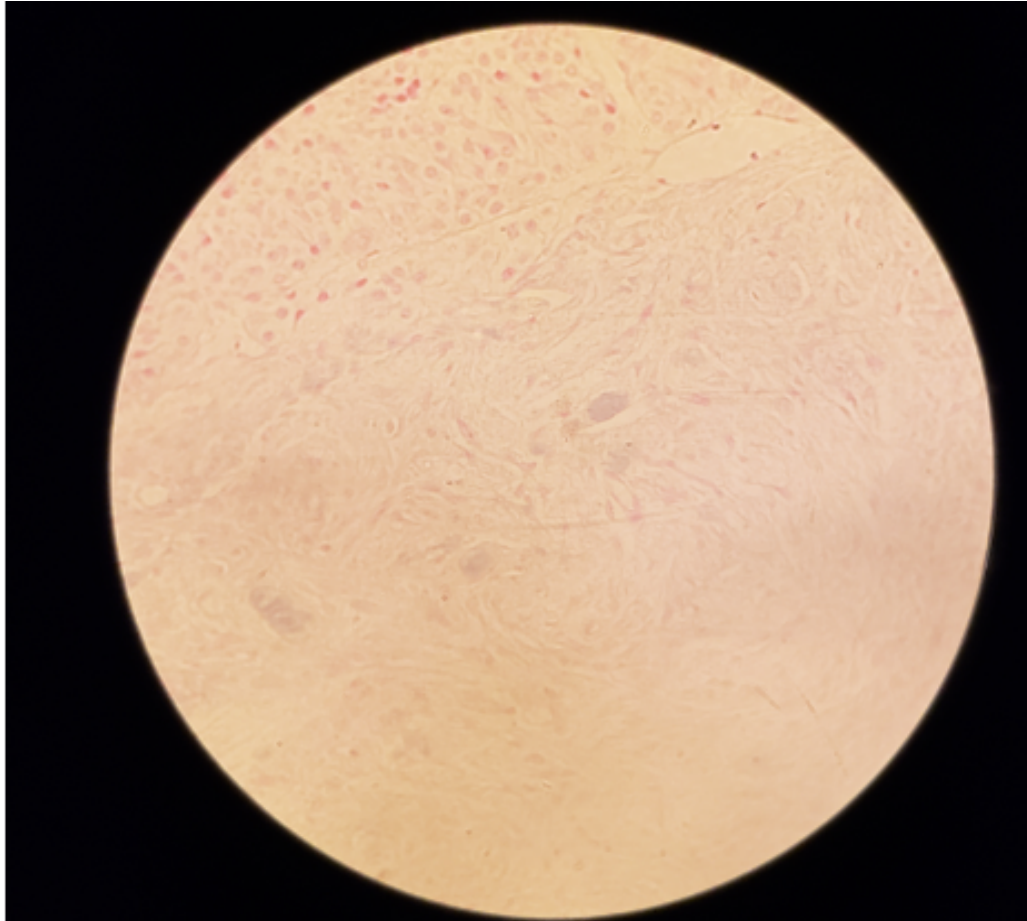
- Acidophil stain **yellowish** cyto granules
- Basophils **brownish** or **bluish** indifferent looking cells
- RBCs **orange**
- Collagen **greenish**

SLIDE 104 HYPOPHYSIS RABBIT(GOMORI~S CHROME ALUM HAEMATOXYLIN



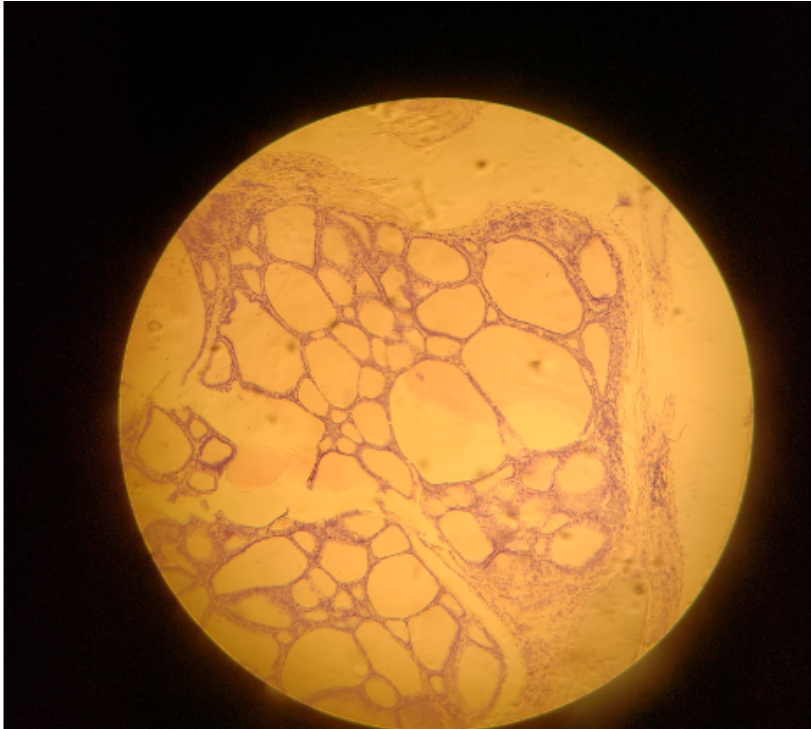
- Three lobes of hypophysis are clearly visible
- Note Pars intermedias close relationship with pars nervosa

HP PARS NERVOSA



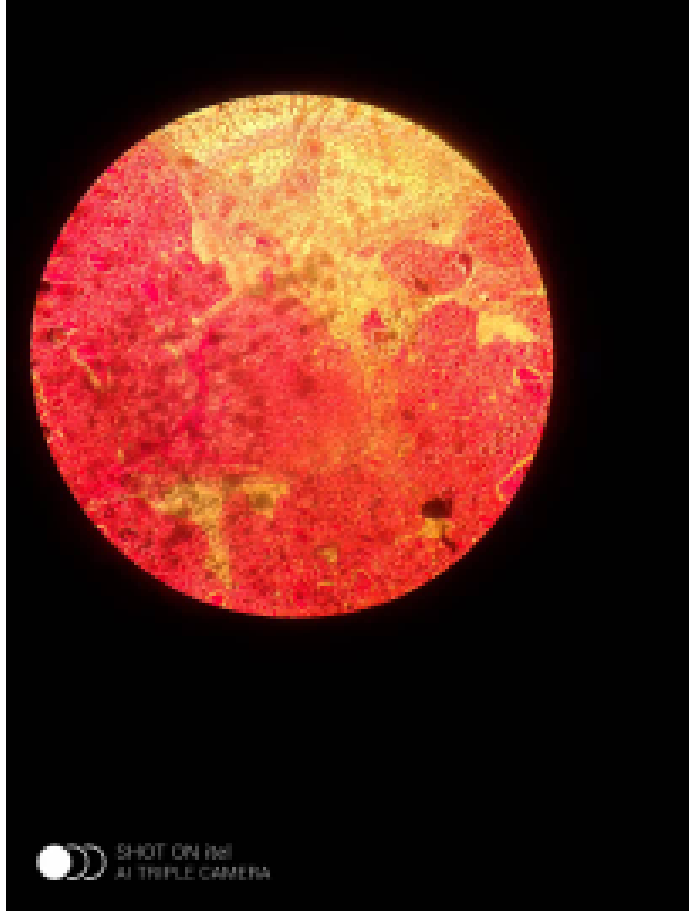
- Contain **nerve fibres**
- Glial cells (Pituicytes) only
- **Herring bodies**(neurosecretory products) may be recognised as accumulations of **dark blue granules**

SLIDE H14.11 THYROID GLAND HUMAN H&E



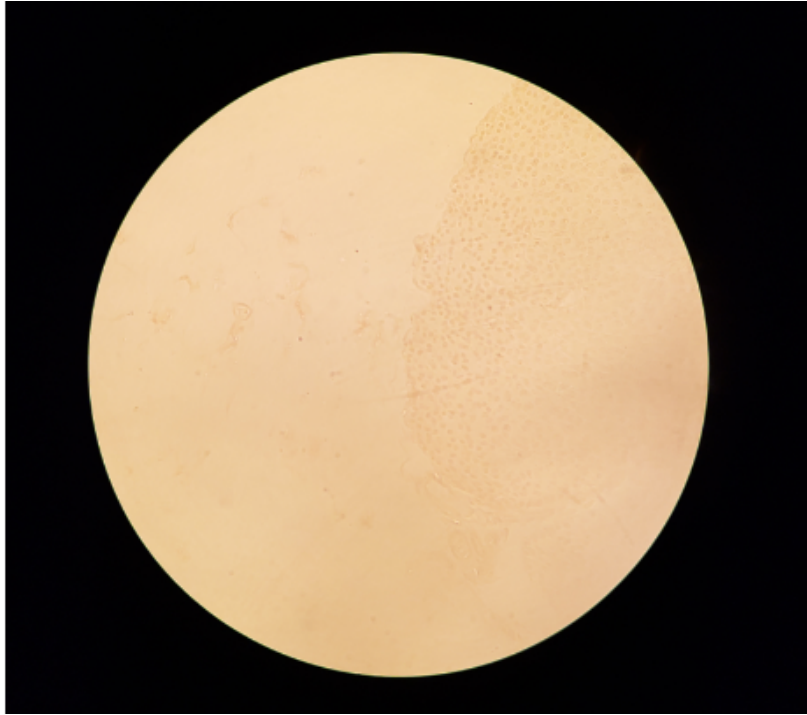
- Study gen pat of follicles
- Lined by low cuboidal epith
- Contain homogenous colloid material
- Interstitial tissues and capillaries

SLIDE 109 THYROID AND PARATHYROID, KITTEN(H&E)



- Locate small island of parathyroid gland
- Parafollicular © cells

SLIDE 14.16 PARATHYROID GLAND HUMAN(H&E)

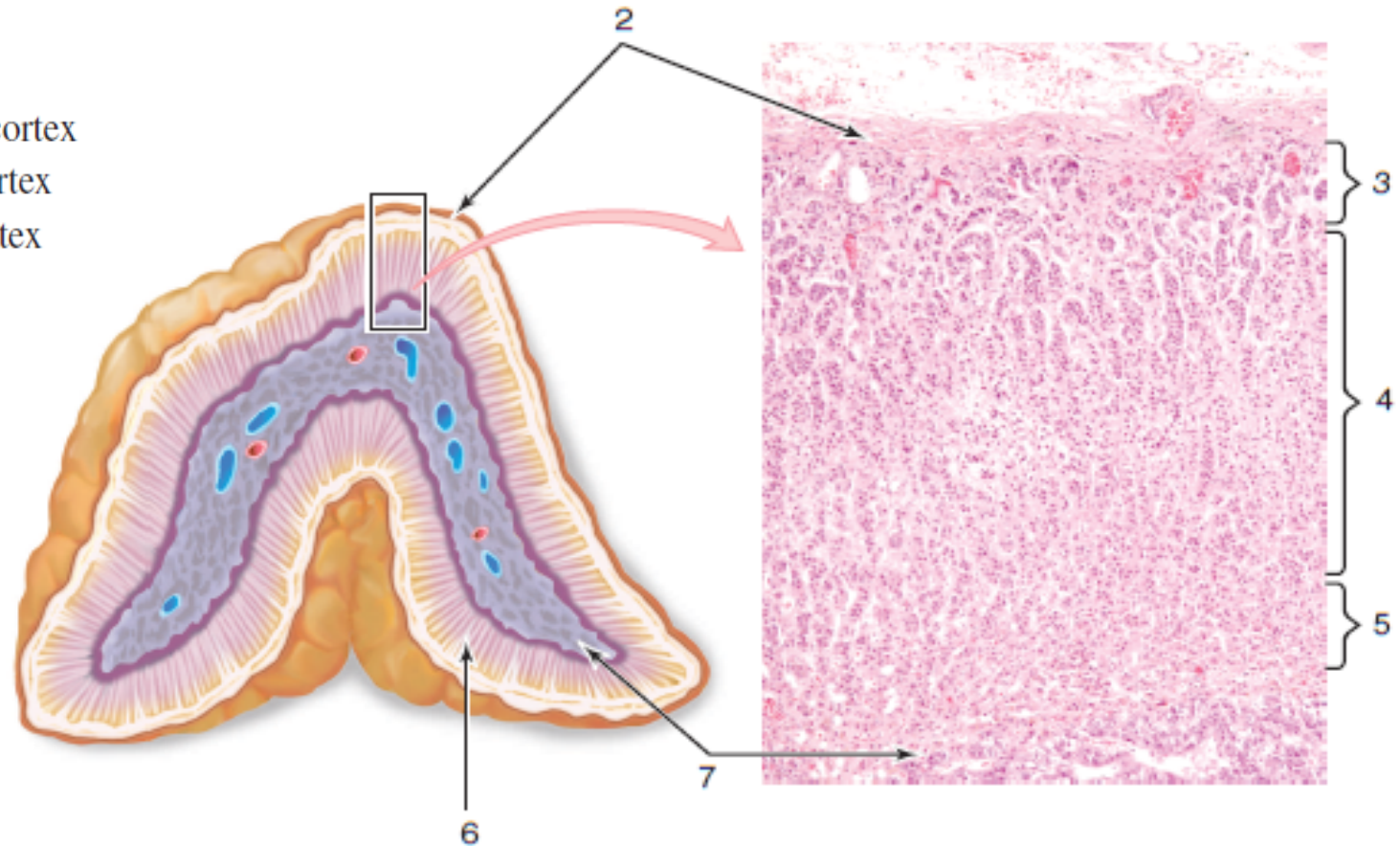


- Thin CT capsule but no lobules
- Parenchyma with closely packed chief(principle) cells
- NO Oxyphil(eosinophil) cells which appear after puberty

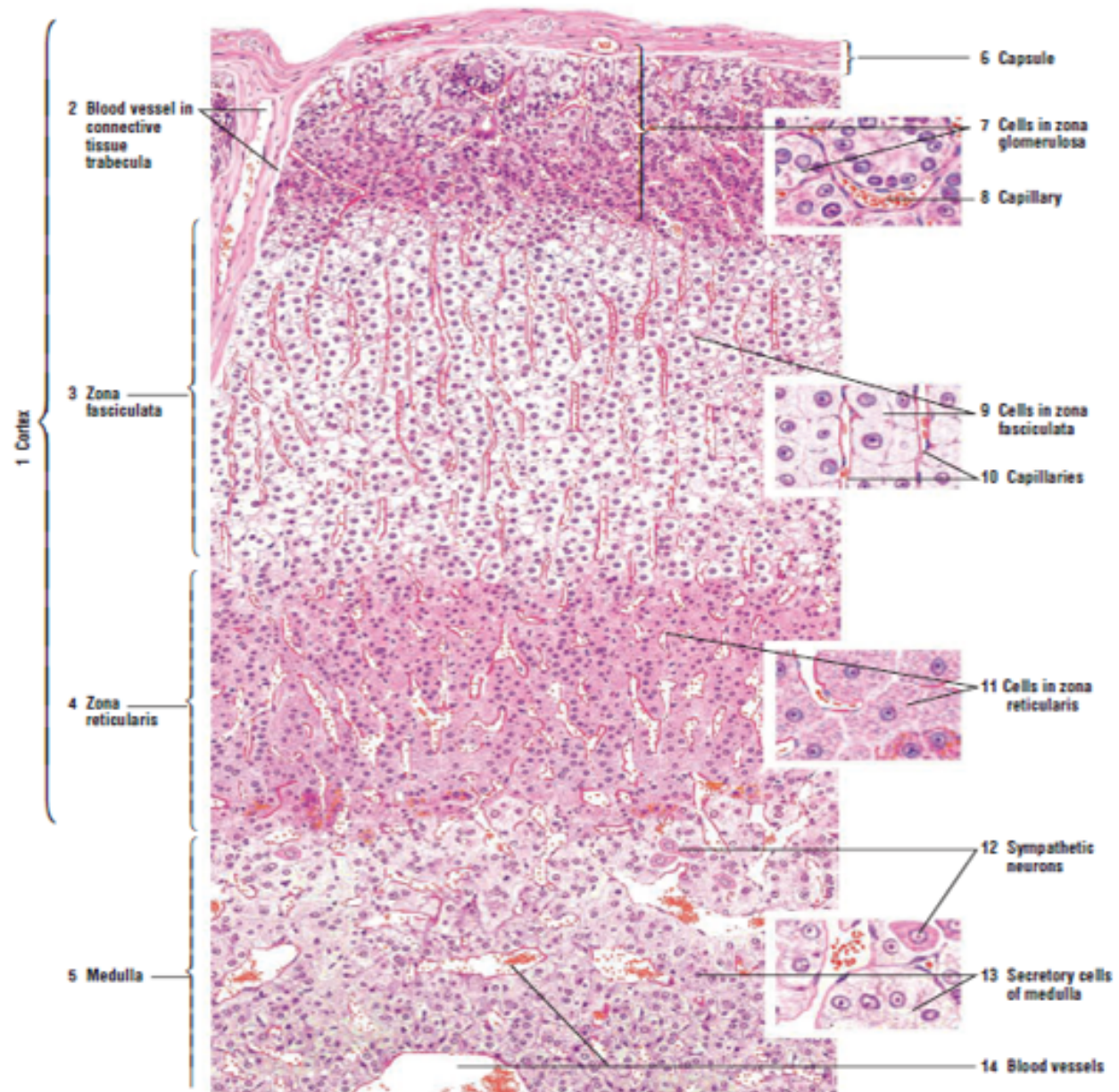


SUPRARENAL GLAND

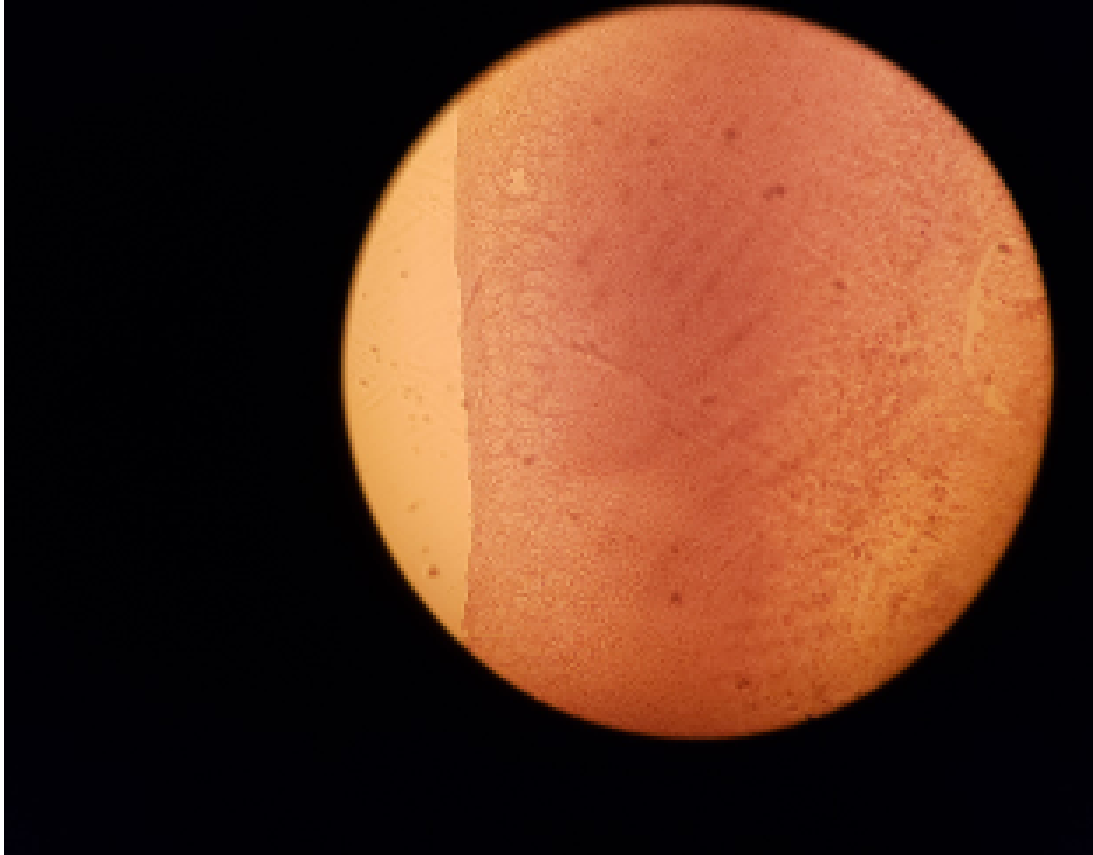
1. Adrenal gland
2. Capsule
3. Zona glomerulosa of adrenal cortex
4. Zona fasciculata of adrenal cortex
5. Zona reticularis of adrenal cortex
6. Adrenal cortex
7. Adrenal medulla



CONT'D

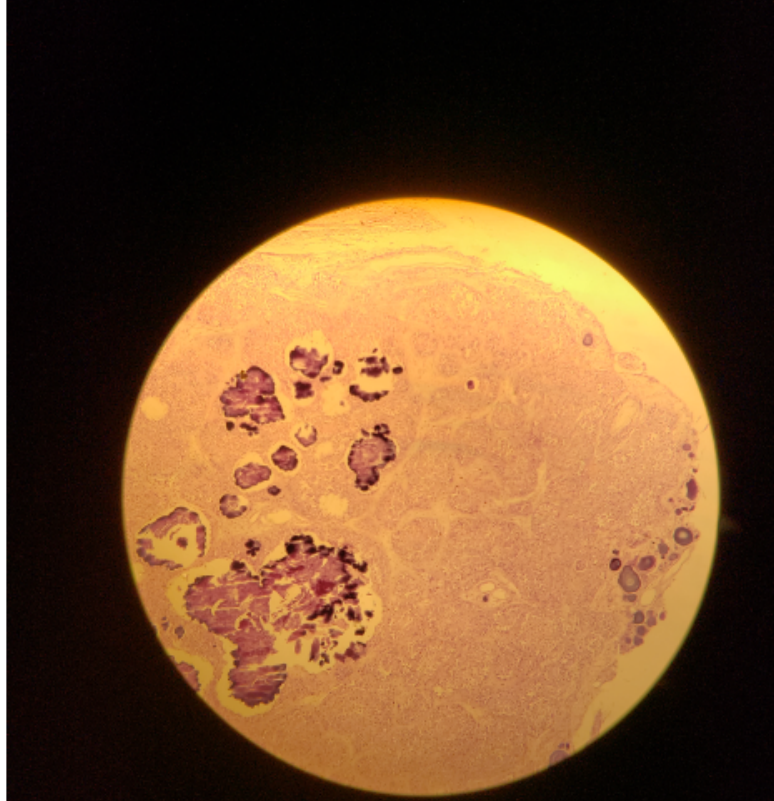


SLIDE 106 SUPRARENAL GLAND (H&E)



- Capsule, Cortex, Medula
- Zona glomerulosa,
- Zona Fasciculata,
- Zona Reticularis

SLIDE H14.36 PINEAL BODY(H&E)



- Small lobules
- Pinealocytes and glial cells
- Interlobular CT
- Dark stained lamellated bodies(Corpora arenacea), brain sand