



## ***The GIANT***

Find herein histology practical presentations

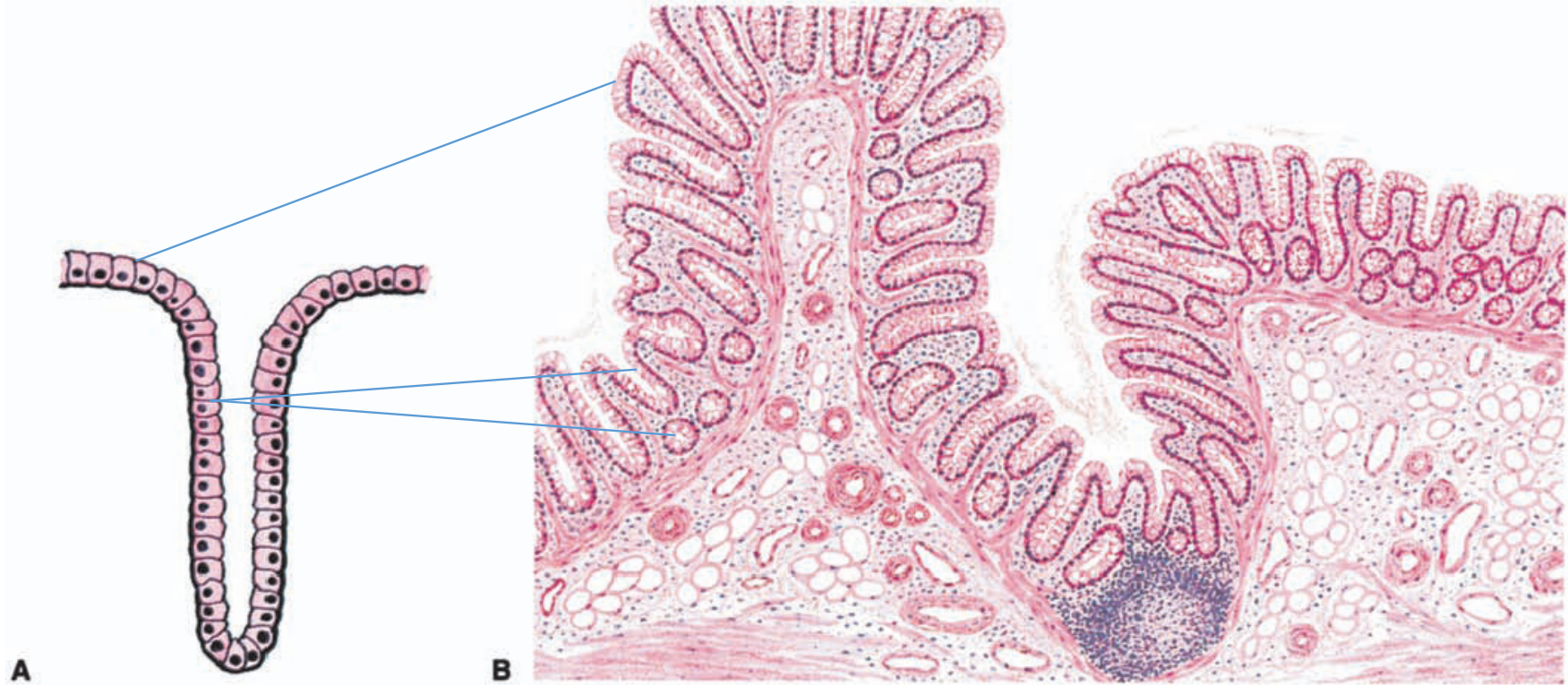
4,5,6,7,9,10,11,13.20 and 22.

[Giant compilation October 17<sup>th</sup> 2021.](#)

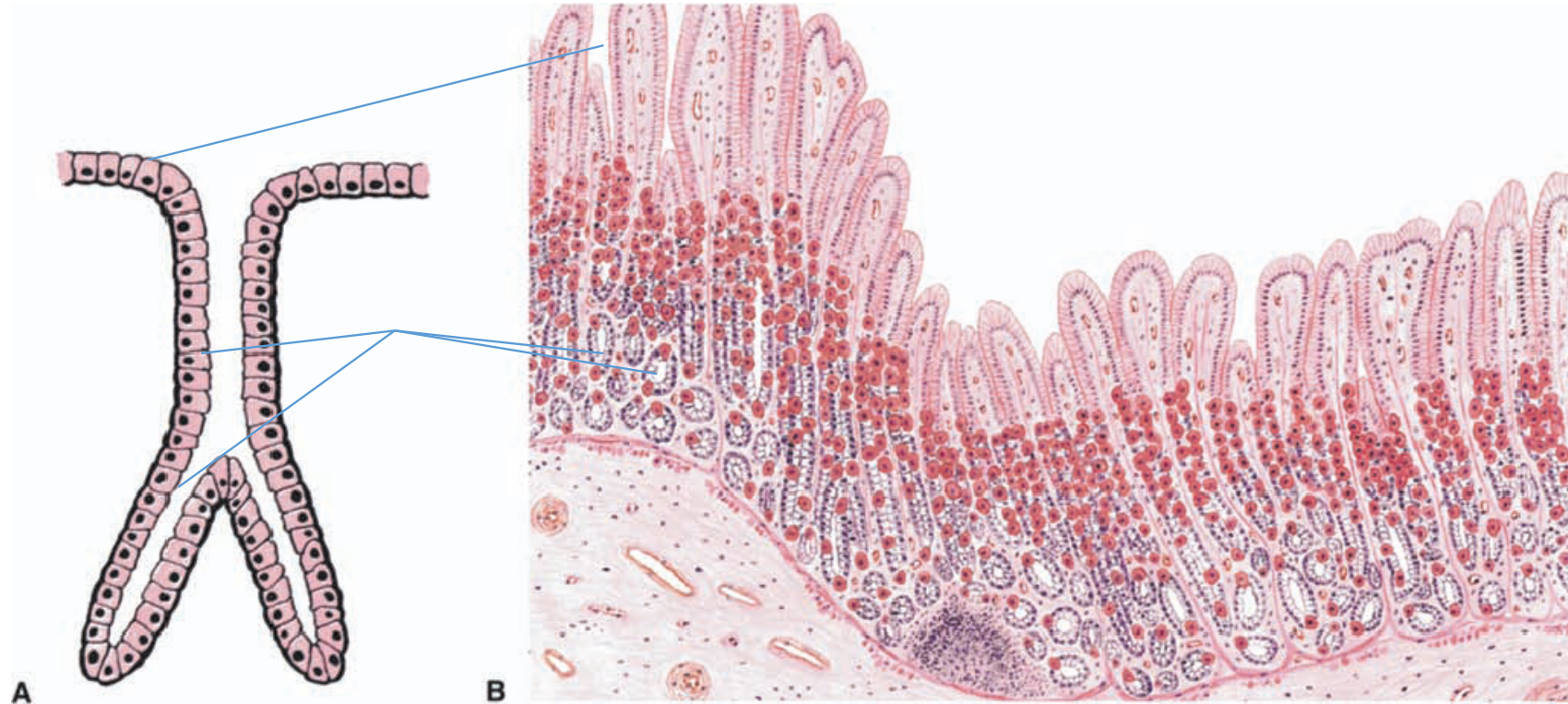
# PRACTICAL 4

EPITHELIAL 2-EXOCRINE GLANDS

# UNBRANCHED SIMPLE TUBULAR EXOCRINE GLANDS



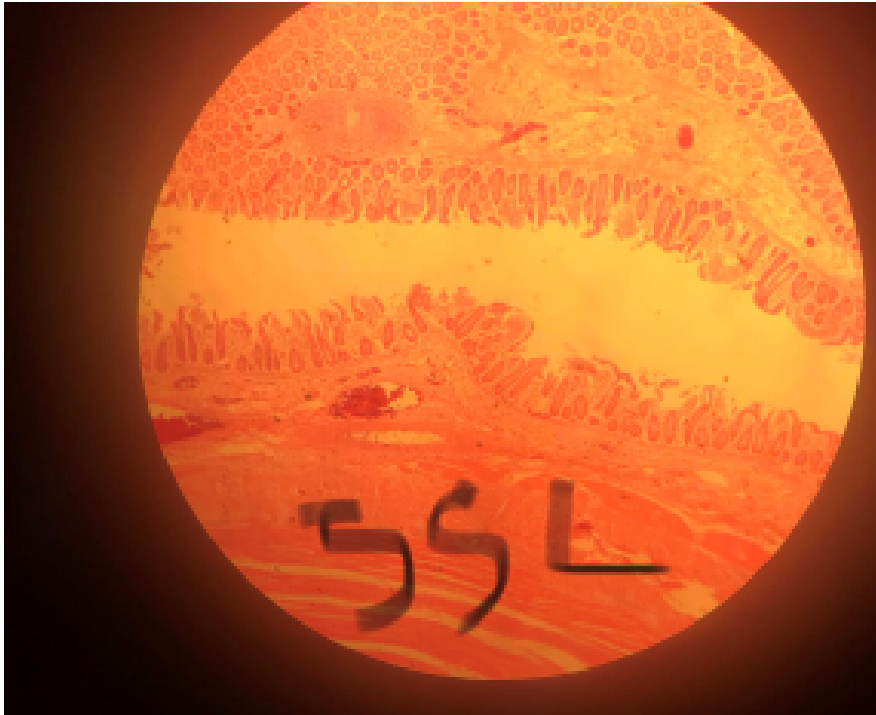# SIMPLE BRANCHED TUBULAR GLAND EXOCRINE GLAND



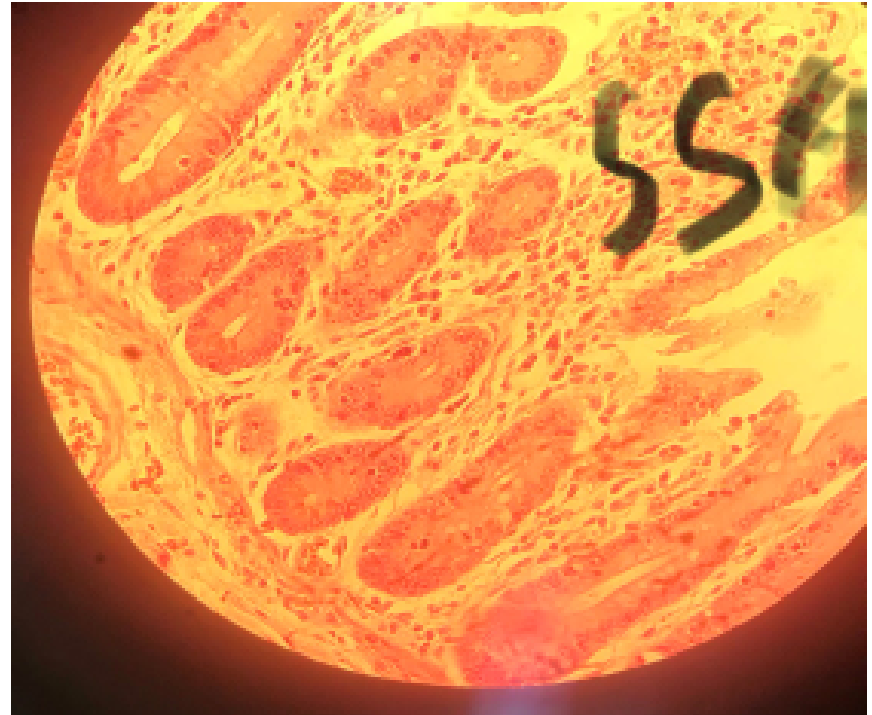# SIMPLE TUBULAR GLANDS AND UNICELLULAR GLANDS

## SLIDE 55 ILEUM (H&E)

- LP

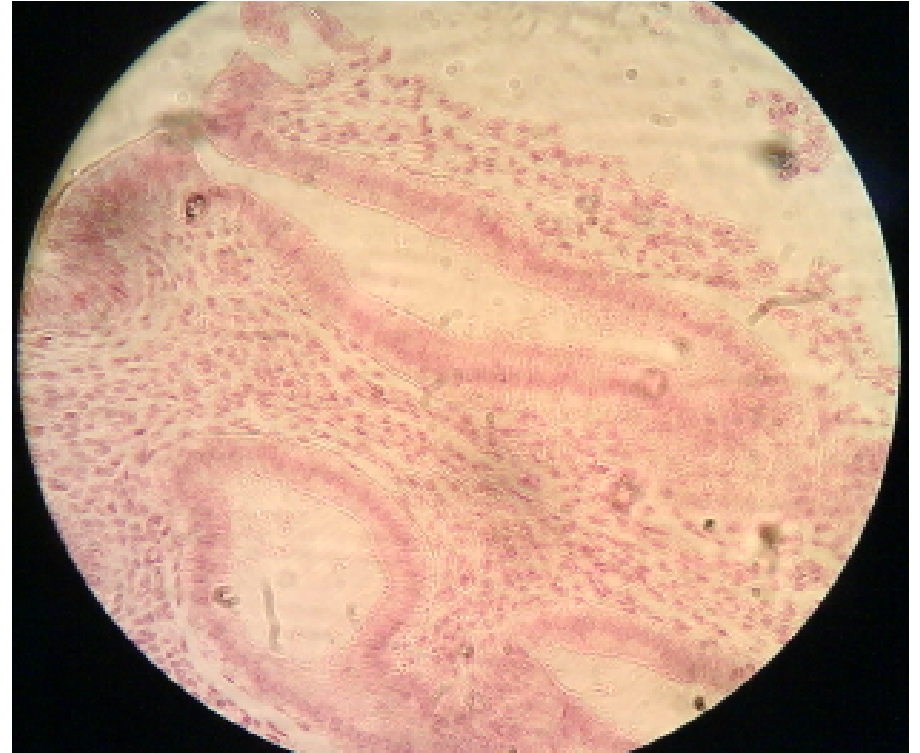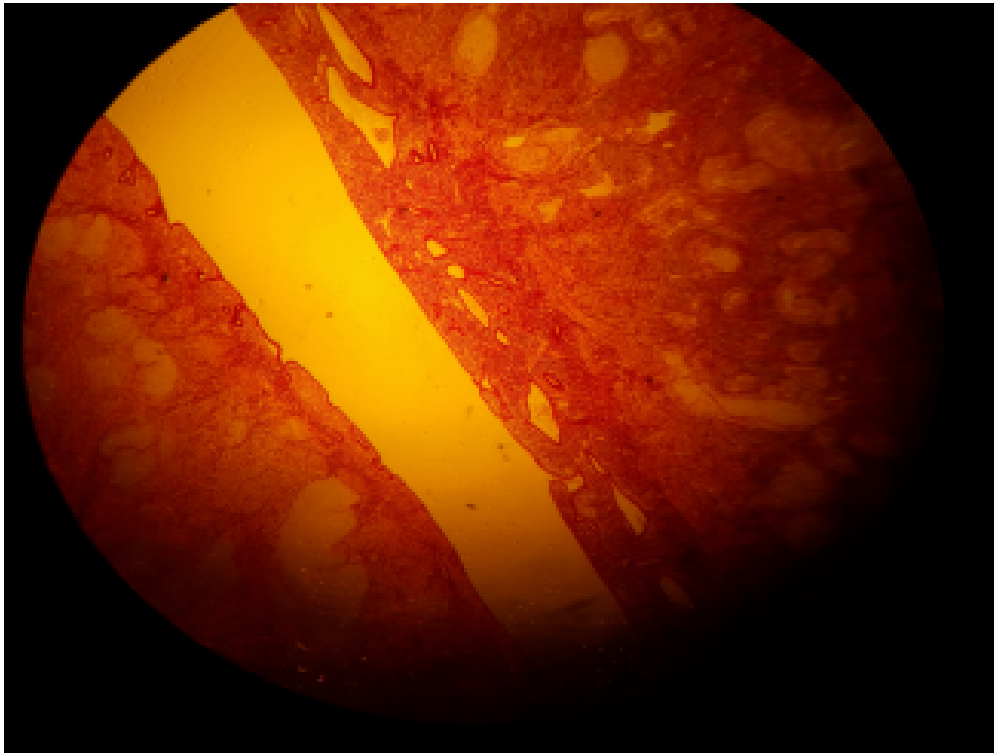


HP



SLIDE 88 UTERUS (H&E)  
SIMPLE TUBULAR GLANDS

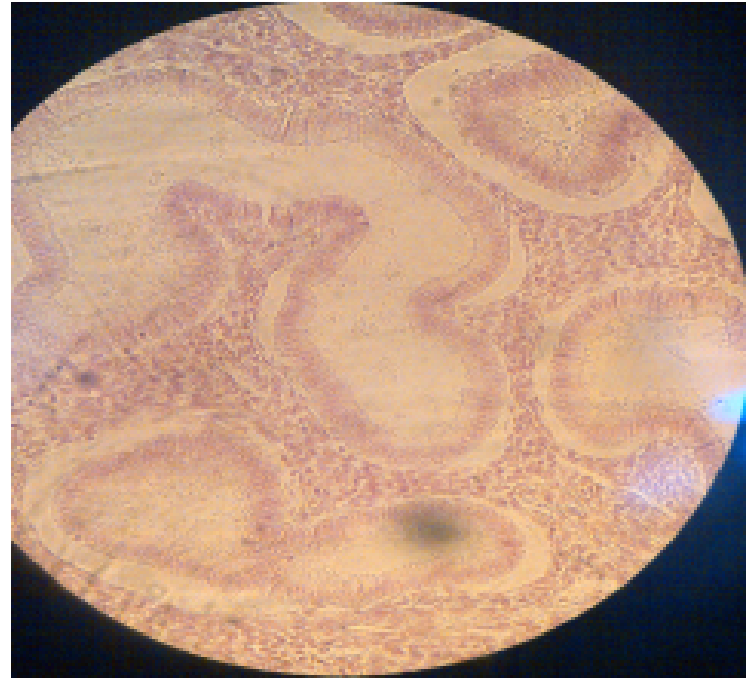
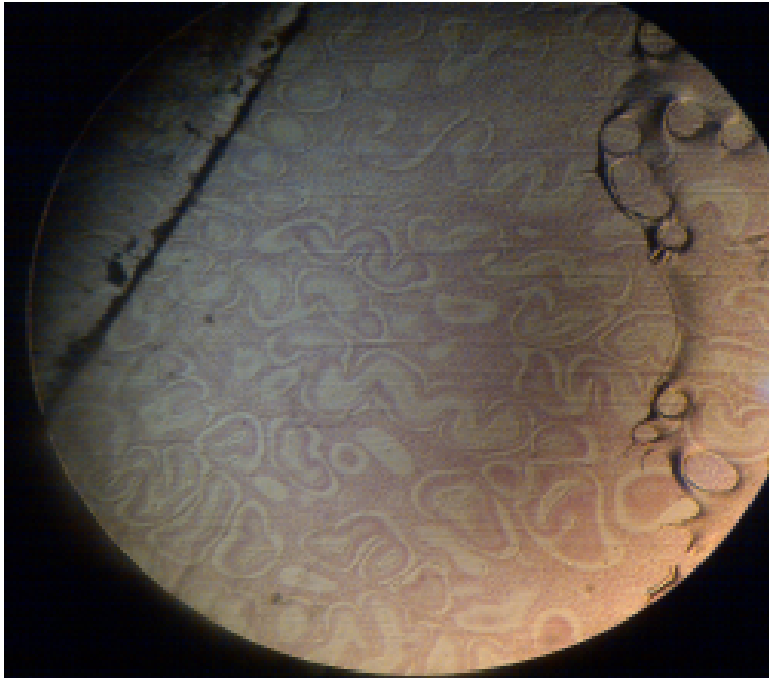
- LP NON-SECRETING



# UTERUS (H&E) SIMPLE TUBULAR GLANDS

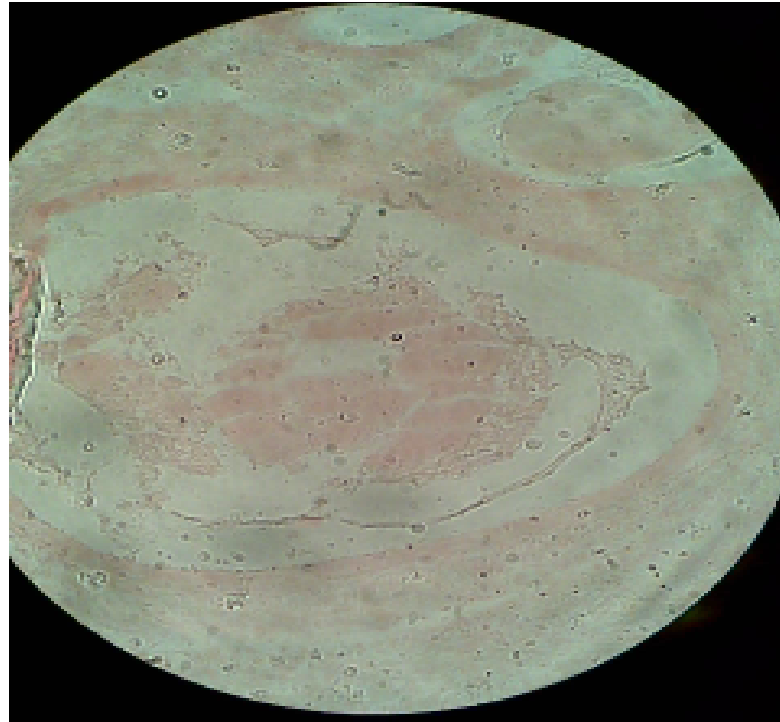
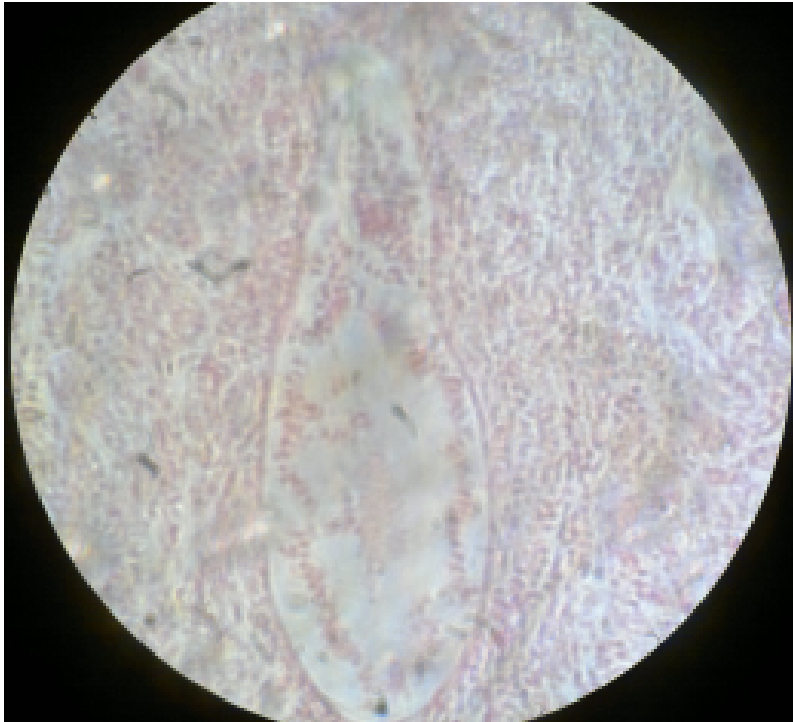
- TS:NON-SECRETING , LP

HP



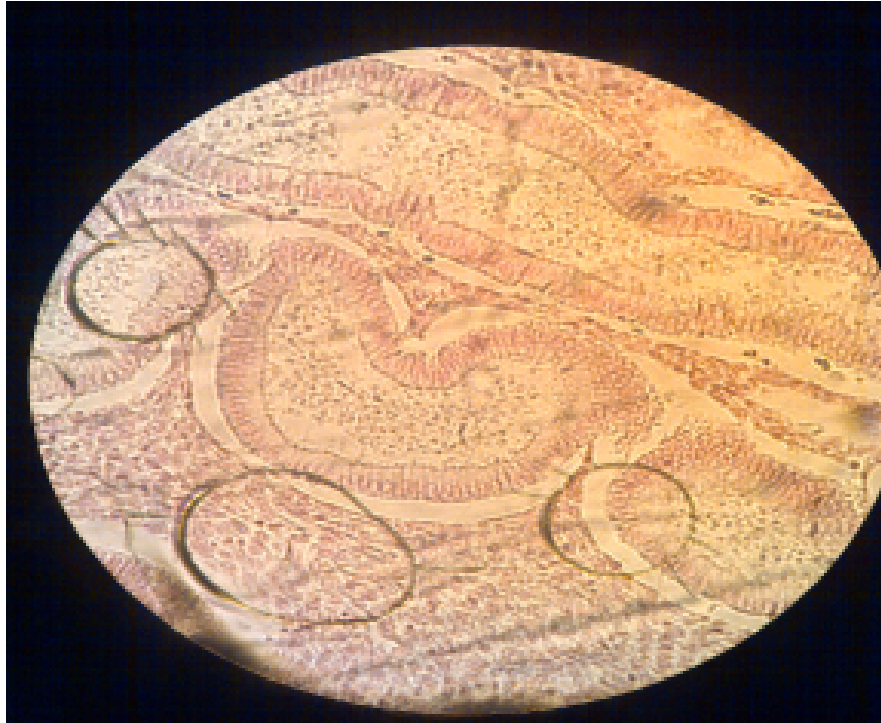# SLIDE H 9.31 UTERUS-SECRETING MUCOSA (H&E) SIMPLE TUBULAR GLANDS

- LS: HP SECRETING



# UTERUS-SECRETING MUCOSA (H&E) SIMPLE TUBULAR GLANDS

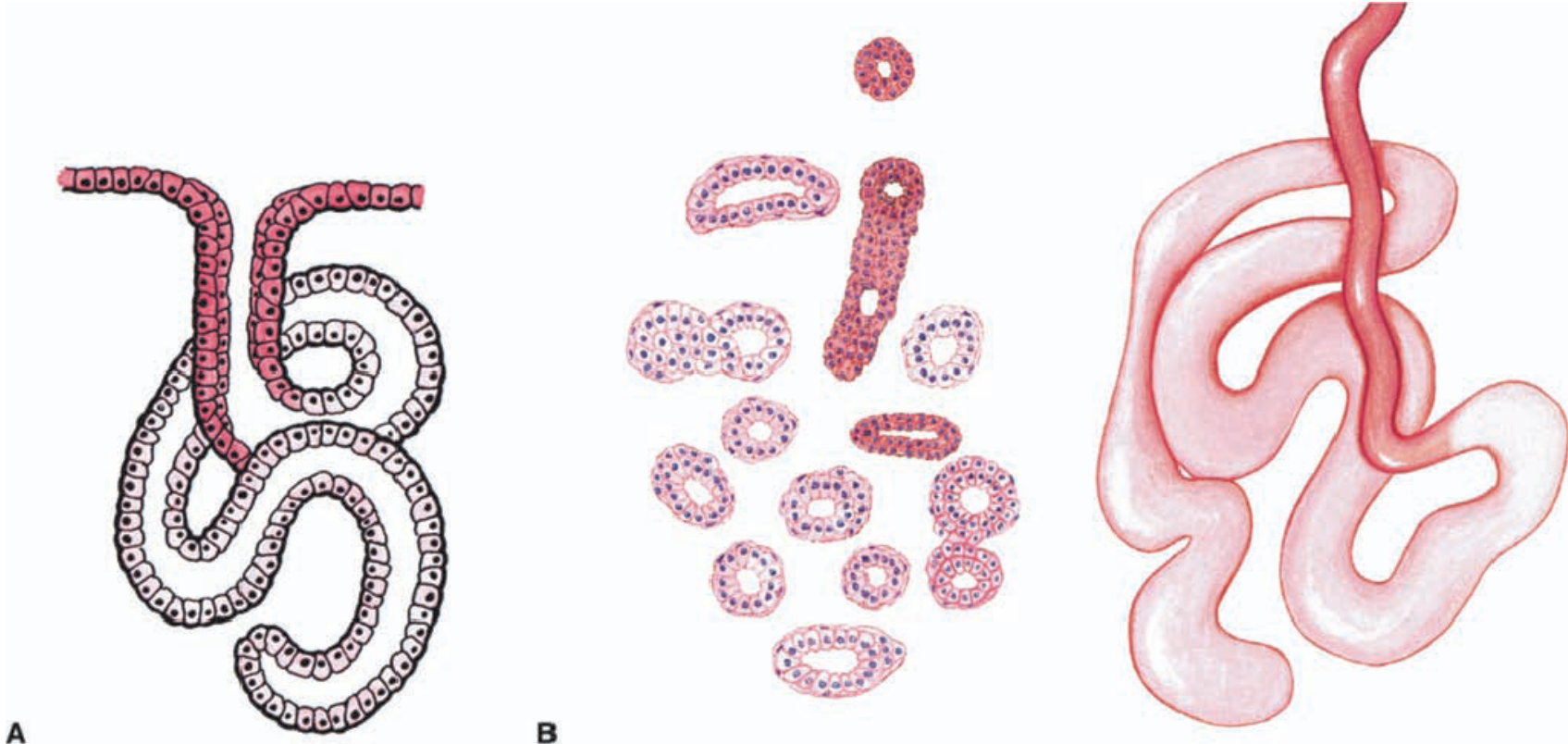
- TS: SECRETING, HP



# COILED TUBULAR (EXOCRINE) GLANDS: SWEAT GLANDS

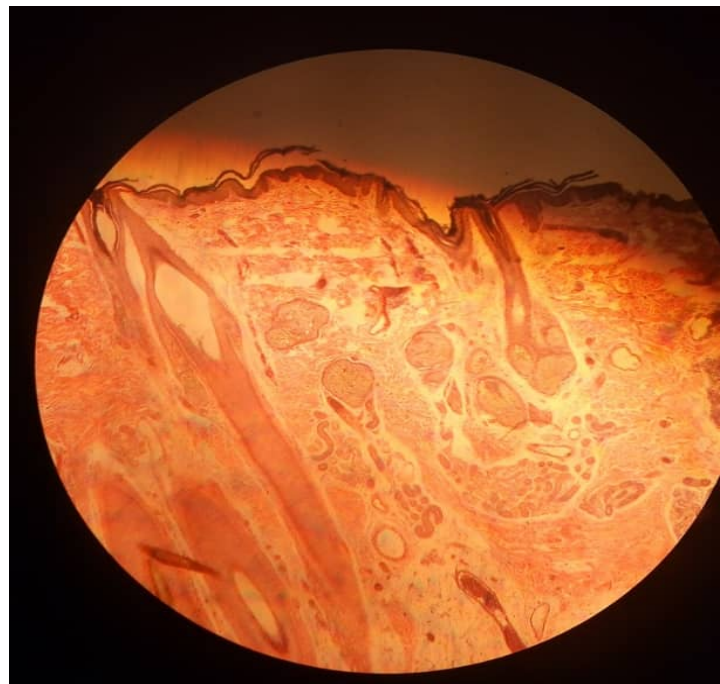
(A) DIAGRAM OF GLAND

(B) CROSS SECTION

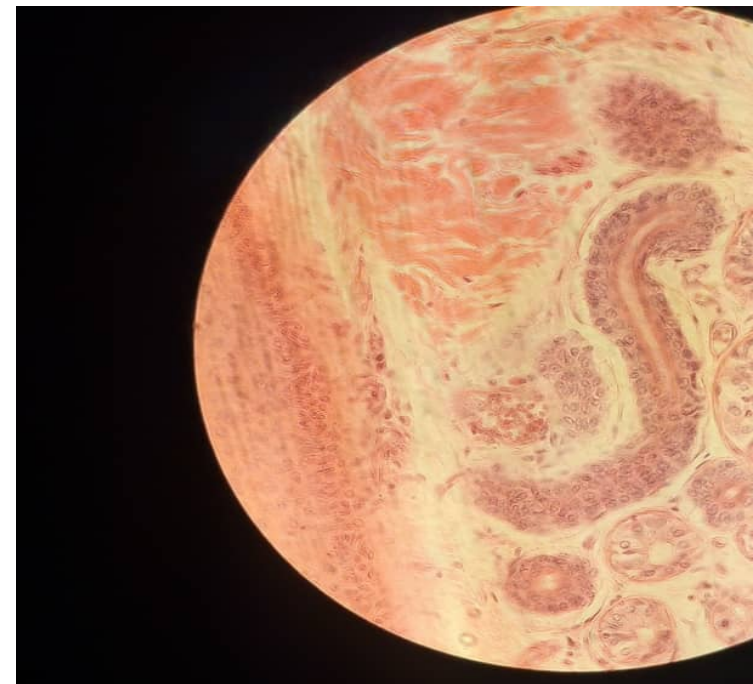


SLIDE 35 SCALP (H&E)  
SIMPLE COILED TUBULAR GLANDS (MEROCRINE/ECCRINE  
GLANDS)

• LP

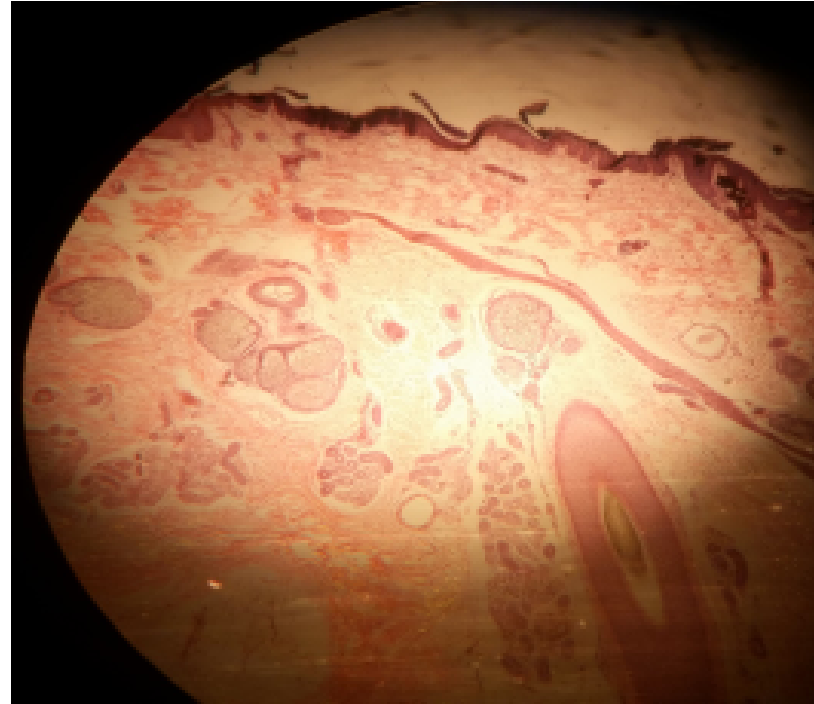
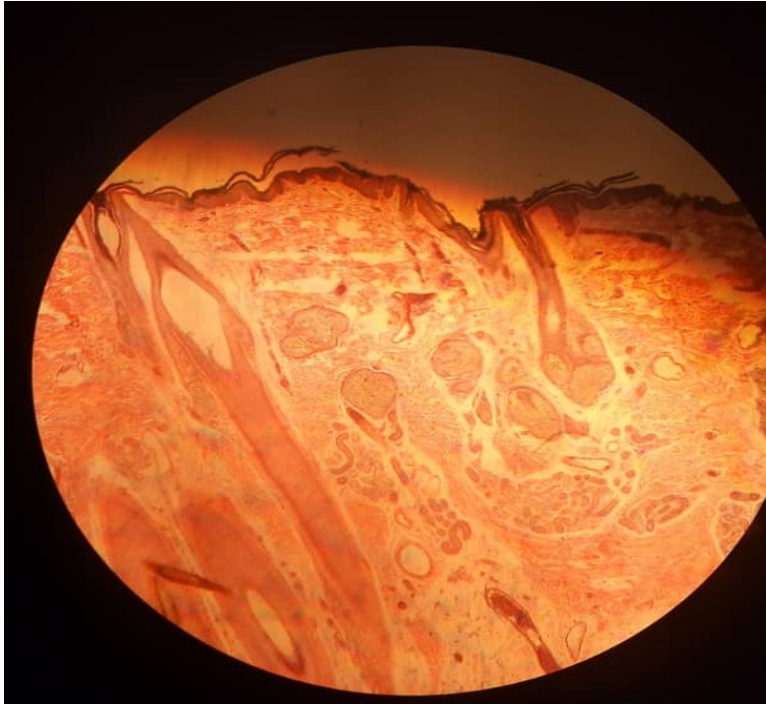


HP



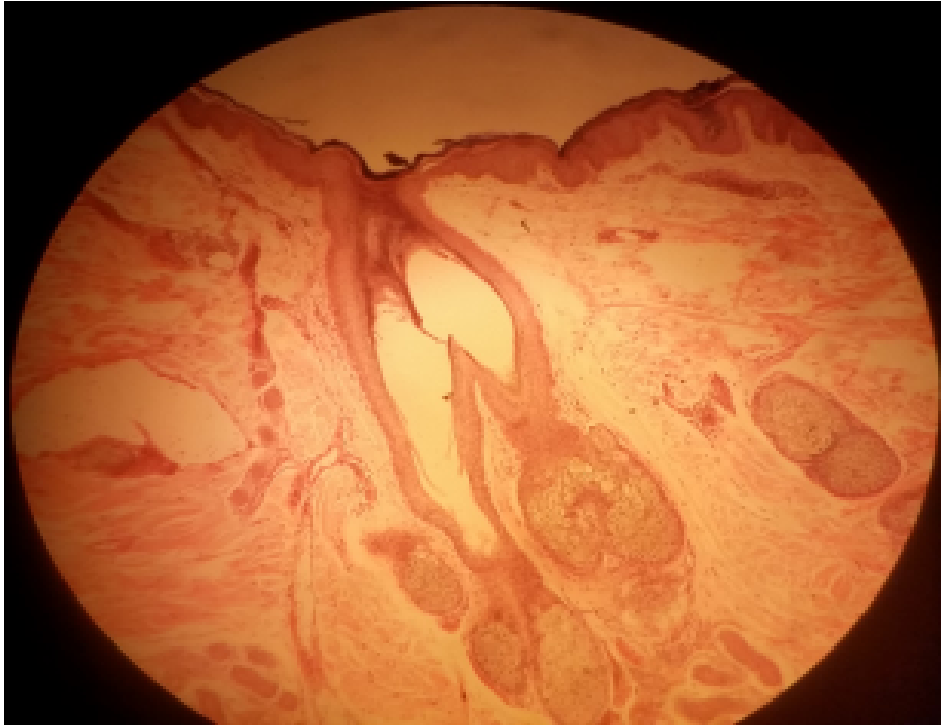
# SIMPLE BRANCHED SACCULAR/ACINAR GLANDS SLIDE 35 SCALP (H&E) SEBACEOUS GLANDS

- LP

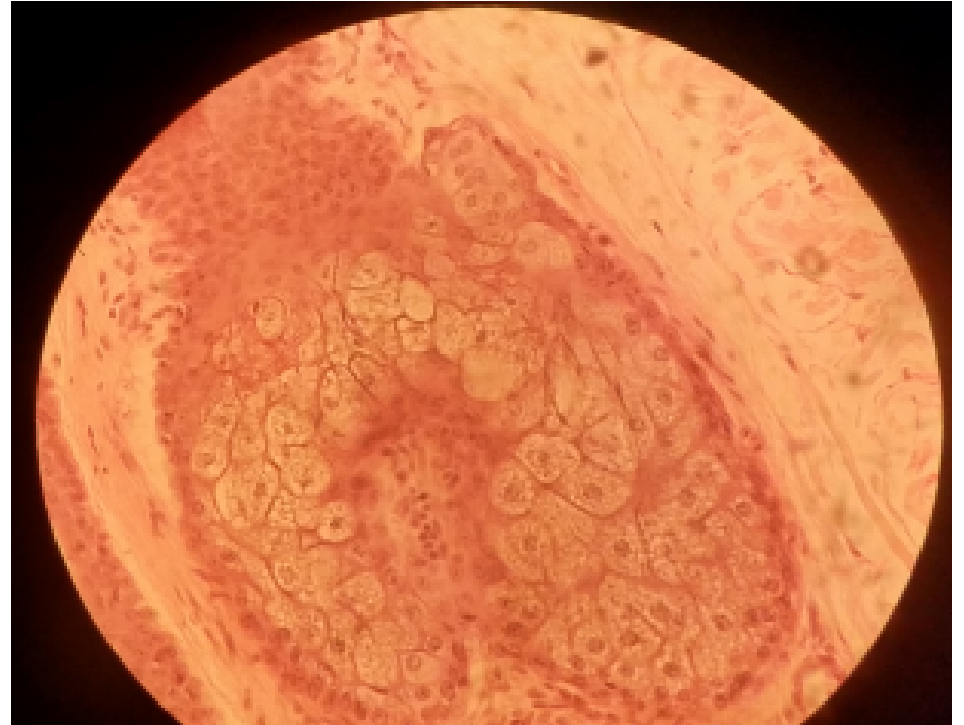


SIMPLE BRANCHED SACCULAR/ACINAR GLANDS  
SLIDE 35 SCALP (H&E) SEBACEOUS GLANDS  
(HOLOCRINE MODE OF SECRETION)

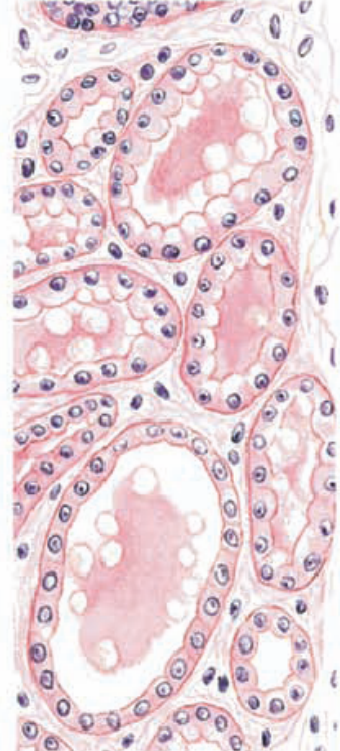
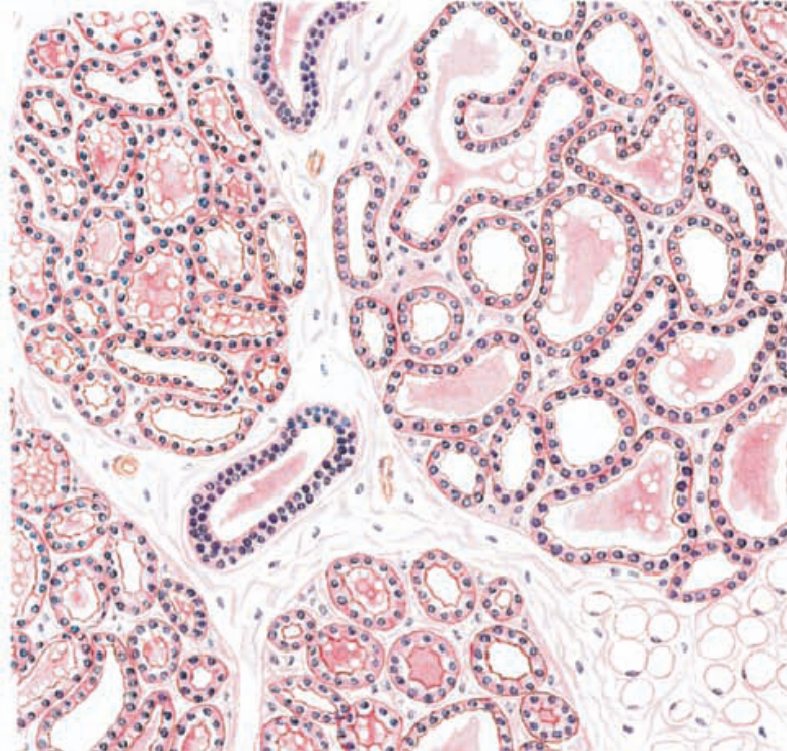
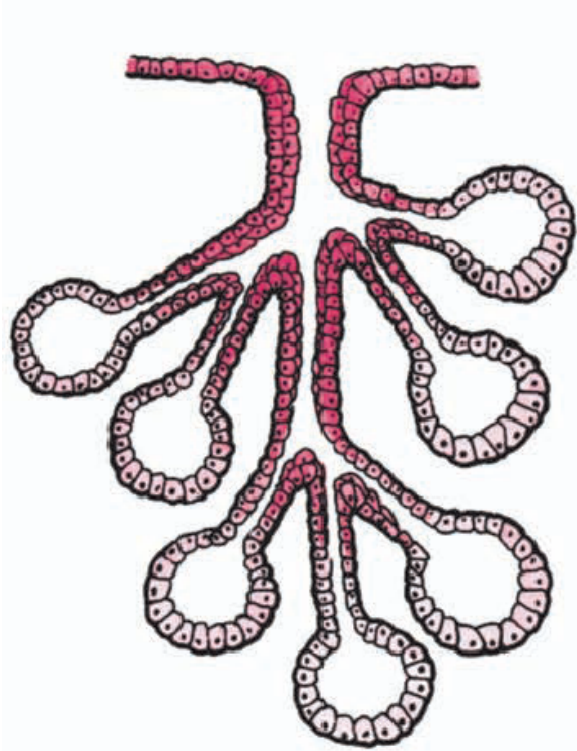
• MP



HP

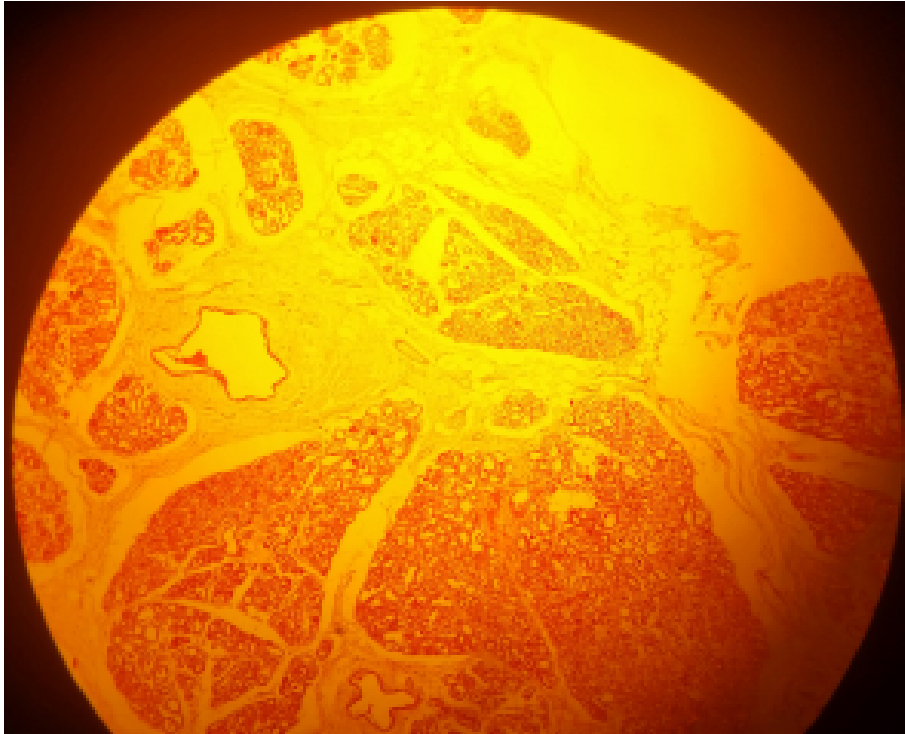


COMPOUND ACINAR (EXOCRINE) GLAND: MAMMARY GLAND (H&E)  
(A) DIAGRAM OF GLAND  
(B) DURING LACTATION

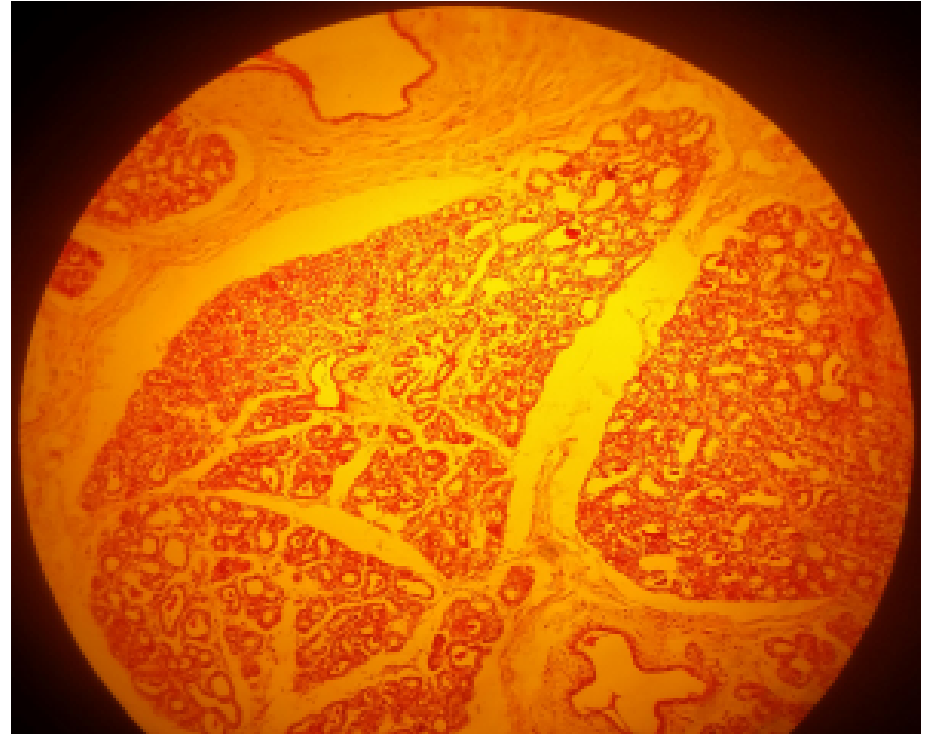


COMPOUND AVEOLAR GLANDS  
SLIDE 95 BREAST (MAMMARY GLAND) (H&E)  
NON-LACTATING

• LP

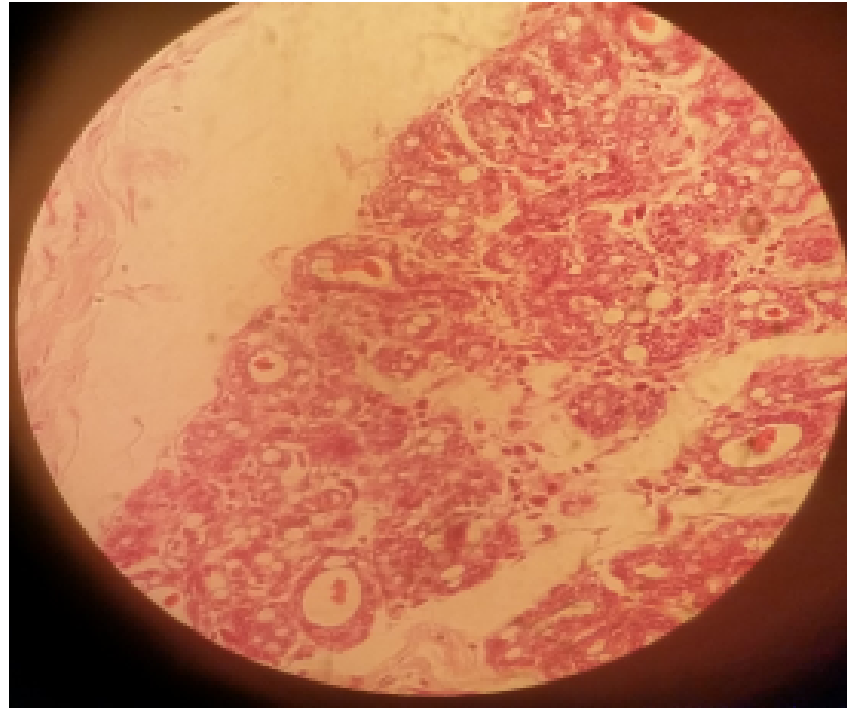


MP



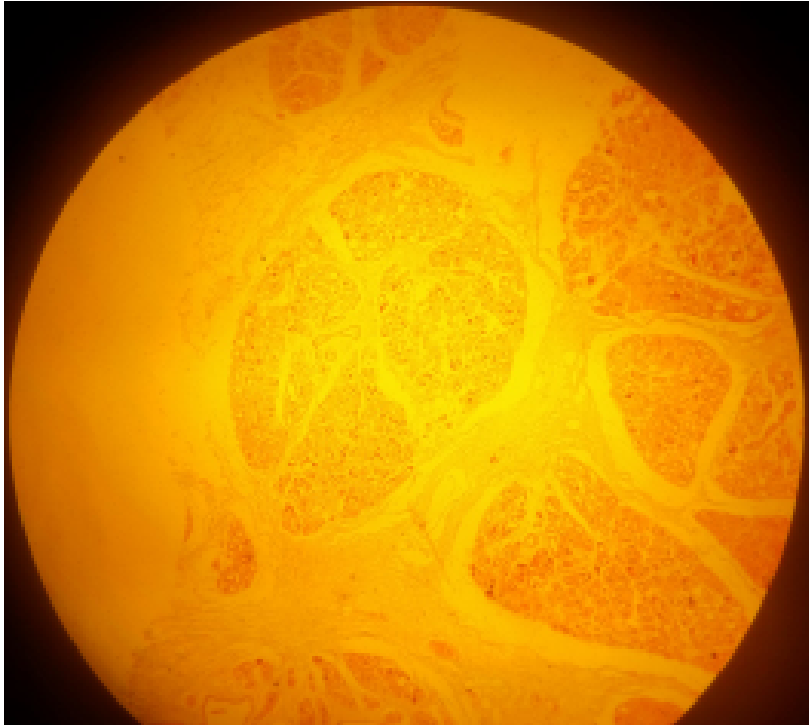
COMPOUND AVEOLAR GLANDS  
SLIDE 95 BREAST (MAMMARY GLAND) (H&E)  
NON-LACTATING

- HP

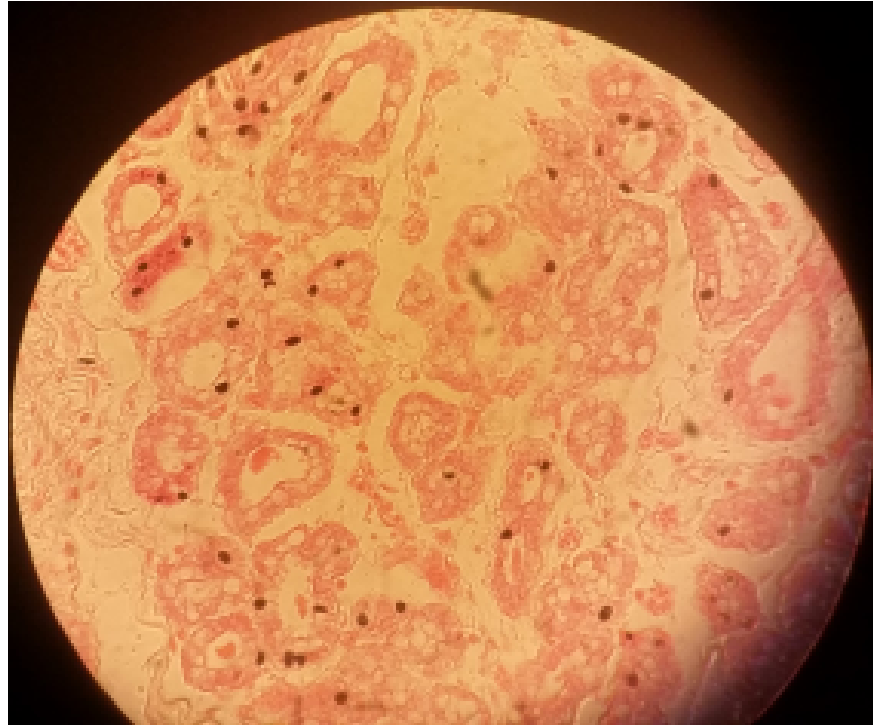

COMPOUND AVEOLAR/ACINAR GLANDS  
SLIDE H9.352 BREAST (MAMMARY GLAND) (H&E)  
LACTATING (APOCRINE MODE OF SECRETION)

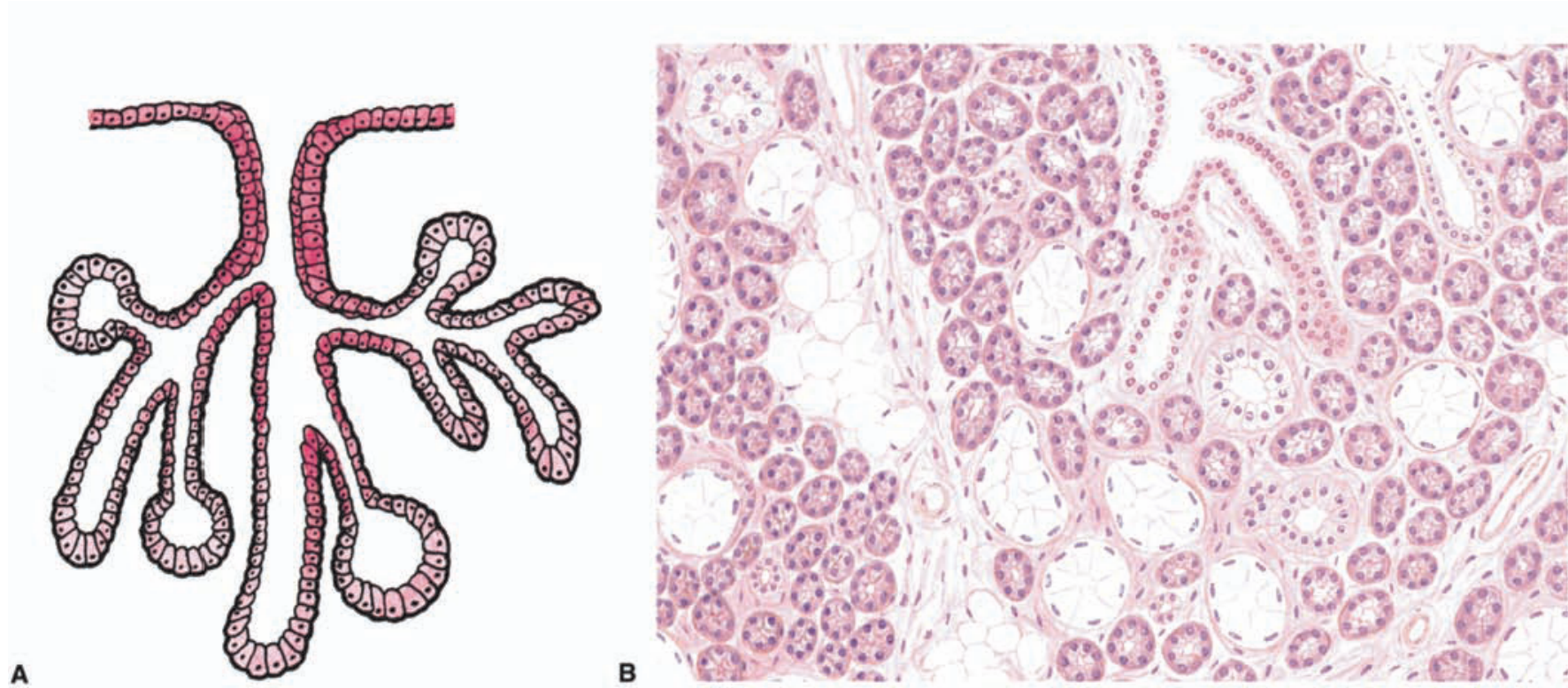
• LP



HP

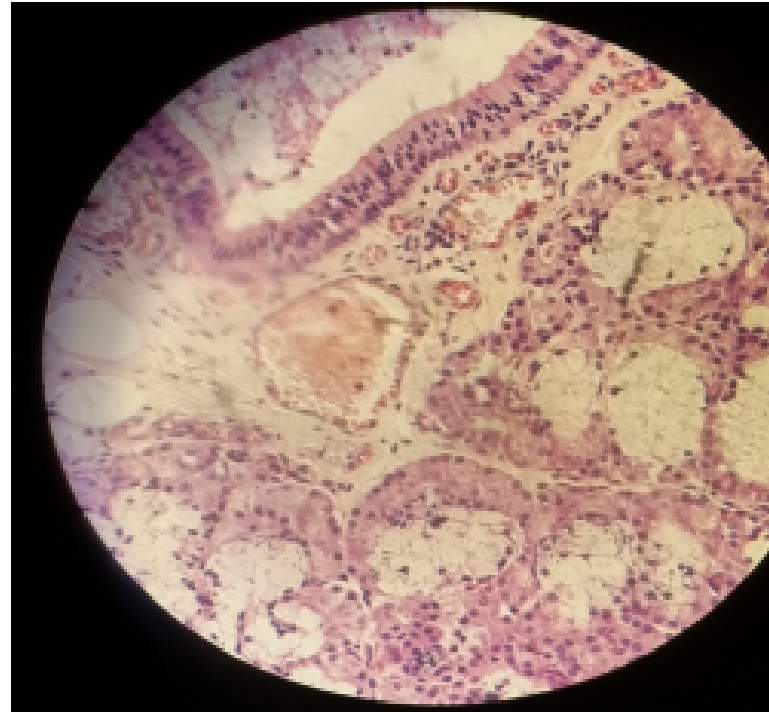
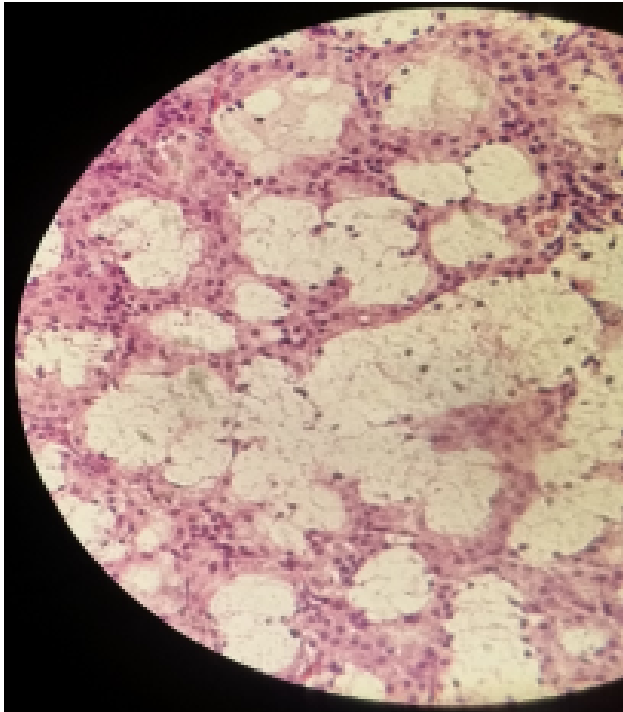


# COMPOUND TUBULOACINAR (EXOCRINE) GLAND



COMPOUND TUBULOACINAR (EXOCRINE) GLANDS: SEROUS AND  
MUCOUS ACINI  
SLIDE 48 SUBLINGUAL GLAND (MALLORY)  
(MEROCRINE MODE OF SECRETION)

- HP



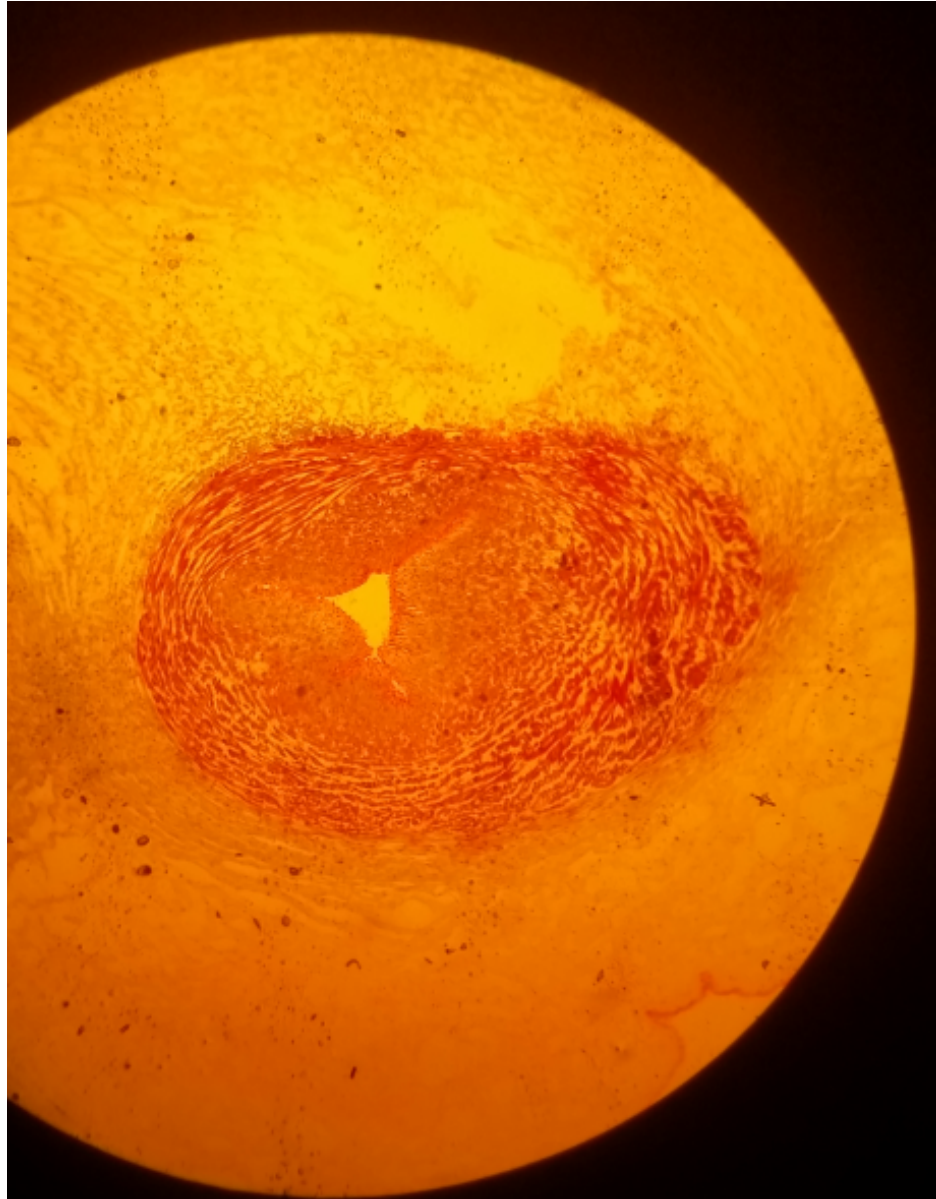
# **CONNECTIVE TISSUE PROPER**

## **PRACTICAL 5**

# Mucous connective tissue

## Slide 2: Umbilical cord (Gomori)

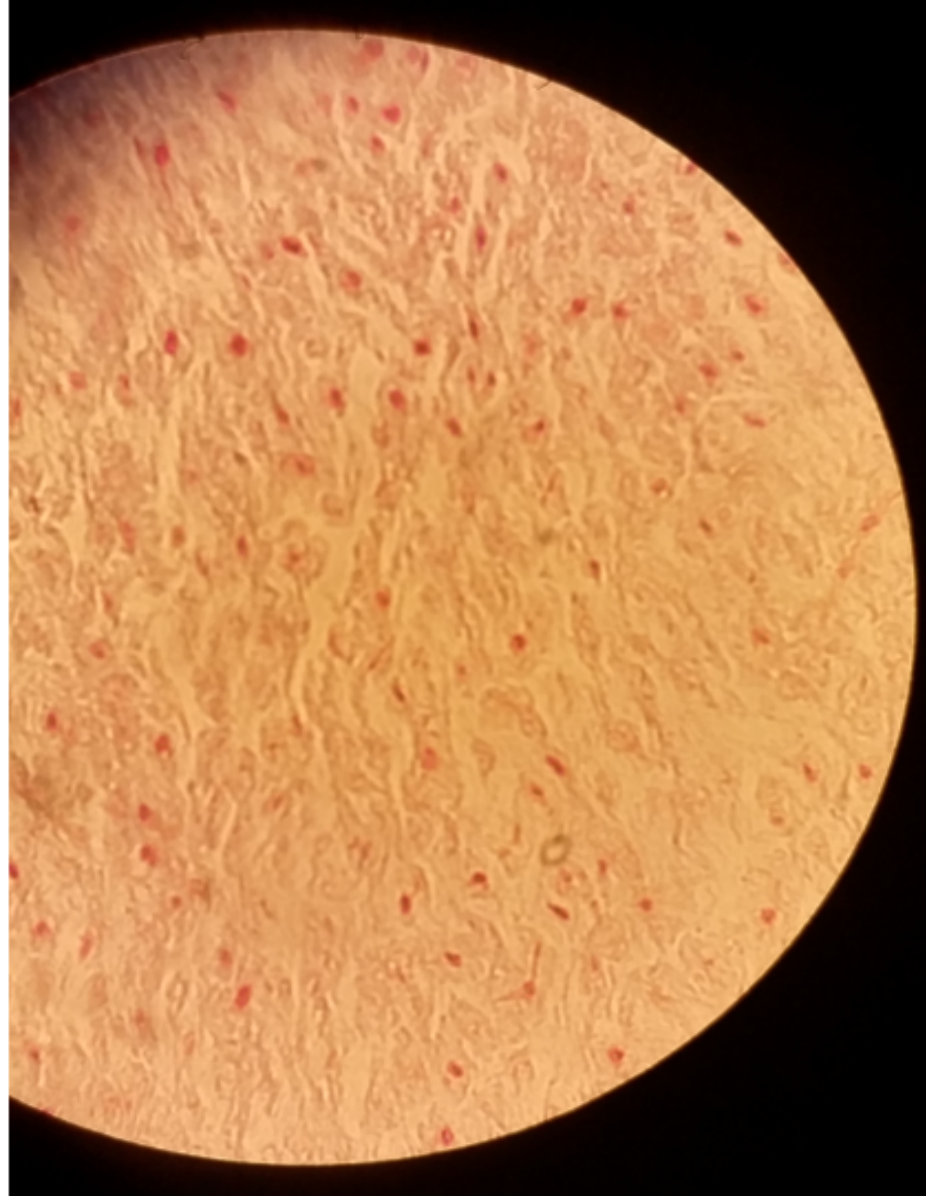
LP




# Mucous connective tissue

## Slide 2: Umbilical cord (Gomori)

- HP

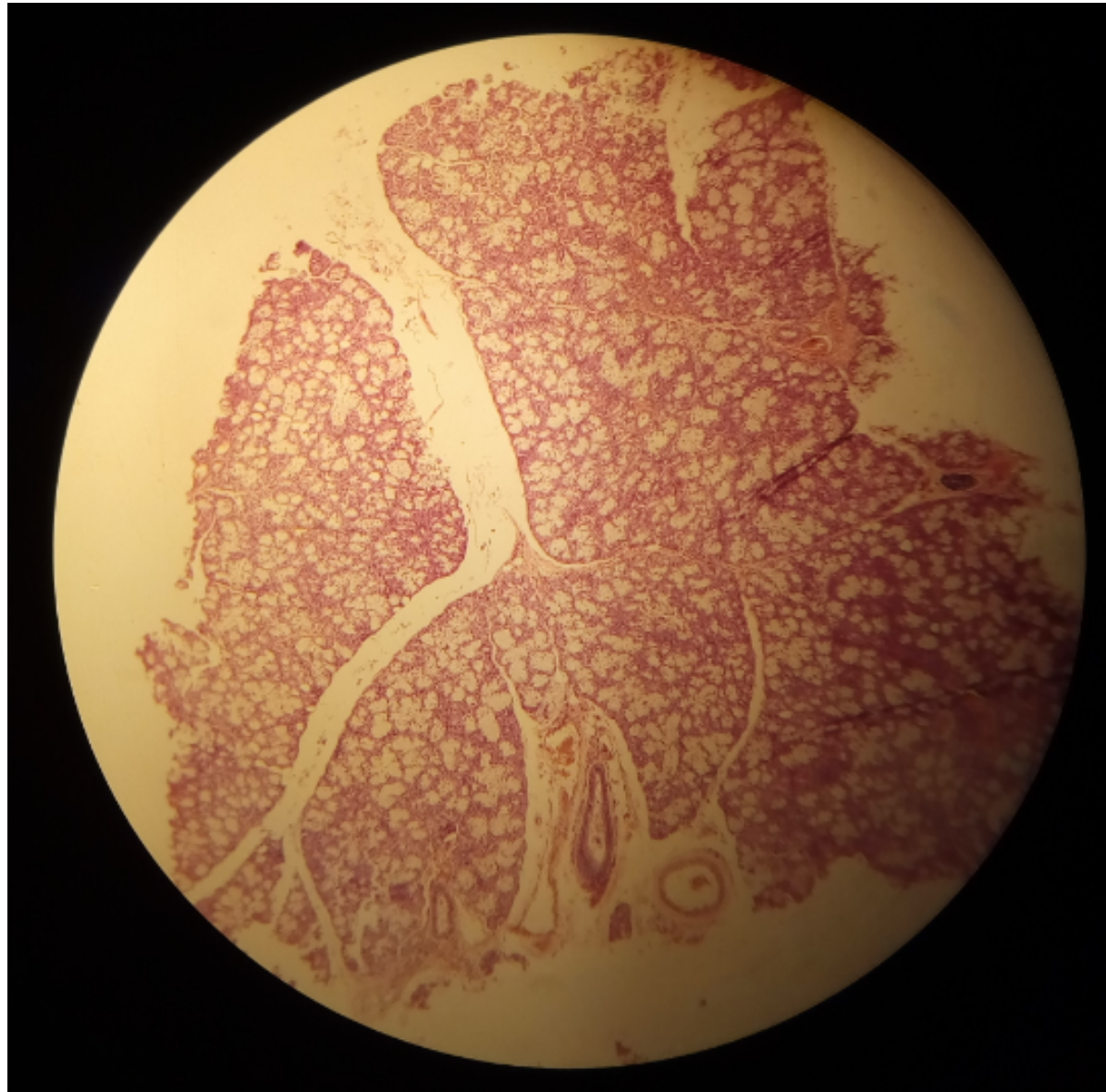




# Dense, irregular CT

## Slide 48: Sublingual gland (Mallory)

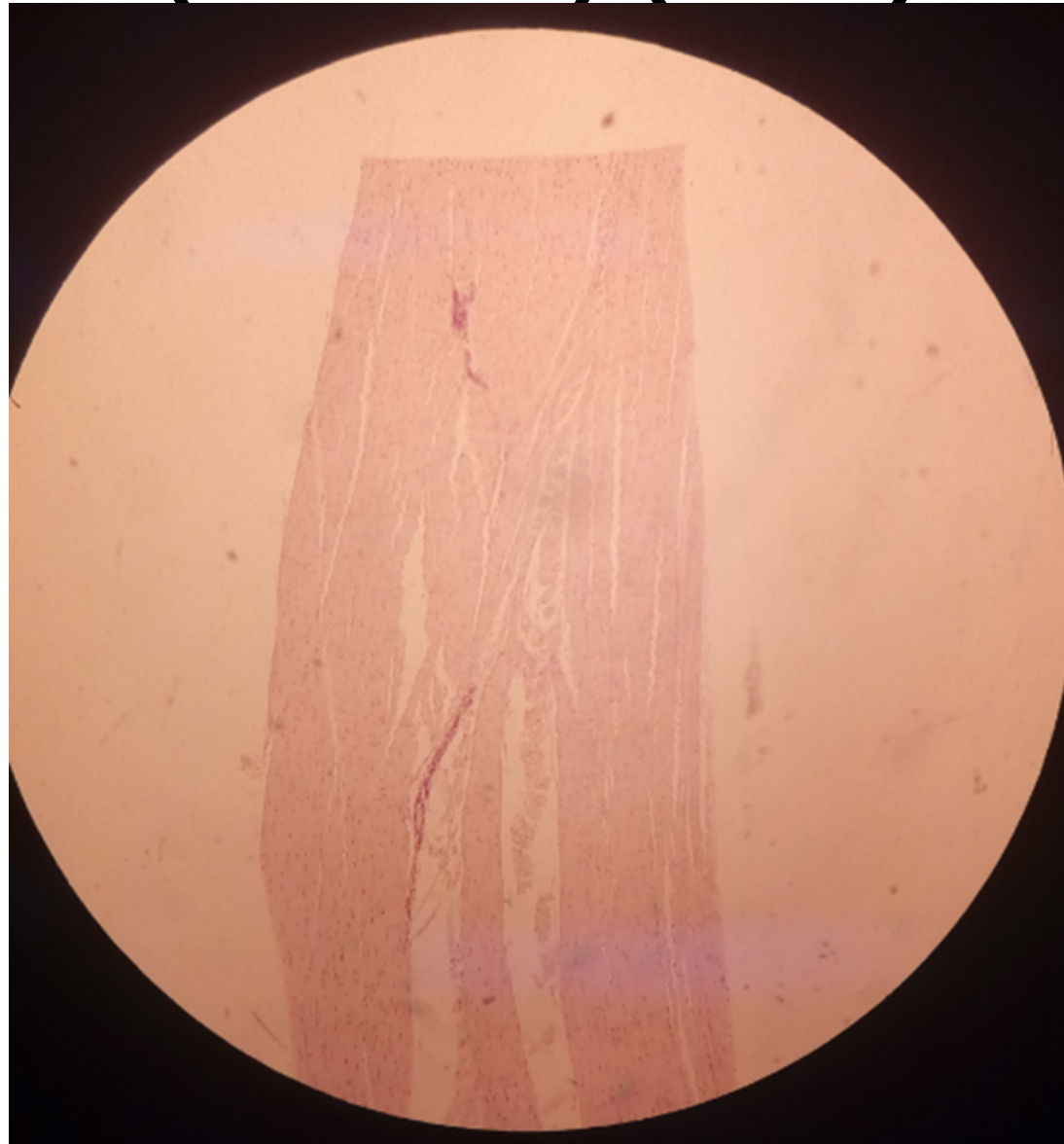
- LP



# Dense, regular CT

## Slide H2 11: White fibrous tissue (Tendon) (H&E)

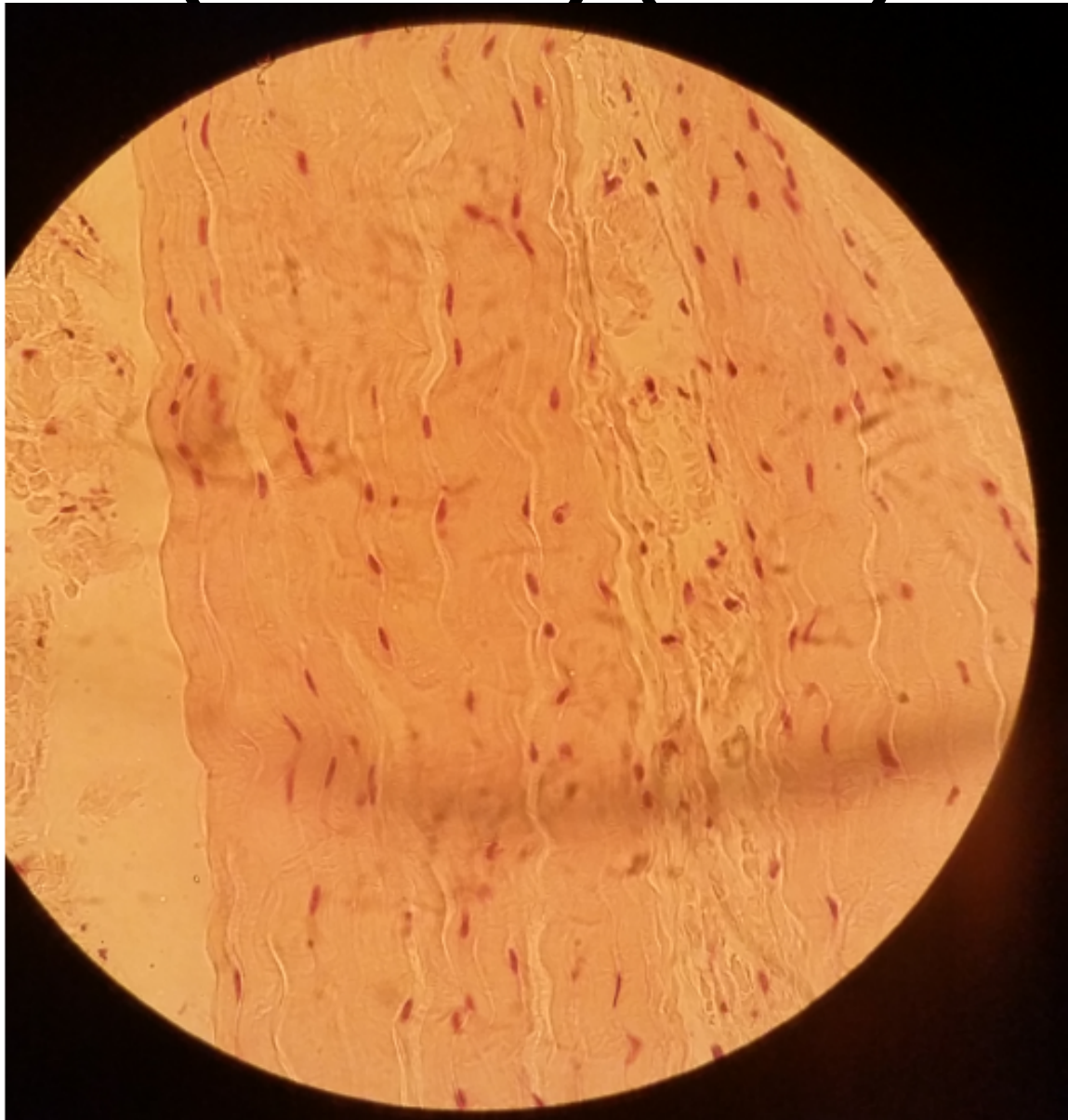
- LP



# Dense, regular CT

## Slide H2 11: White fibrous tissue (Tendon) (H&E)

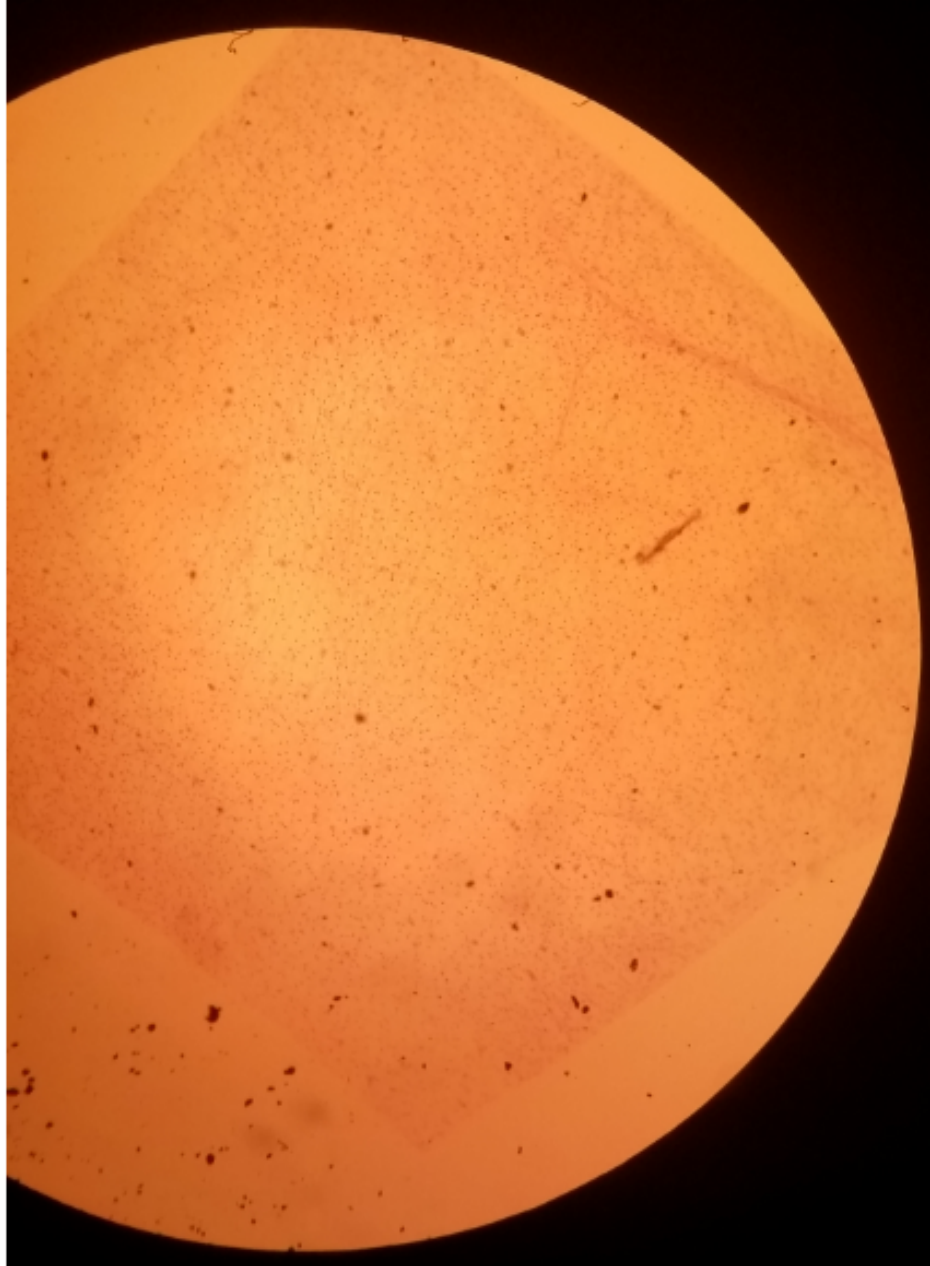
- HP



# Loose (areolar) connective tissue

## Slide H2.13 tissue spread

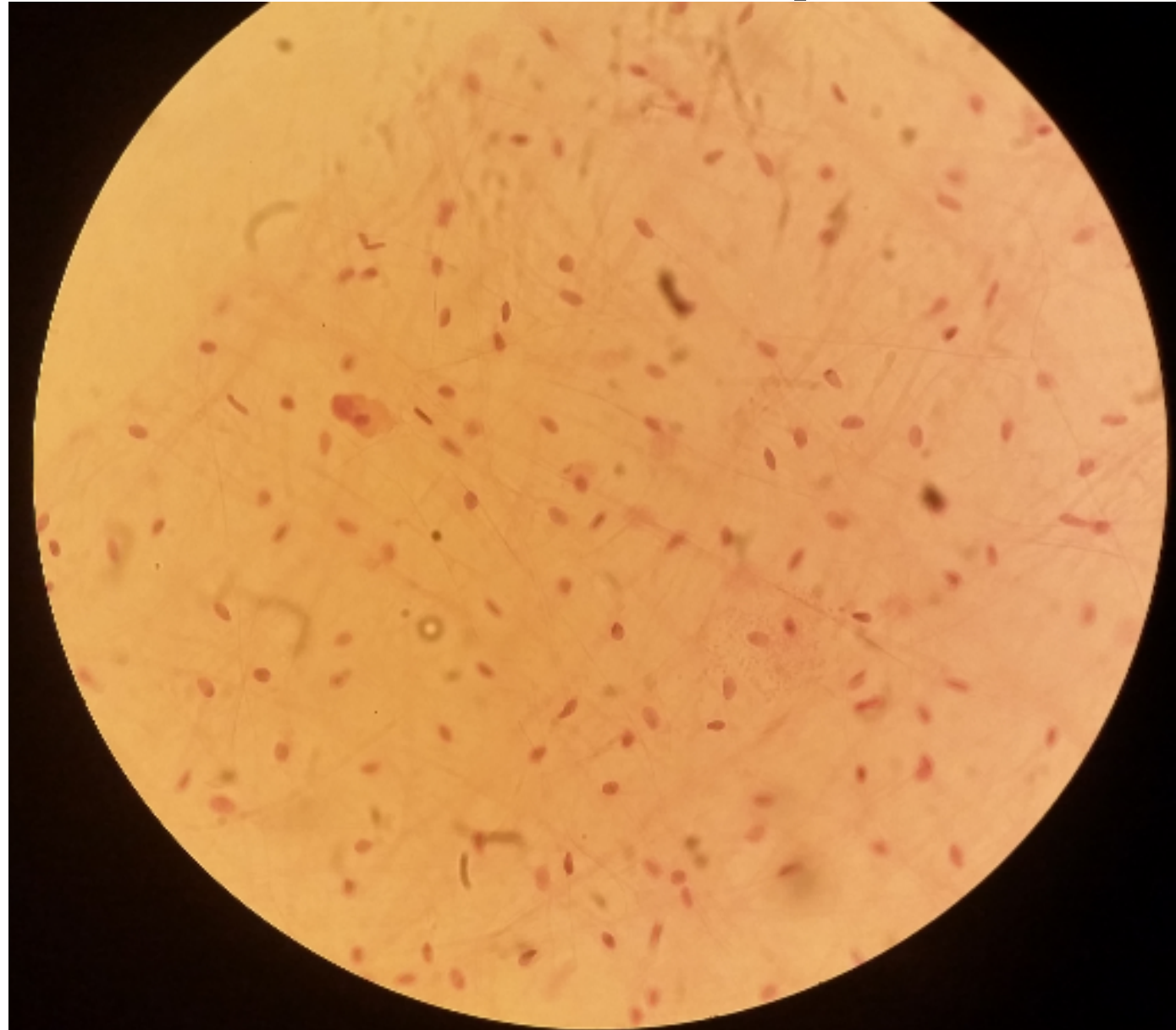
- LP



# Loose (areolar) connective tissue

## Slide H2.13 tissue spread

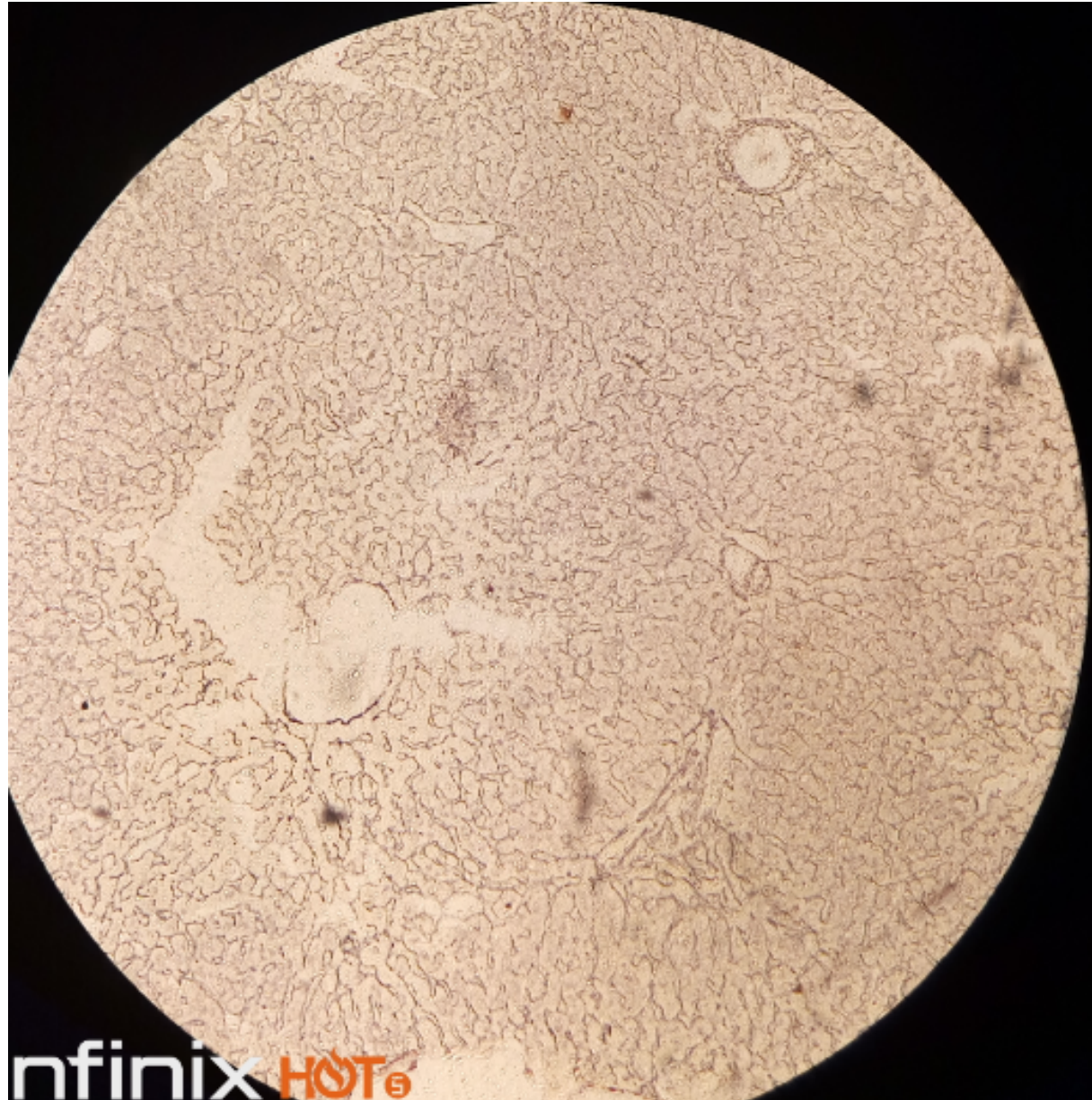
- HP



# Reticular fibres

## Slide 63 silver stain liver

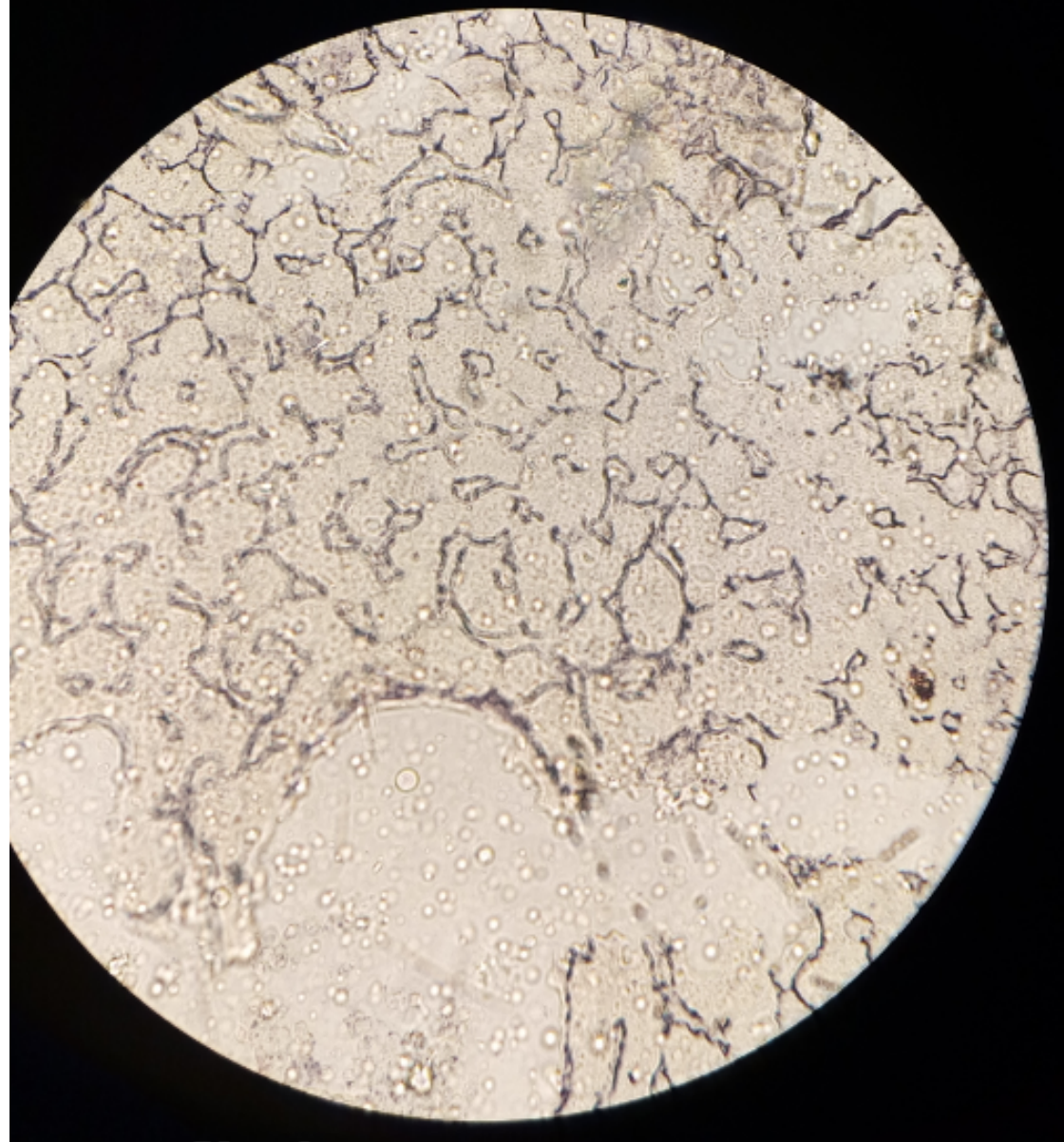
- Lp



# Reticular fibres

## Slide 63 silver stain liver

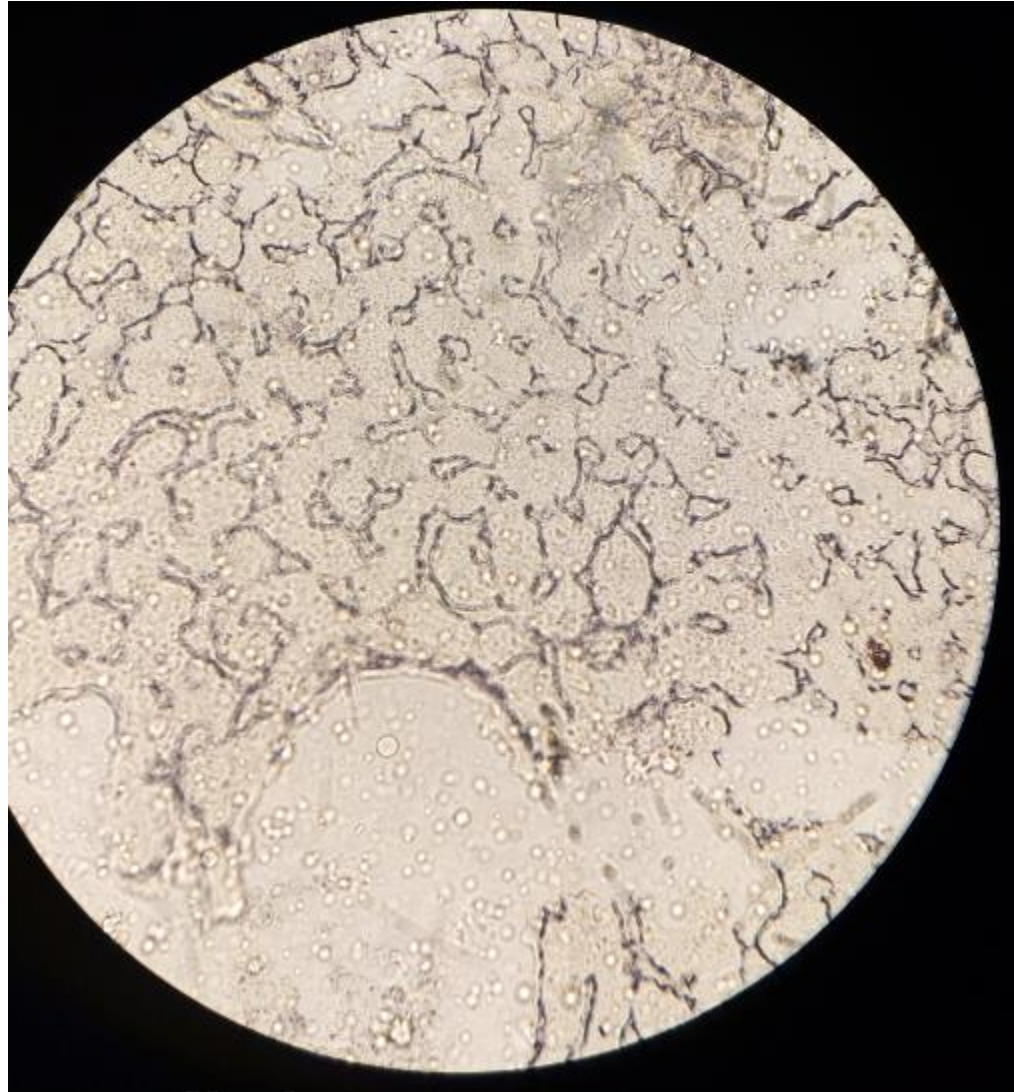
- Hp



# Reticular fibres

## Slide 63 silver stain liver

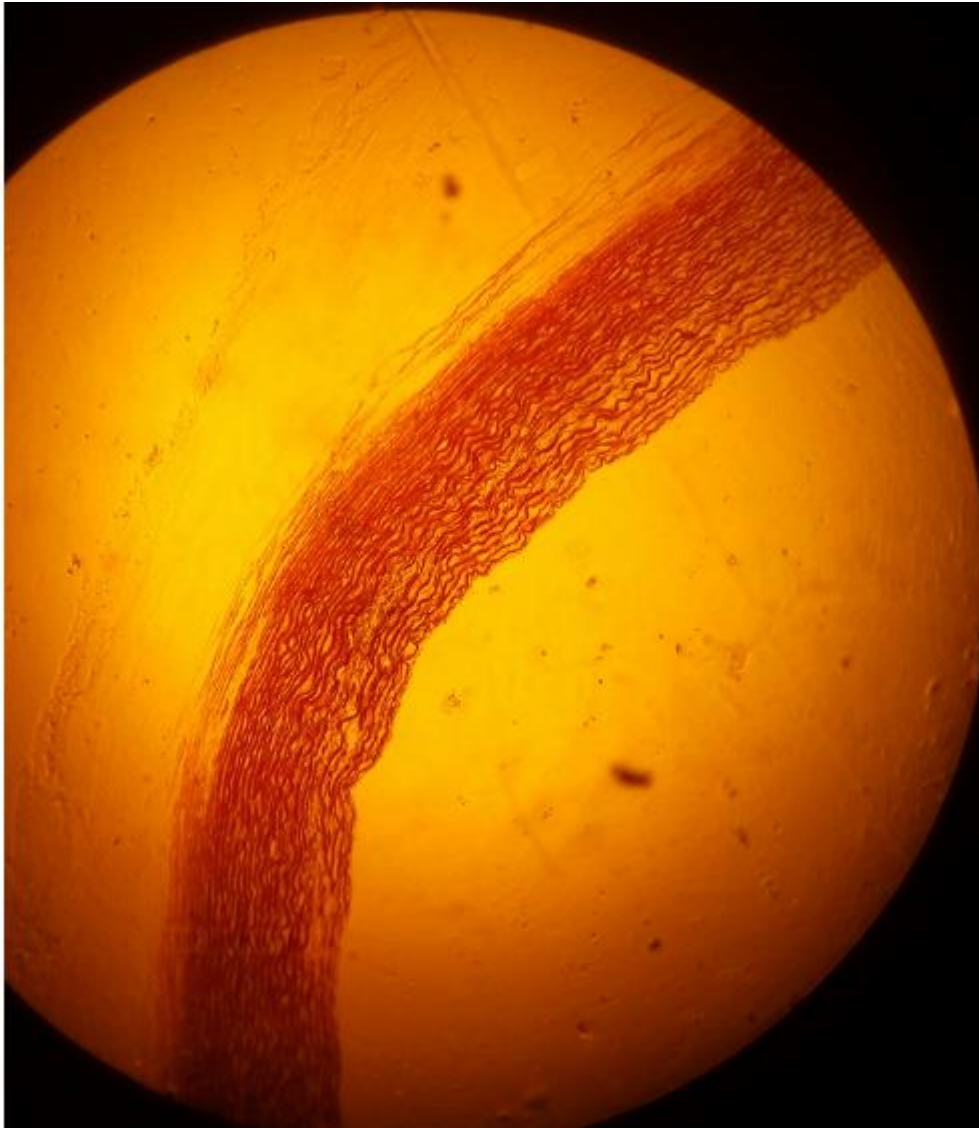
- Hp



# Elastic tissue

## Slide H2.63

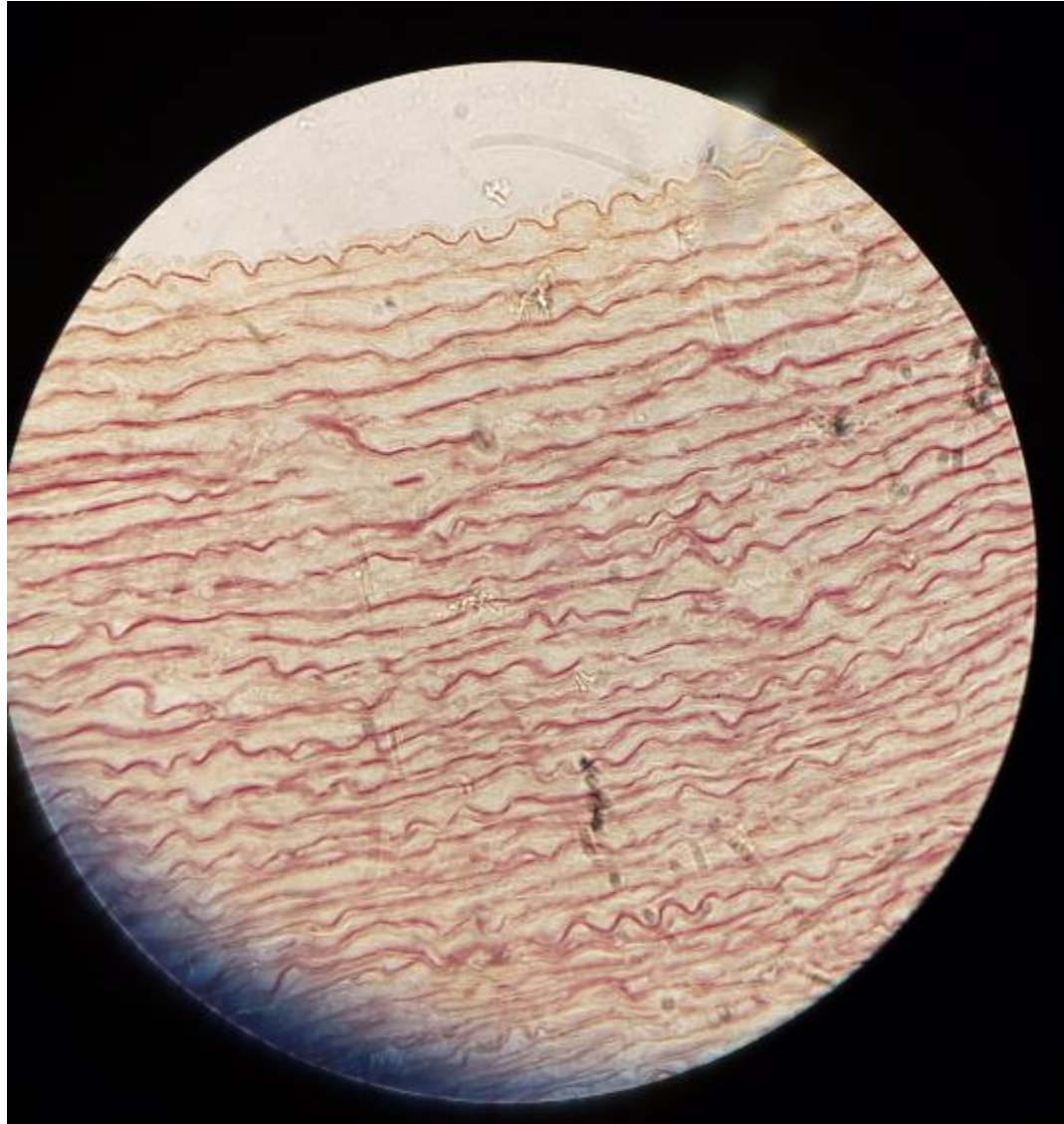
- LP



# Elastic tissue

## Slide H2.63

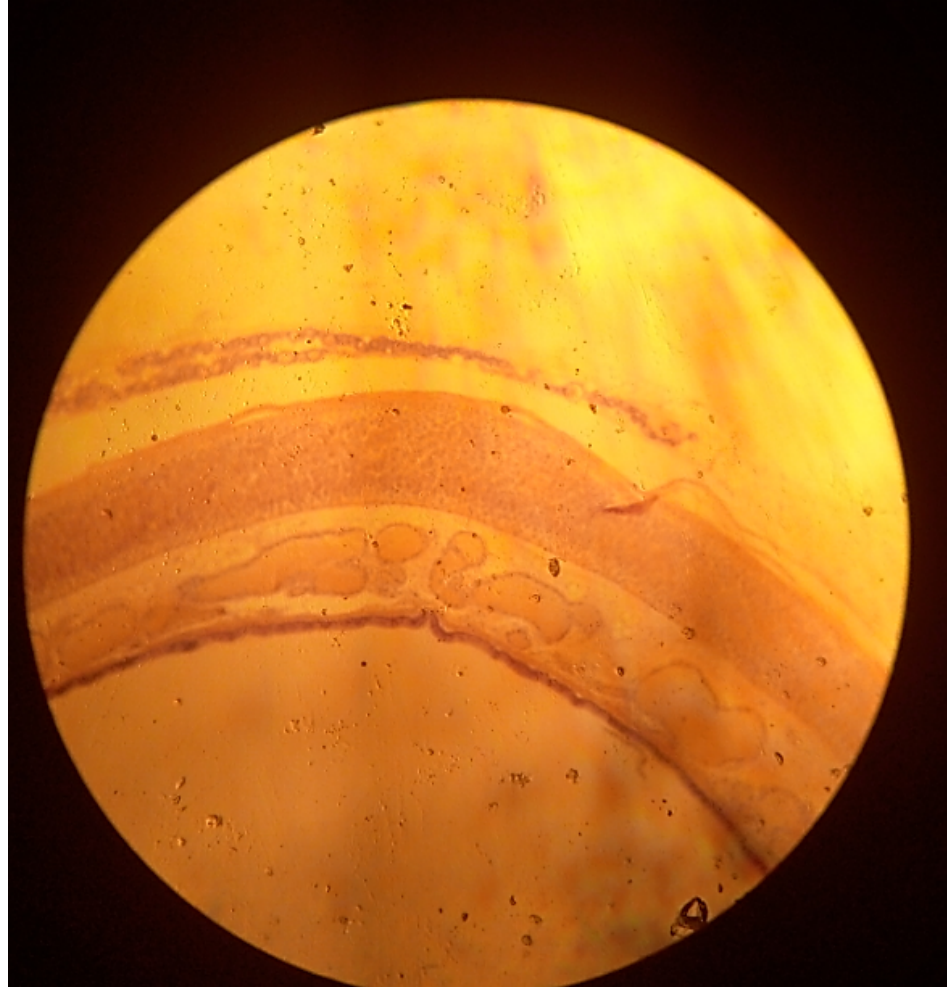
- Hp



# Practical lab 6

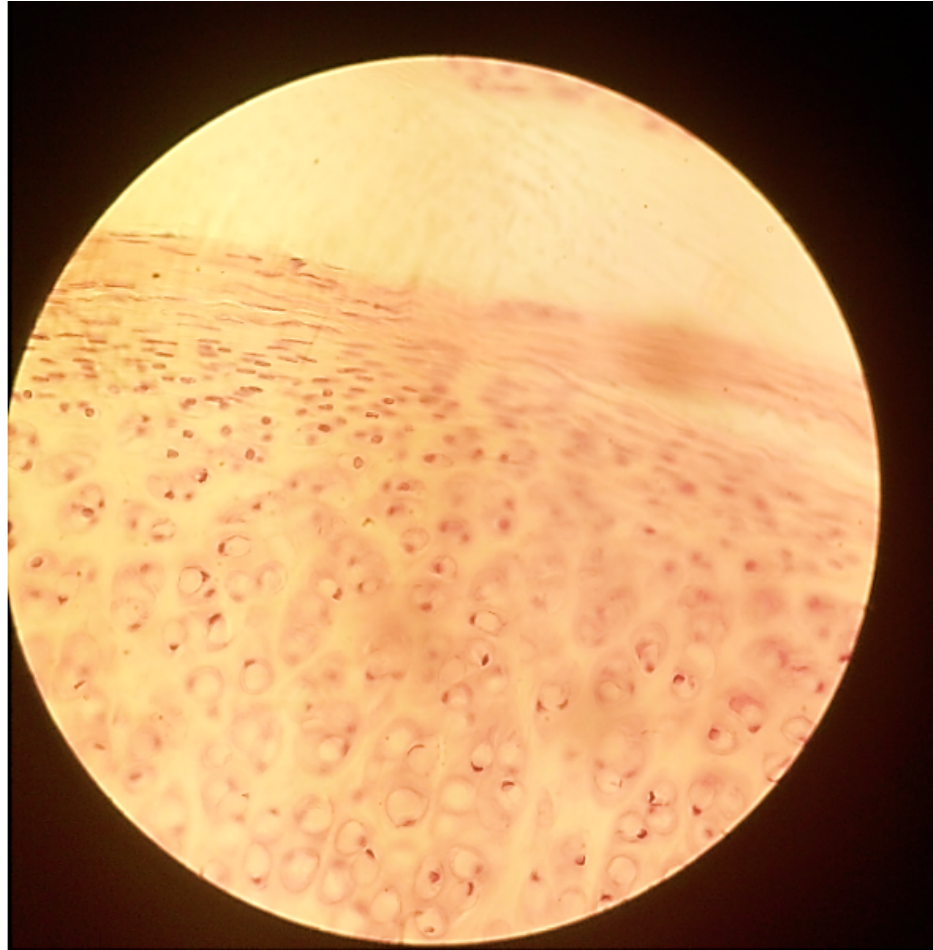
# cartilage

# Slide 72 Trachea (H&E) Lp



# Hyaline Cartilage: Slide 72 Trachea (H&E)

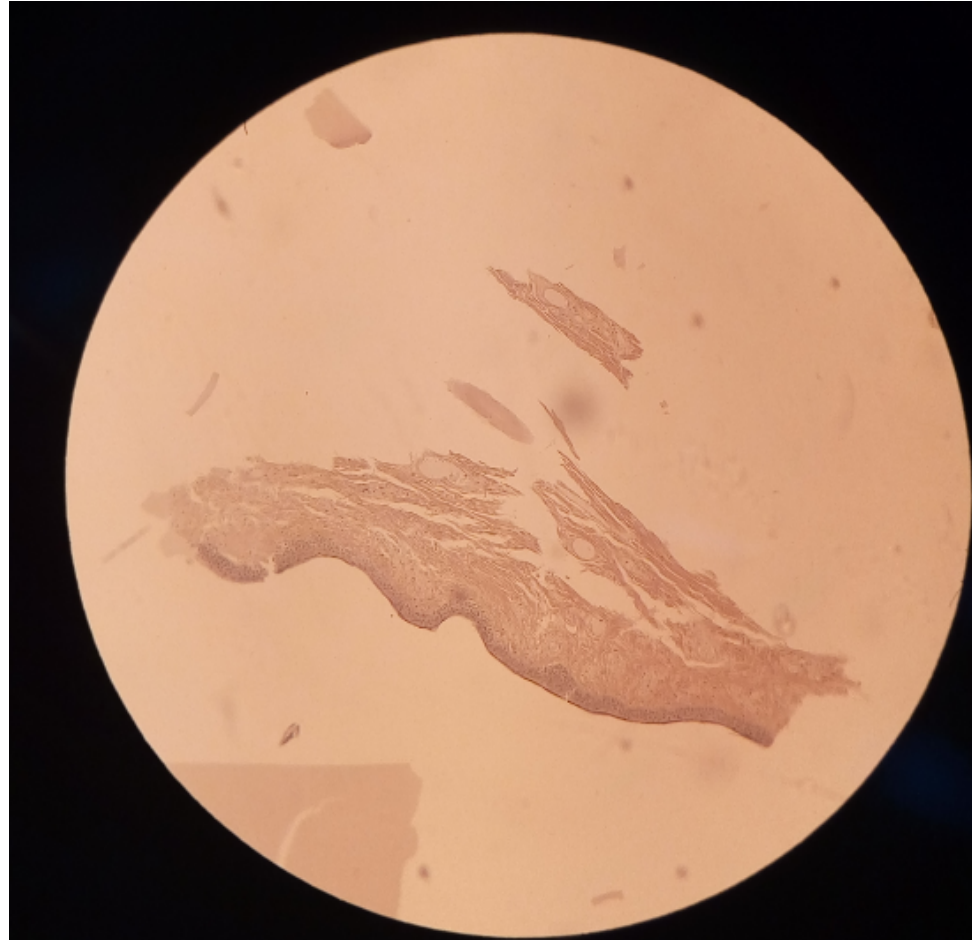
Hp



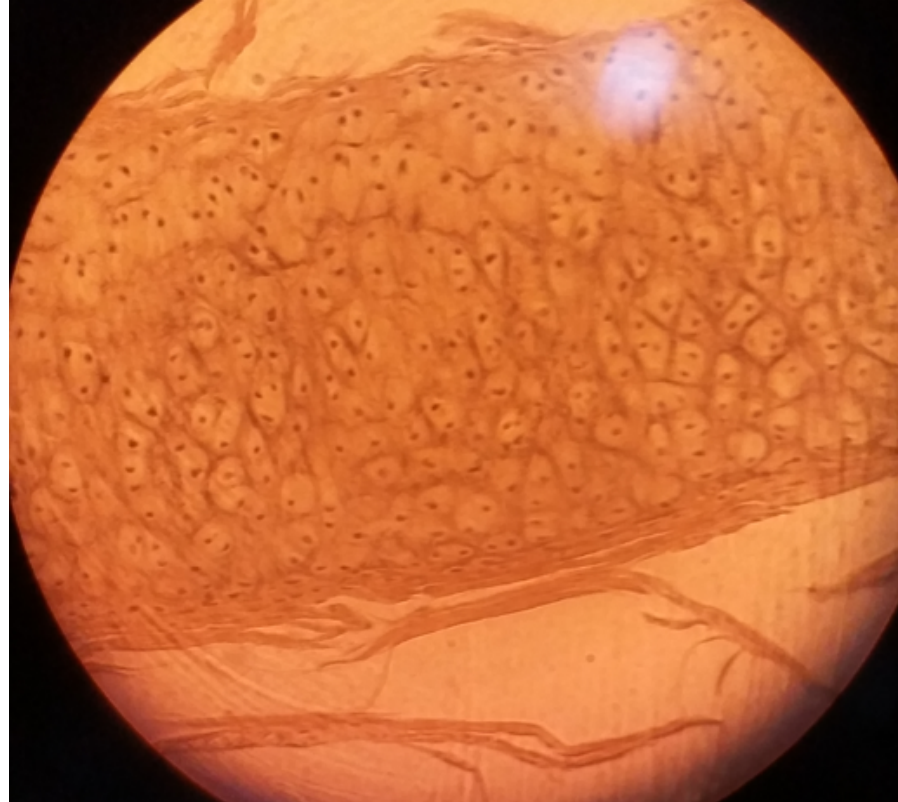
# ELASTIC Cartilage: Slide 4 External acoustic meatus (H&E)

Lp

• LP



# Elastic cartilage: Slide 4 External acoustic meatus (H&E) Hp



# Elastic cartilage: Slide 71 Larynx (H&E)

## Hb

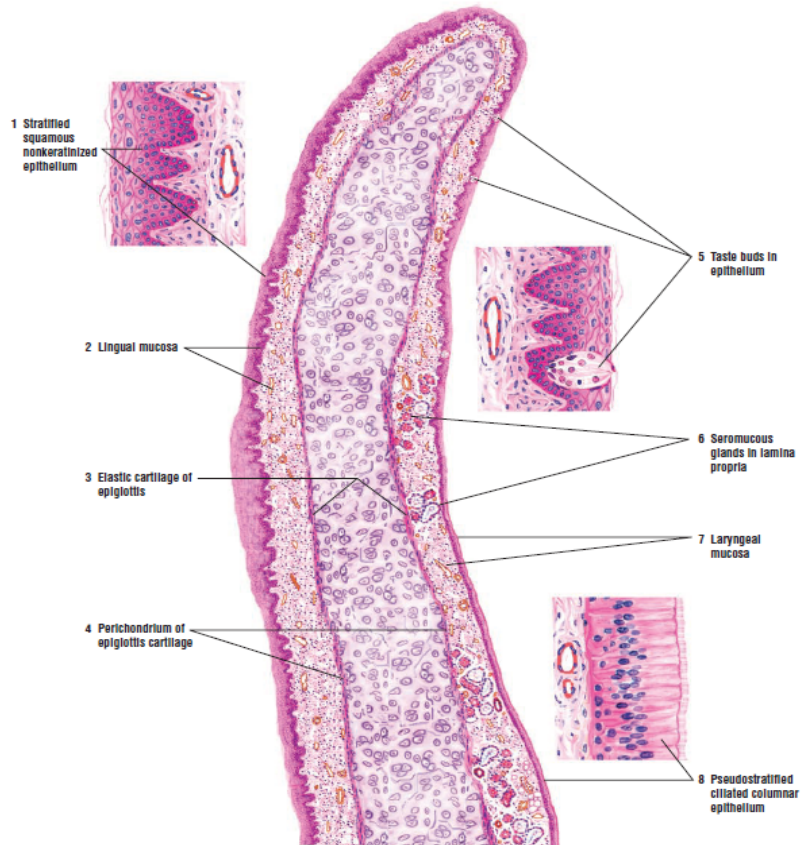


FIGURE 15.4 ■ Epiglottis (longitudinal section). Stain: hematoxylin and eosin. Low magnification. Insets: high magnification.

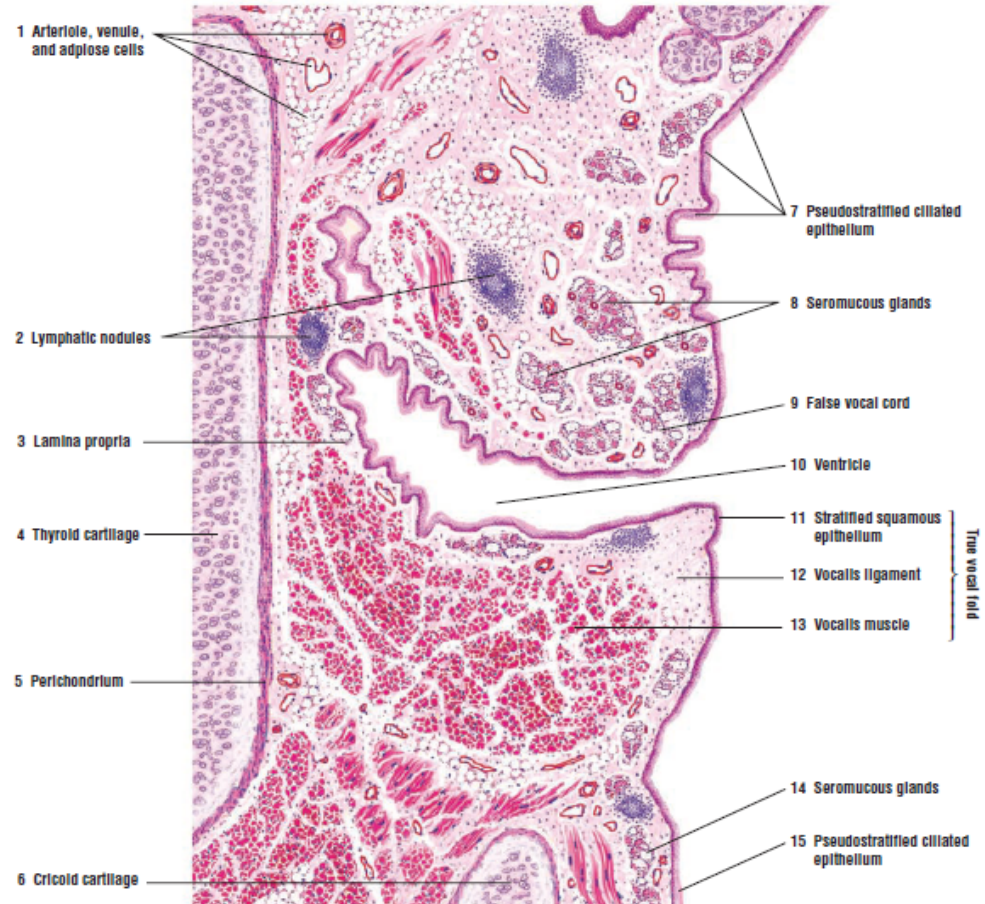
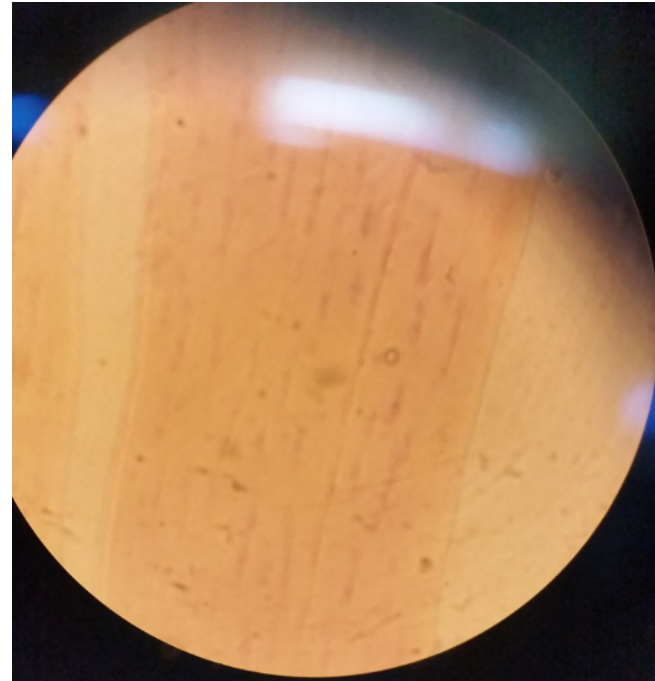
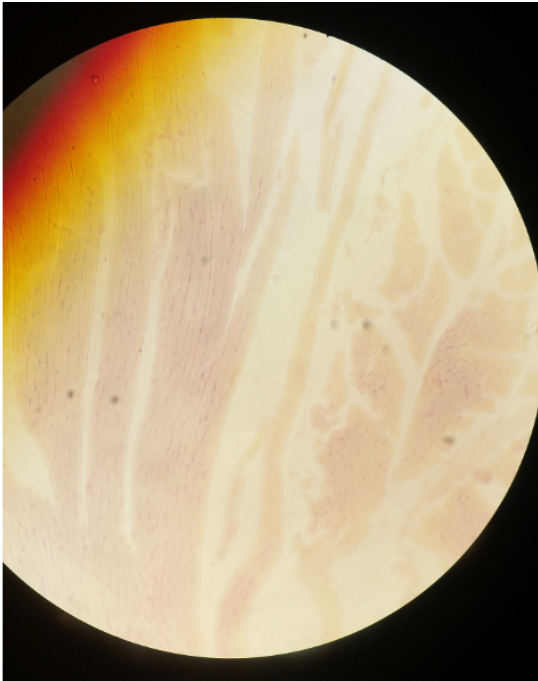
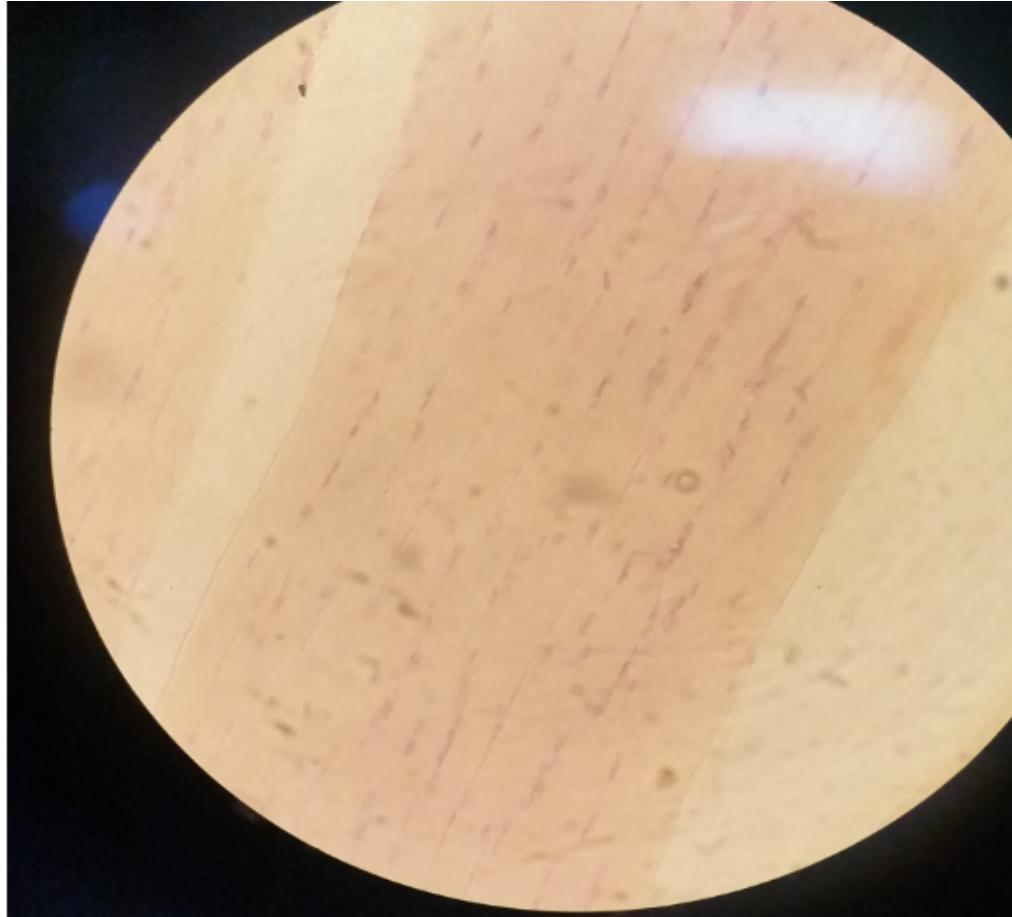


FIGURE 15.5 ■ Frontal section of larynx. Stain: hematoxylin and eosin. Low magnification.

# Fibrocartilage: Slide H2.63 Lp



# Fibrocartilage: Slide H2.63 Mp



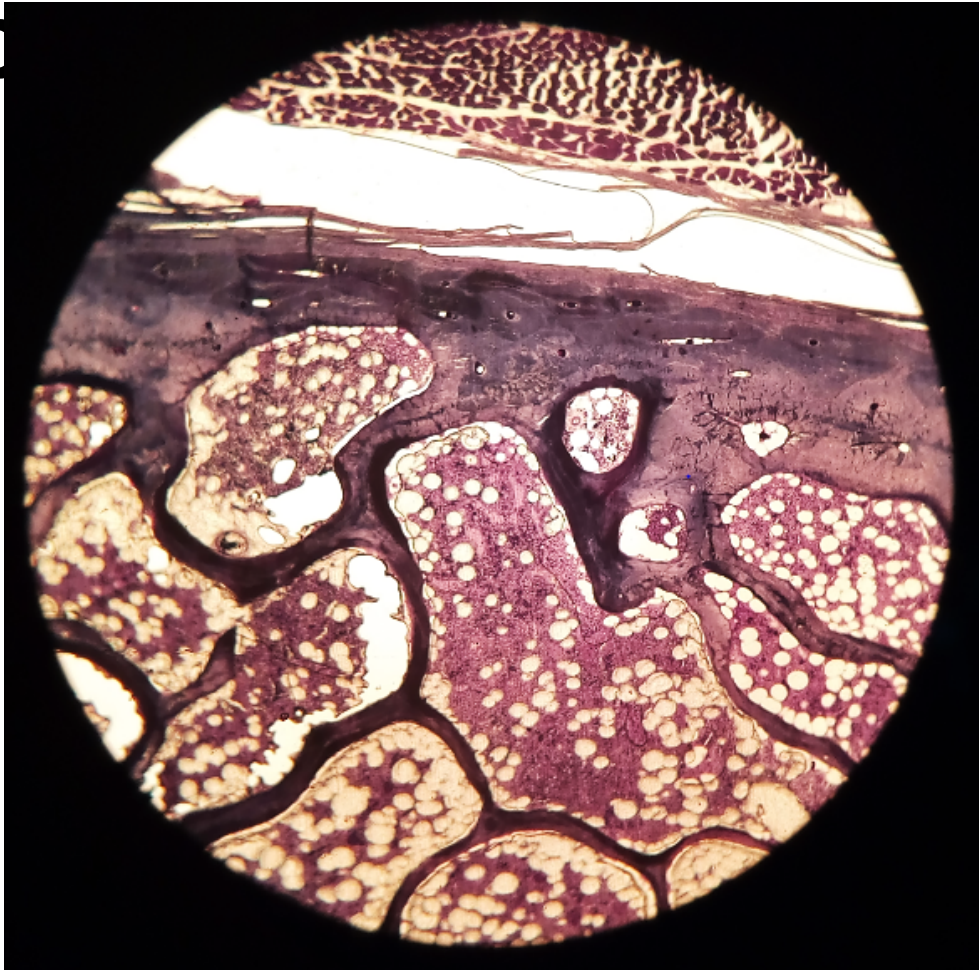
# Practical 7: Bone & Ossification

Presenter: J.Z.Sichela

# Compact and cancellous bone

slide 6: Rib Lp

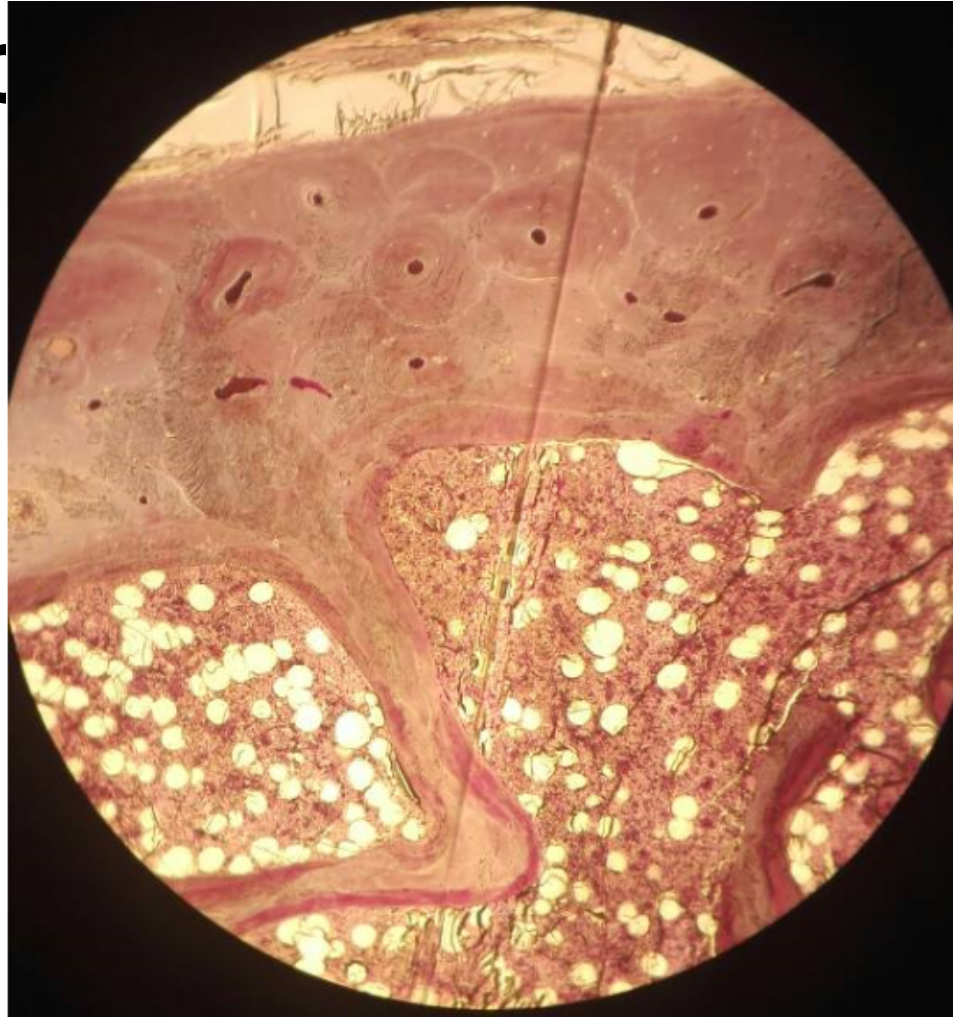Compact  
bone



# Compact and cancellous bone

slide 6: Rib Mp

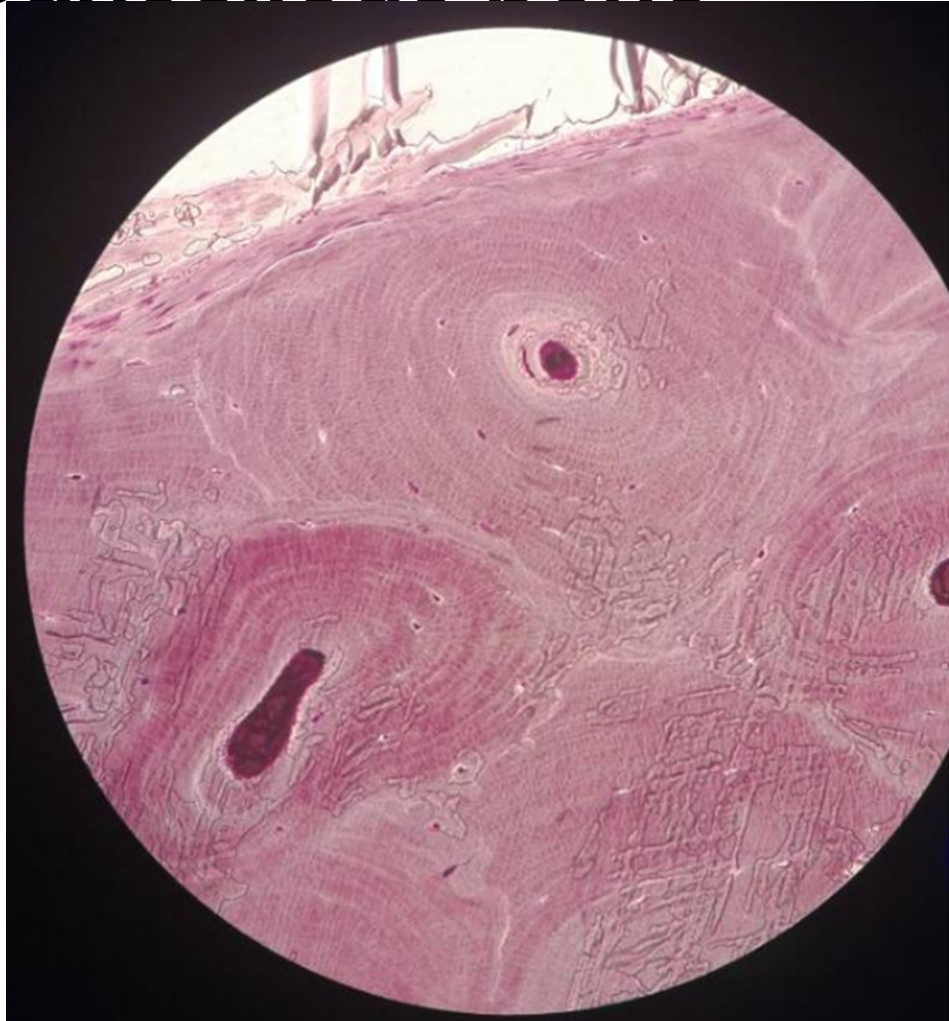Compact bone



# Compact and cancellous bone

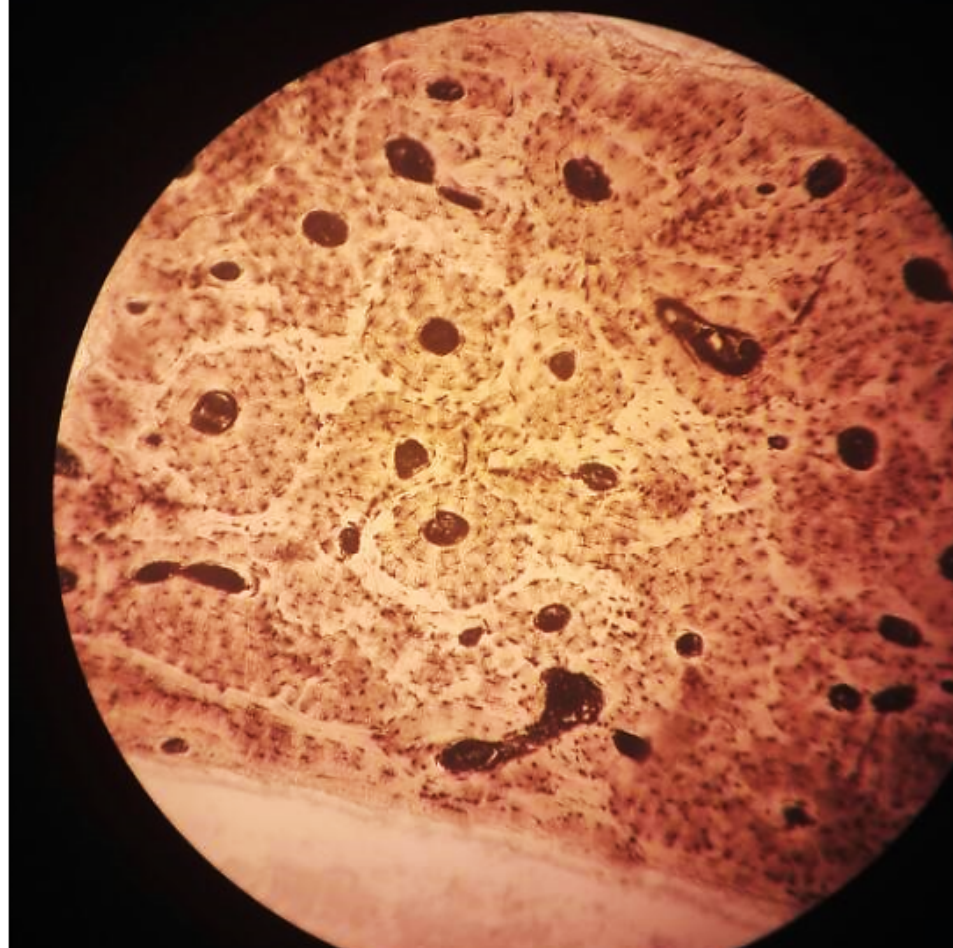
## slide 6: Rib Hp

Compact  
bone



# Compact and cancellous bone slide H2.74: Lp


Ground Bone



# Compact and cancellous bone

slide H2.74: H

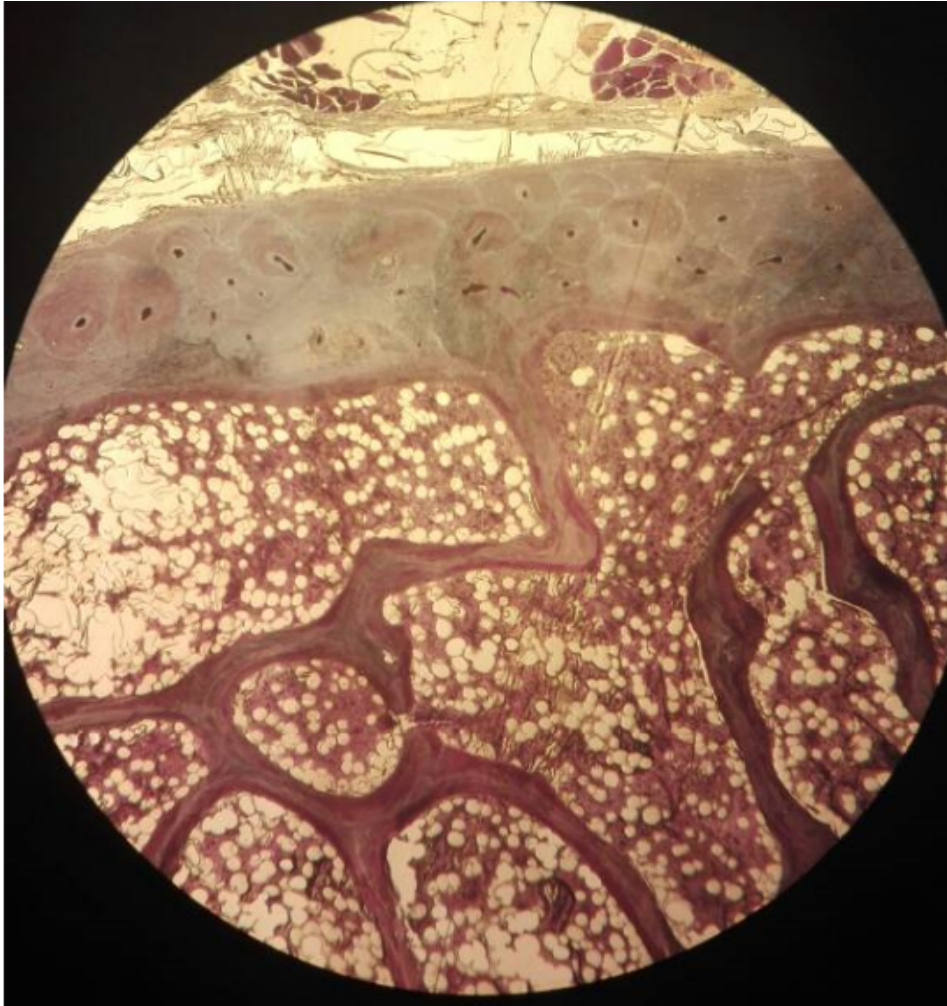
Ground Bone



# Compact and cancellous bone

slide 6: Rib Lp

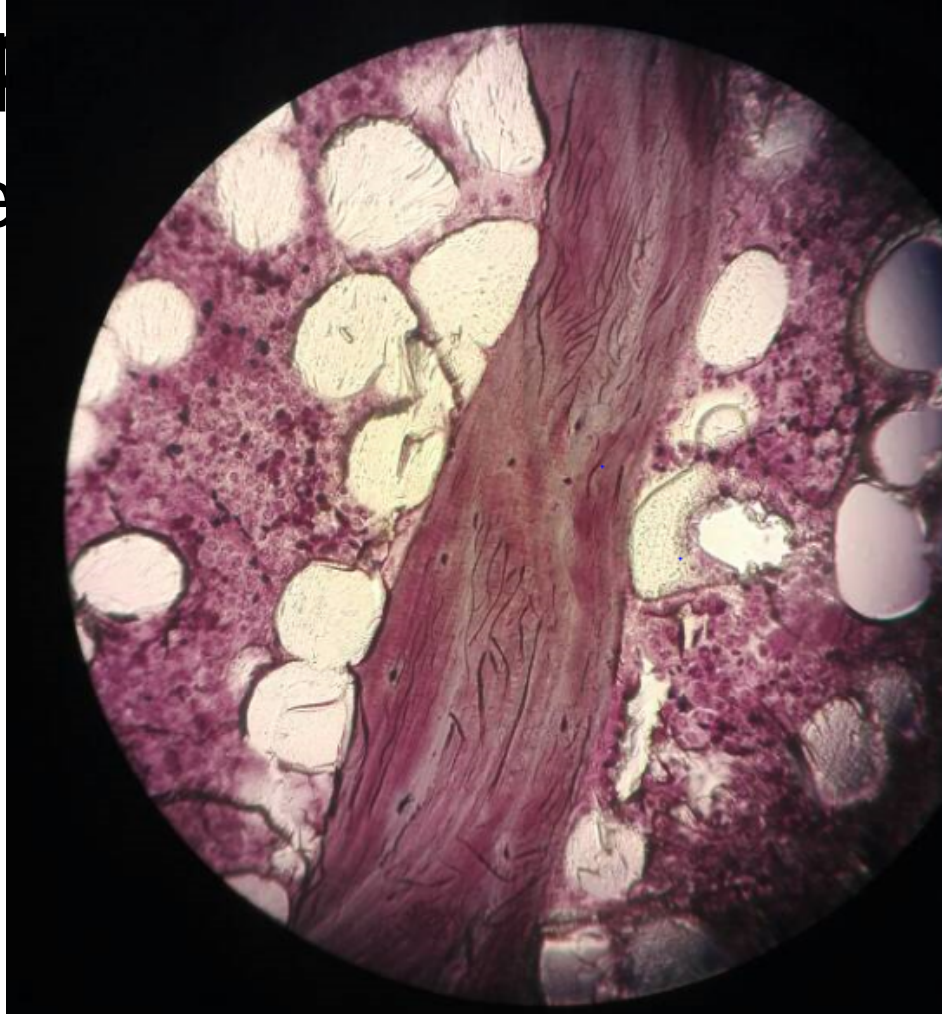Cancellous bone



# Compact and cancellous bone

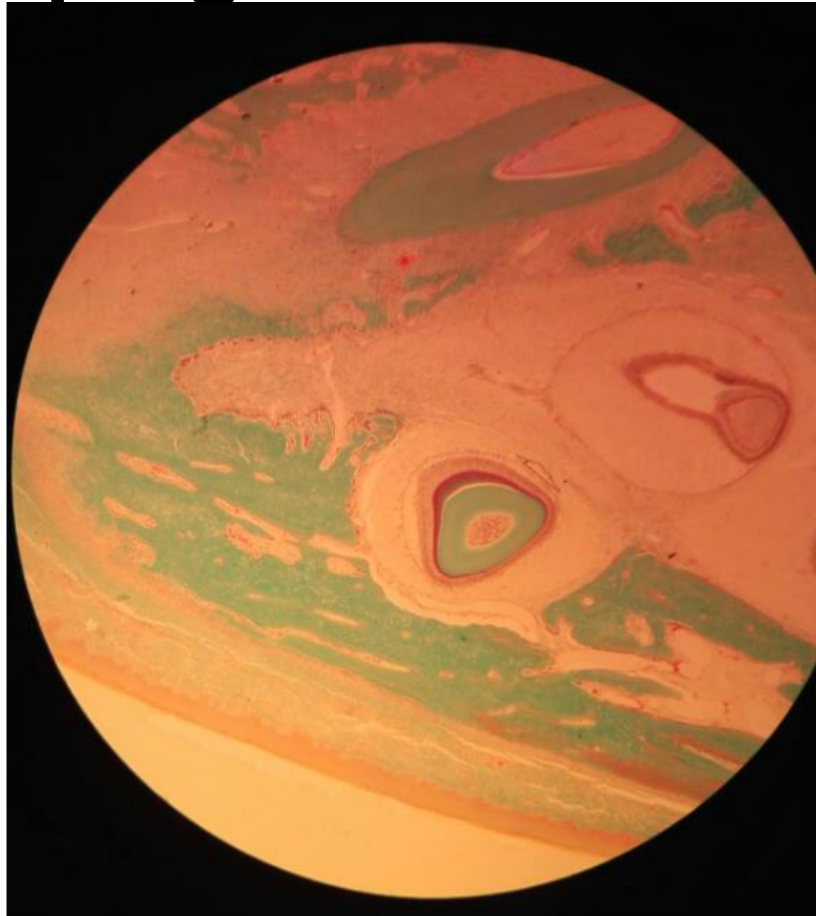
slide 6: Rib H&E

Cancellous bone



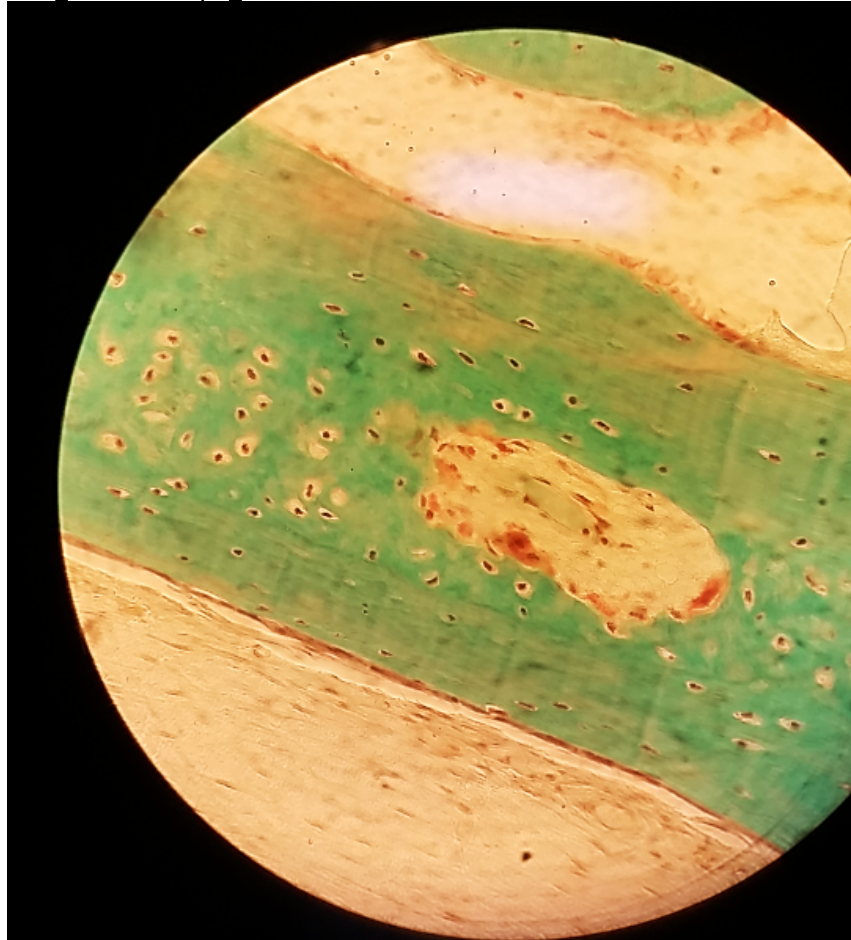
# Intramembranous calcification slide 50: Developing Tooth

Lp

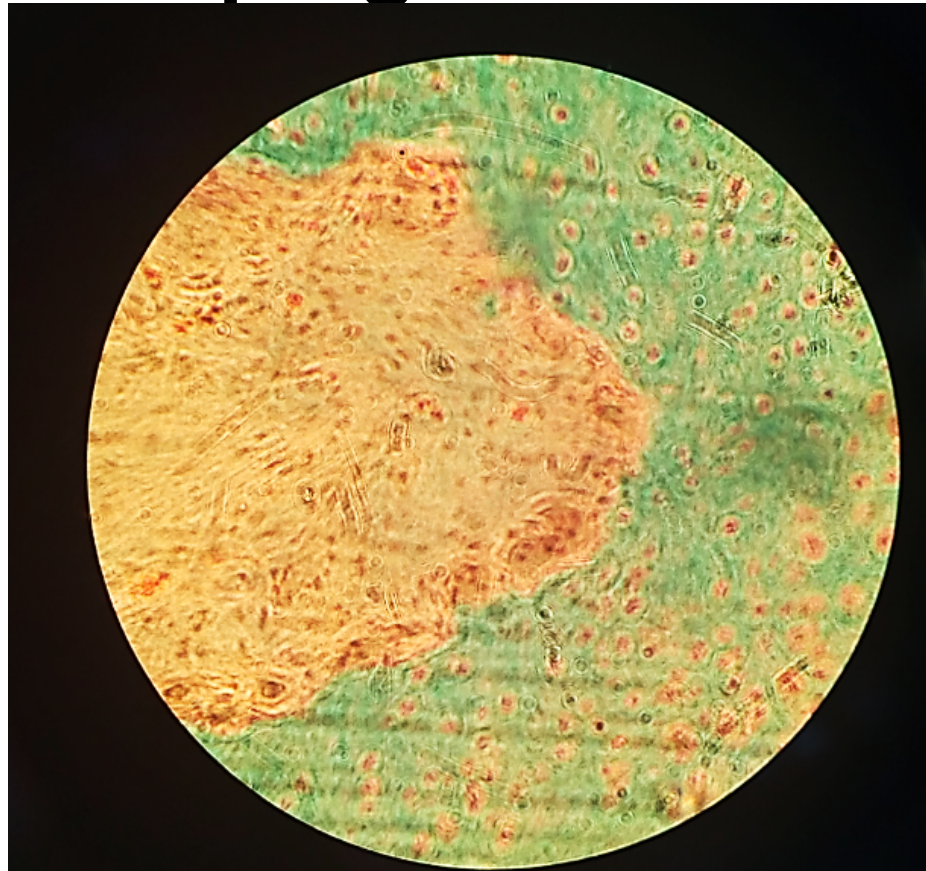


# Intramembranous calcification slide 50: Developing Tooth

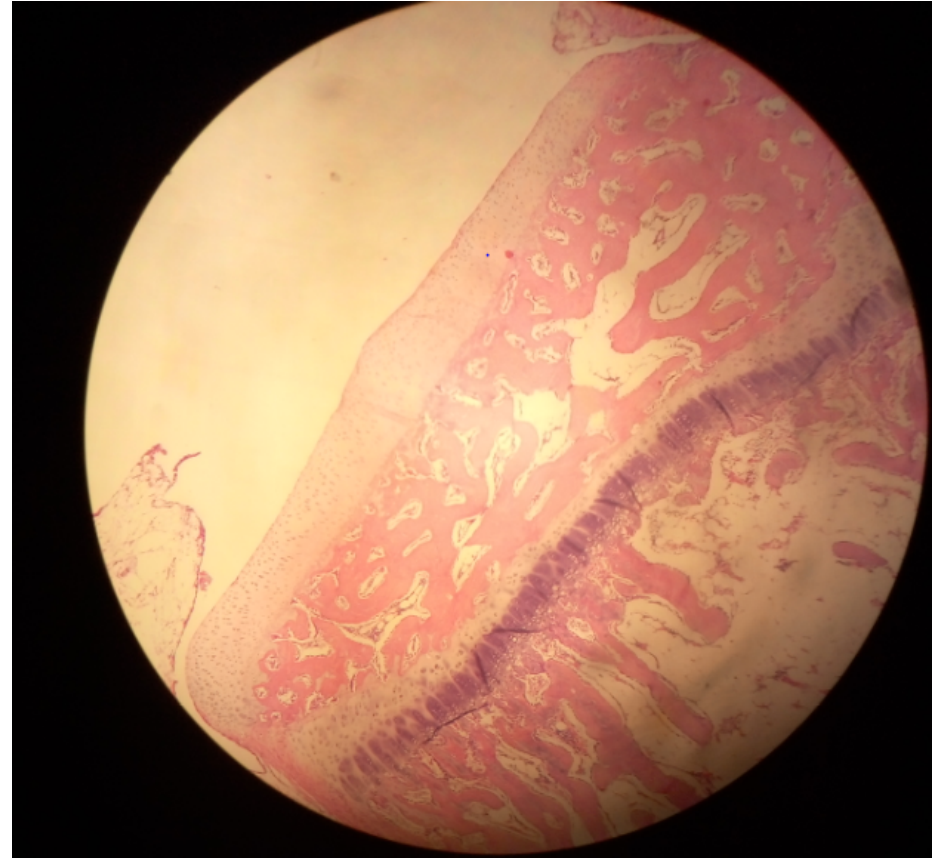
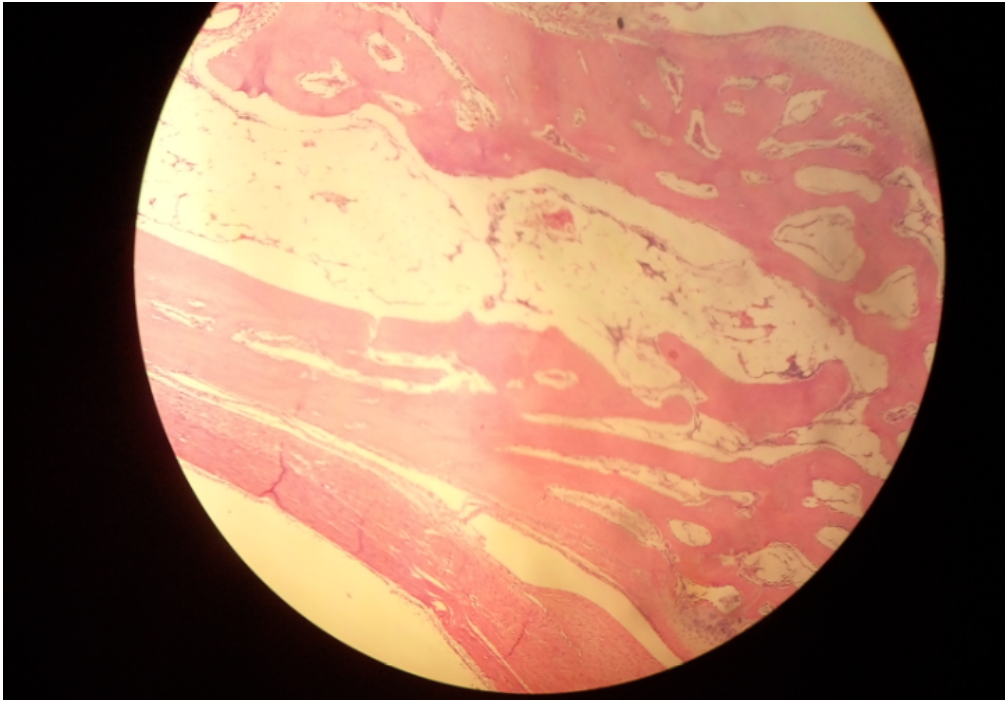
Hp



# Intramembranous calcification slide 50: Developing Tooth

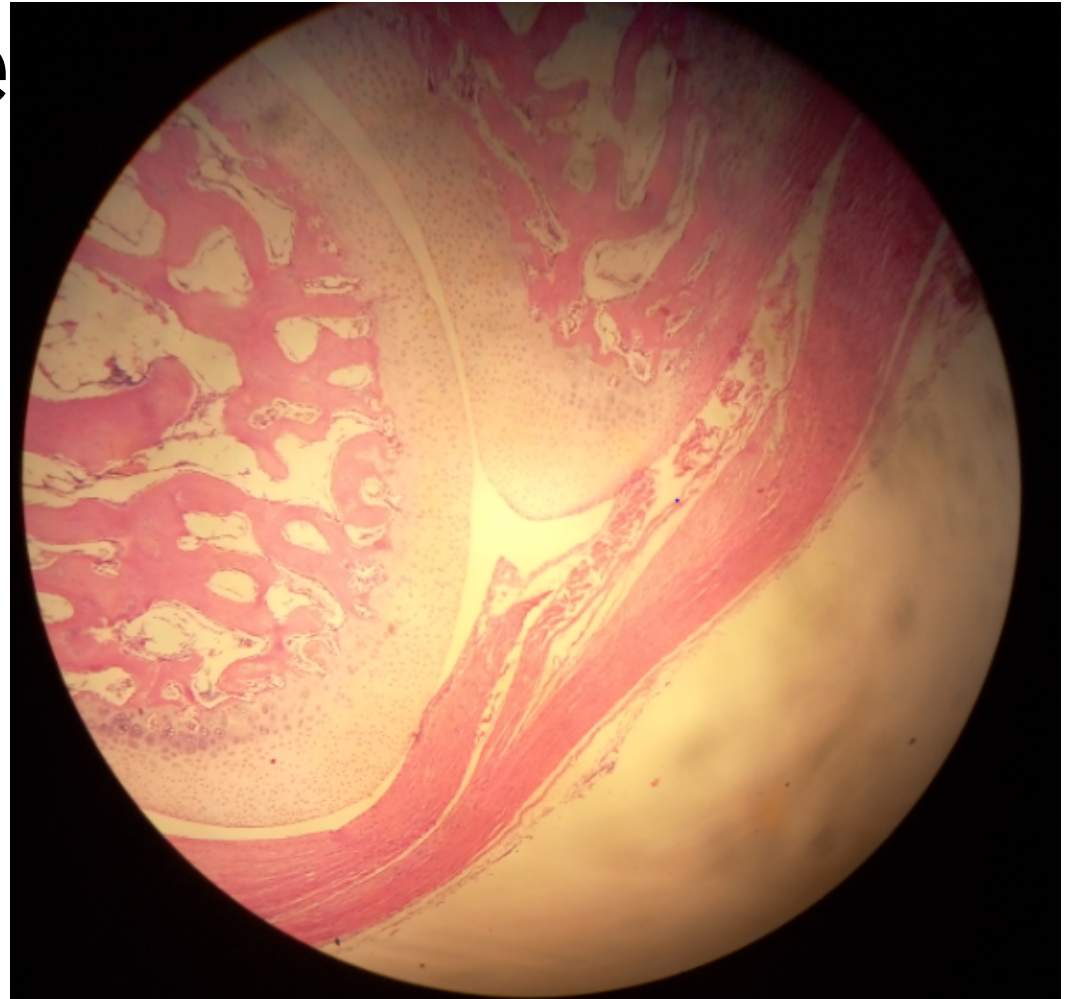
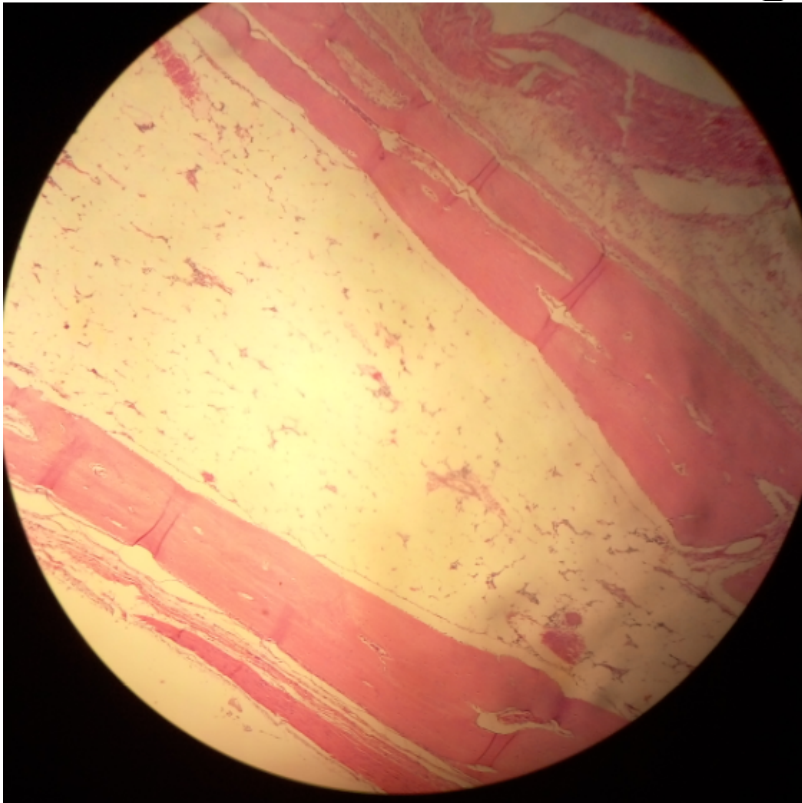


# Endochondral ossification slide 7: Fetal Finger



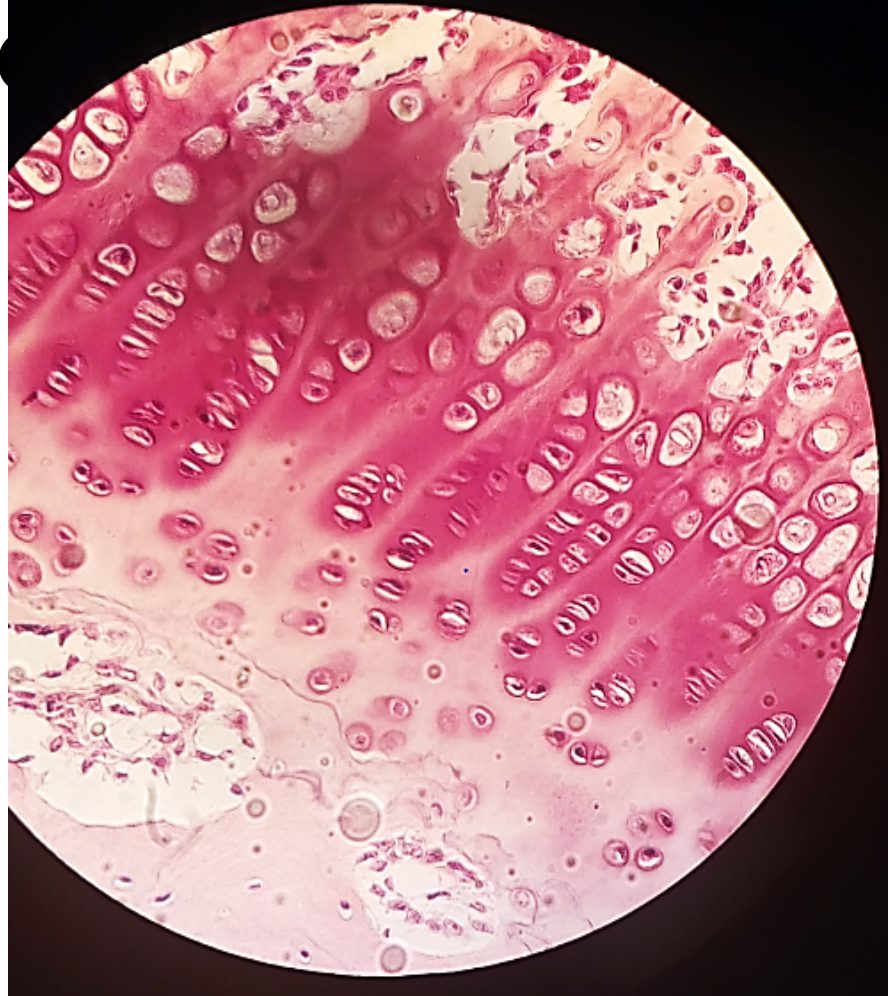
# Endochondral ossification

## slide 7: Fetal Finge



# Endochondral ossification

## slide 7: Fetal Fing



# **Epiphyseal plate**

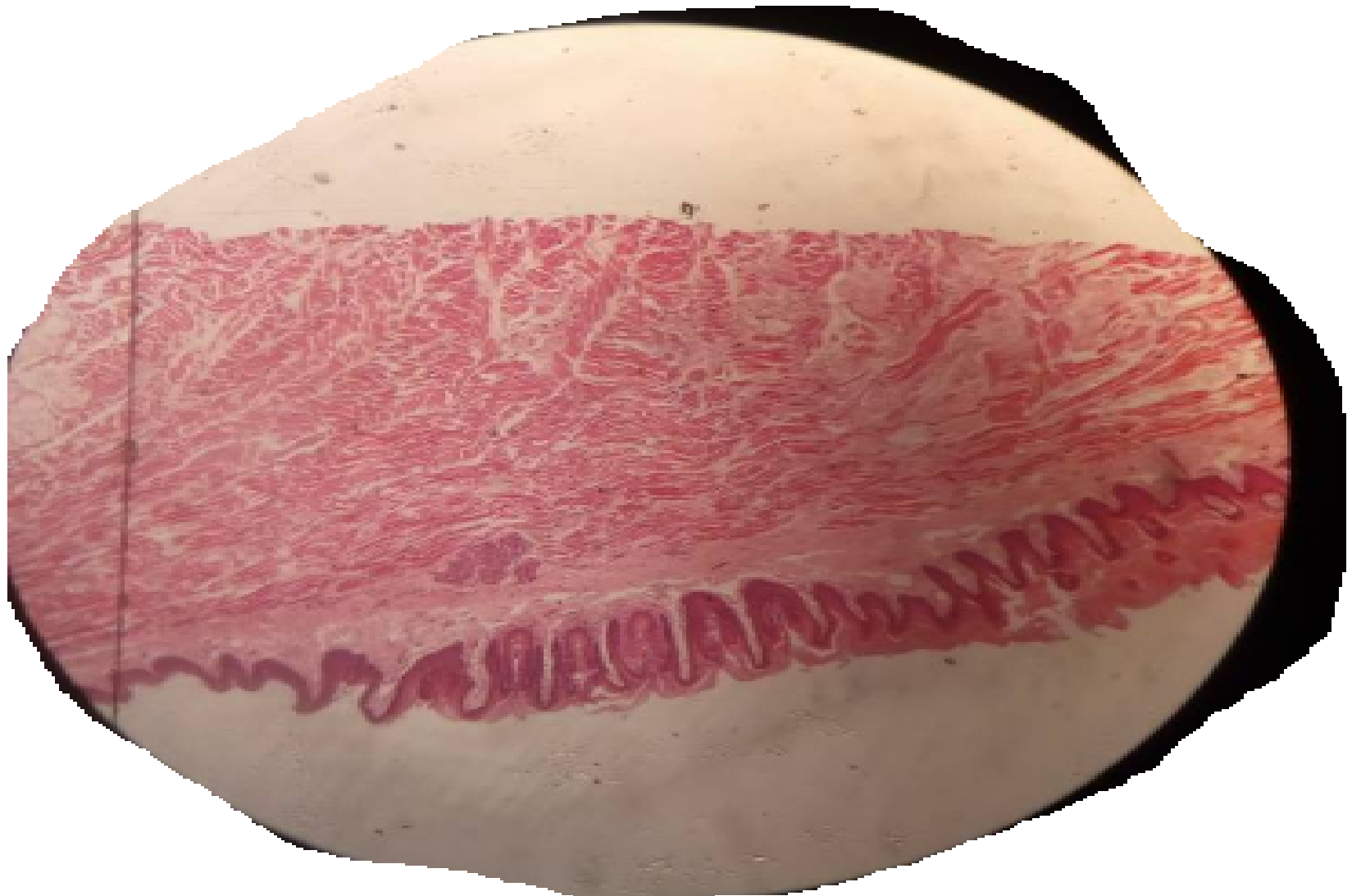## **slide 8: Femur, Epiphyseal Disc**

# LAB 9

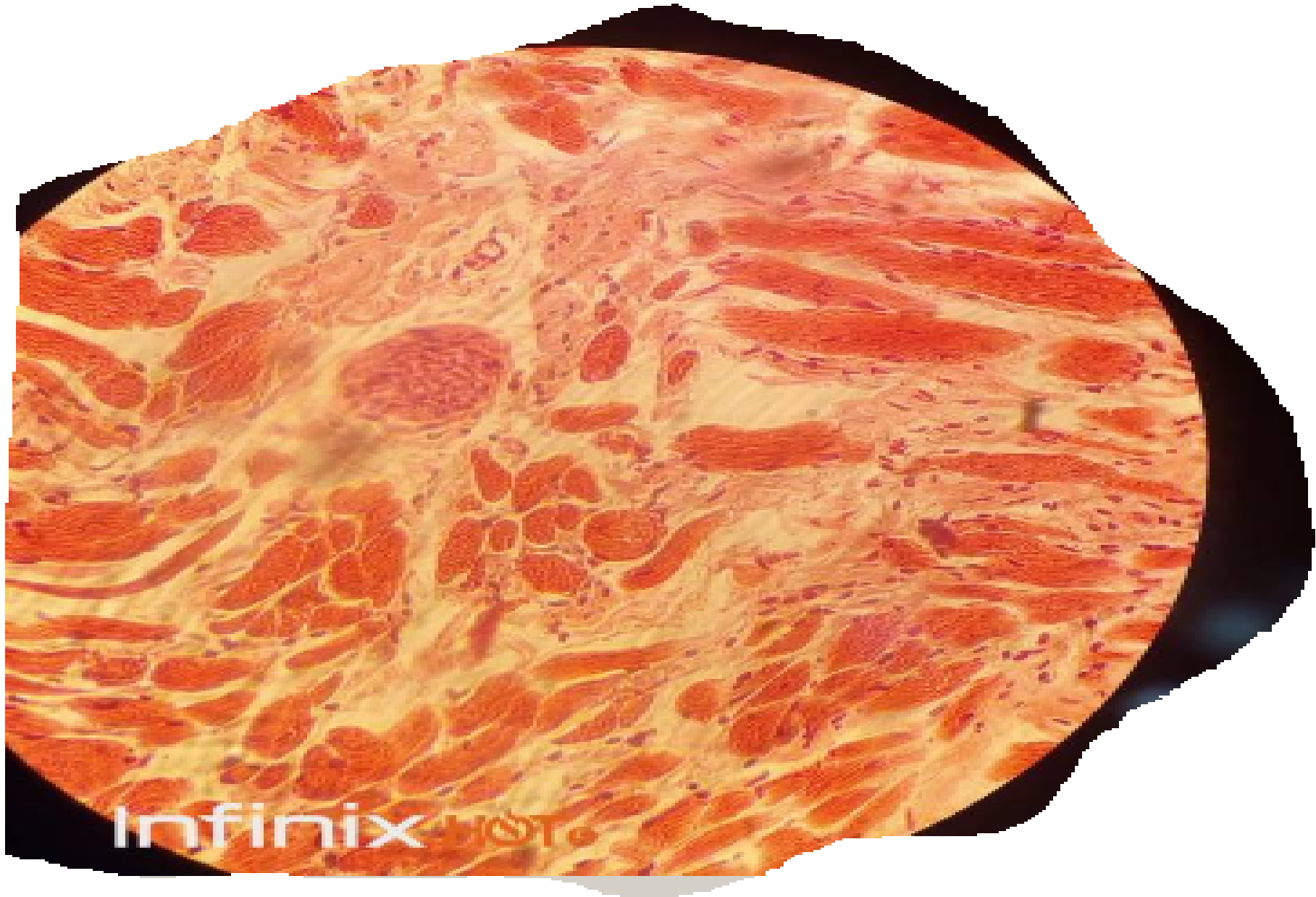## MUSCLE TISSUE

# 1. STRIATED SKELETAL MUSCLE

- SLIDE 43 ROOT OF THE TONGUE/LP



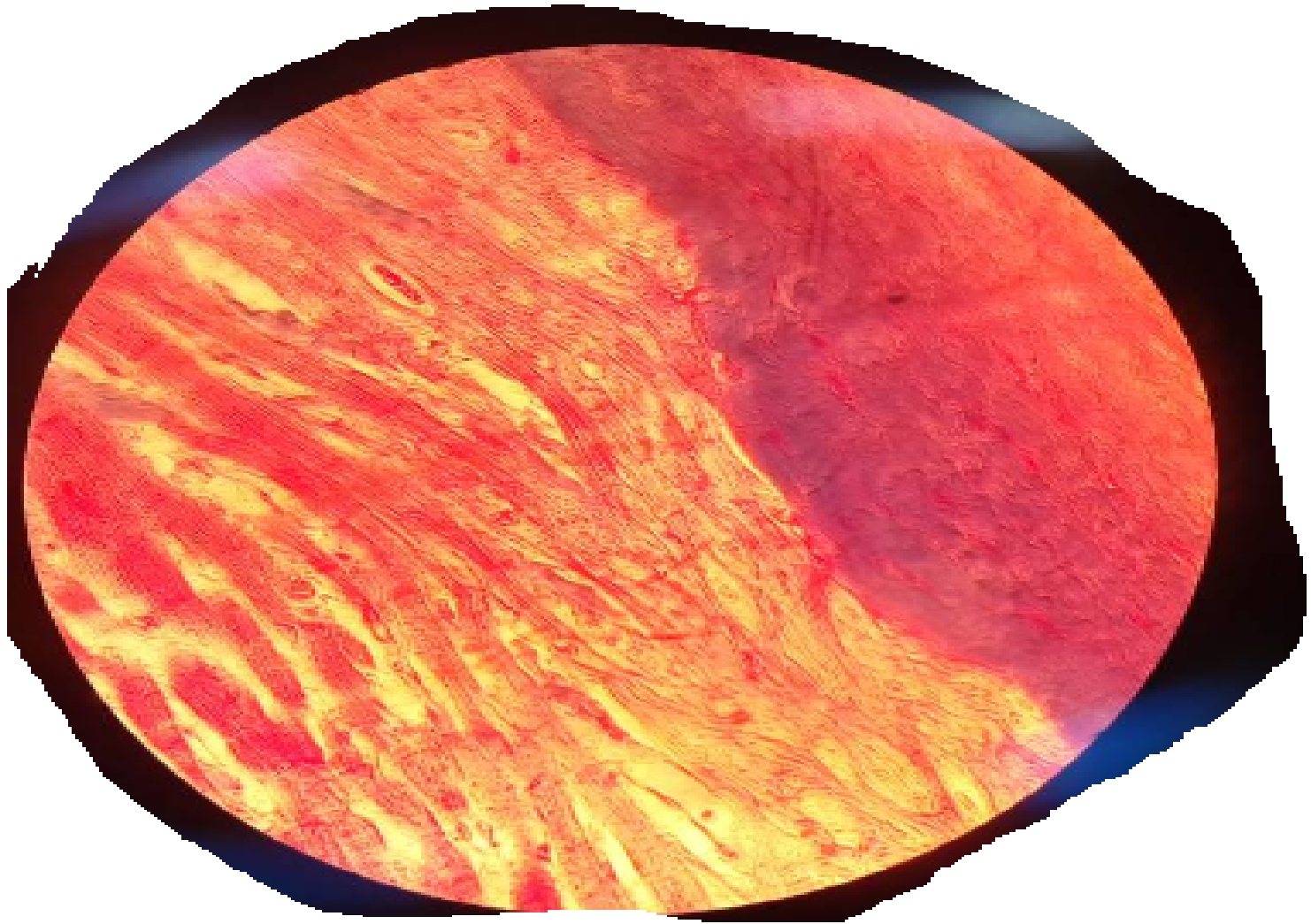
# ROOT OF THE TONGUE/HP



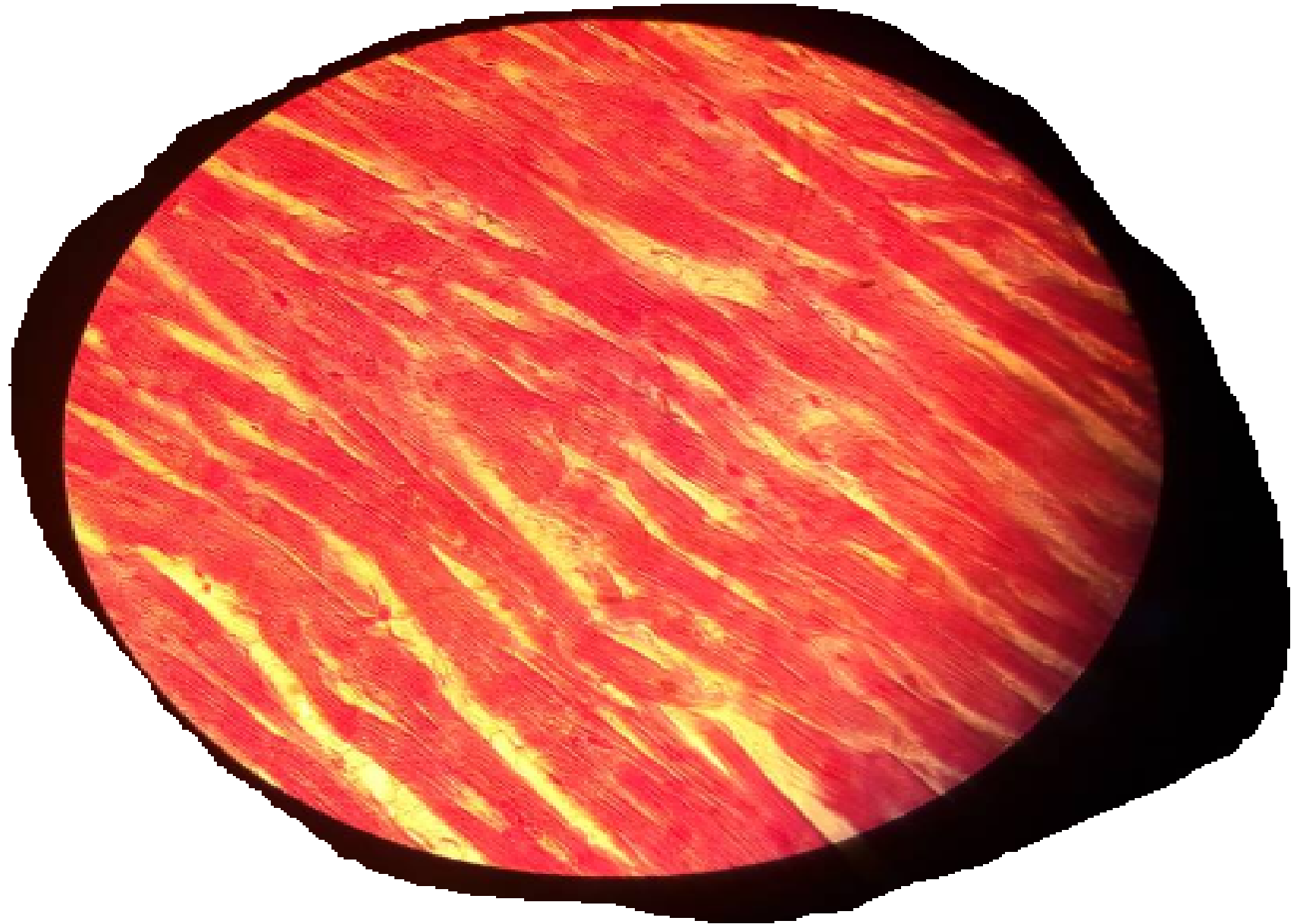
Infinix HISTO

## 2. CARDIAC MUSCLE

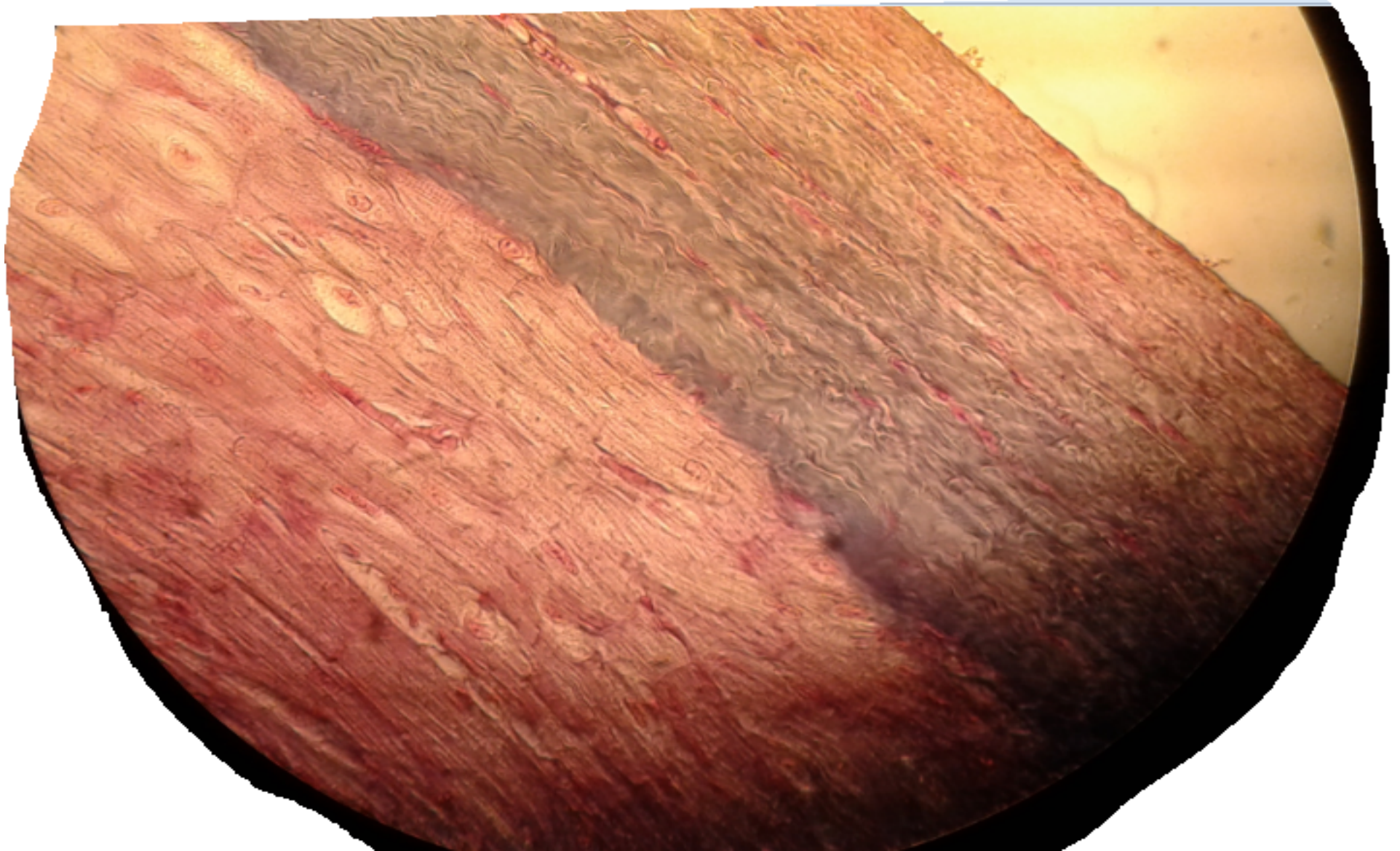
- SLIDE 25 HEART(MALLORY)/LP



# SLIDE 25 HEART(MALLORY)/LH

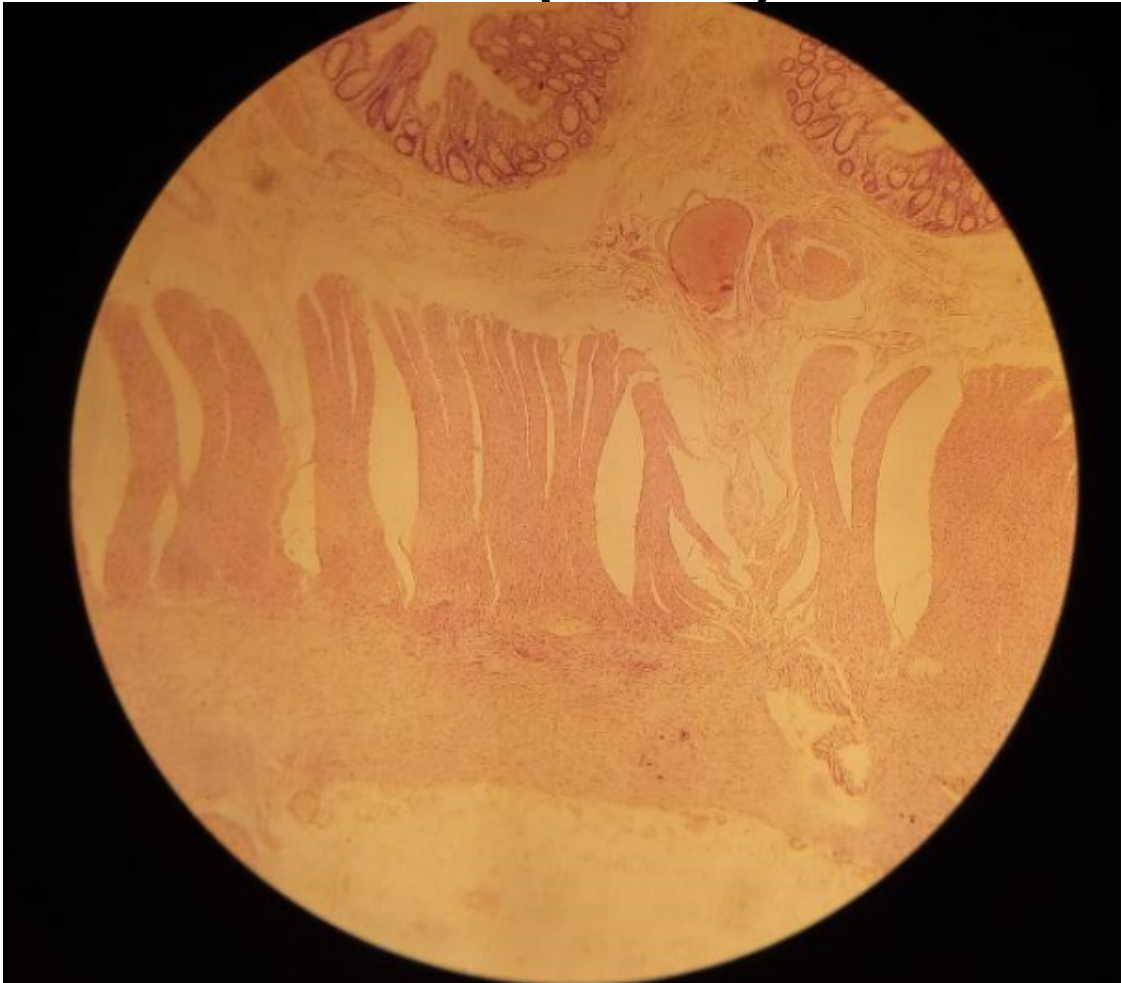


### 3. PURKINJE FIBRES /HP

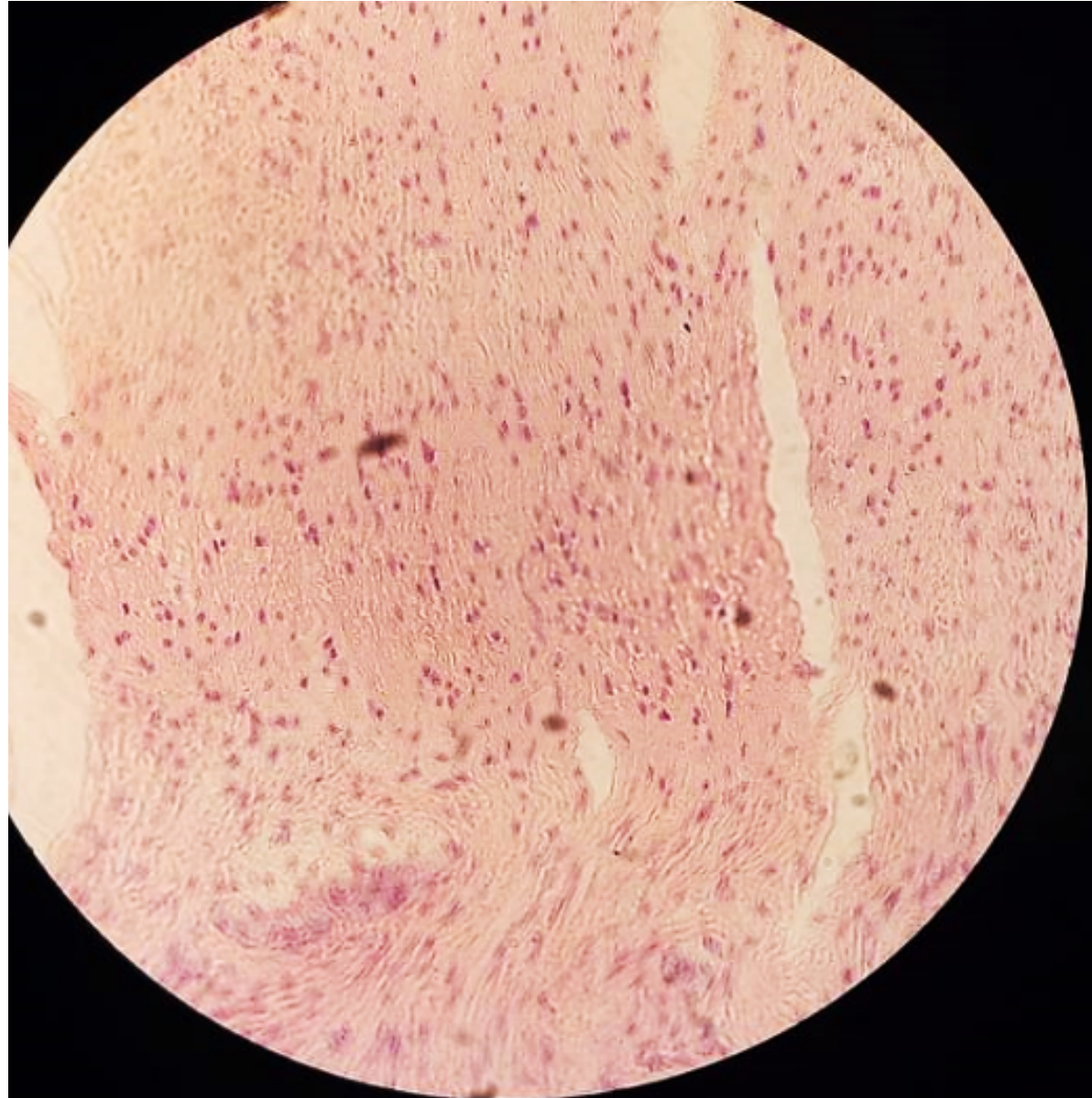


# 4. SMOOTH MUSCLE

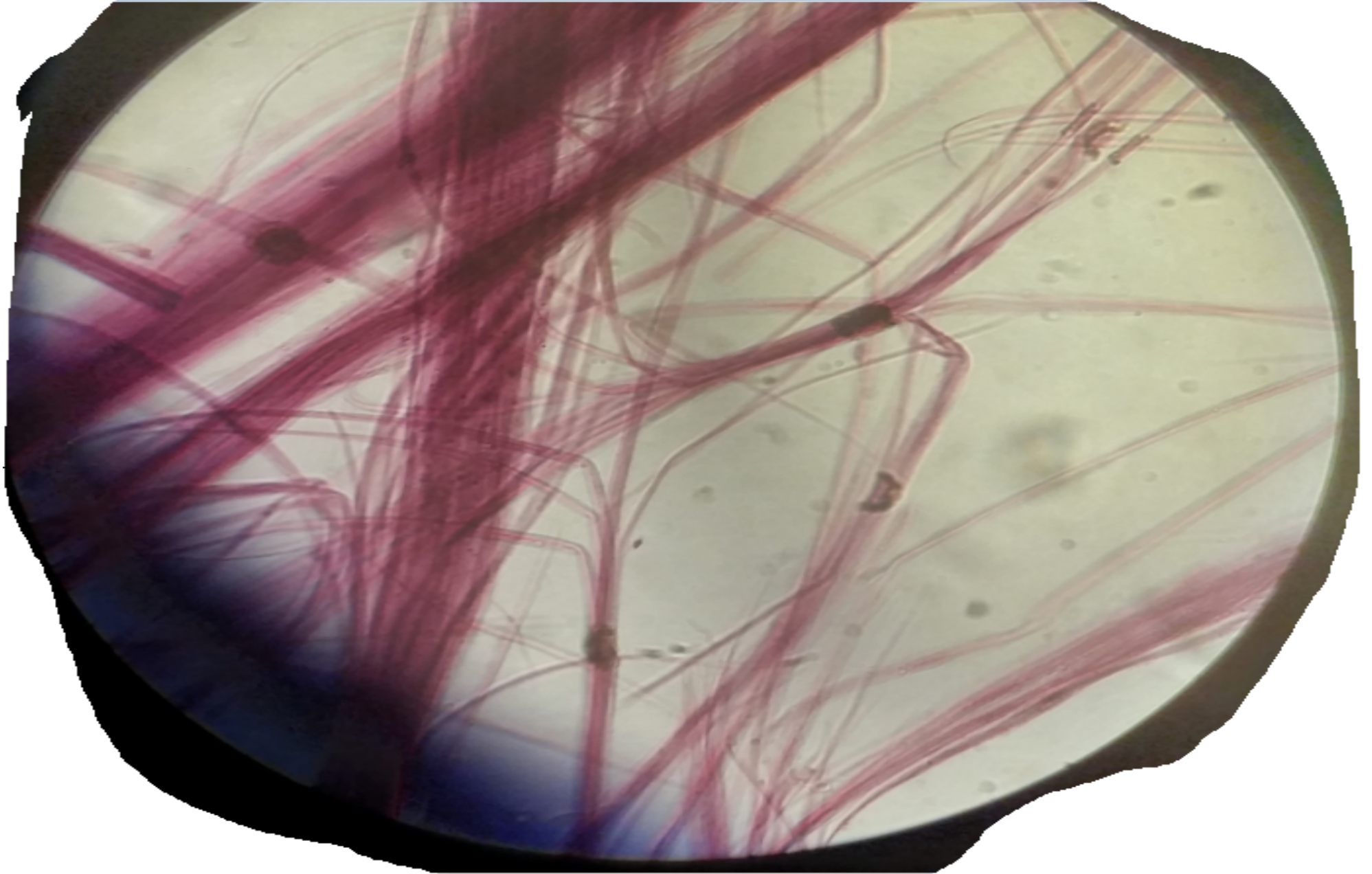
- SLIDE 53 COLON(HAB)



# COLON HP

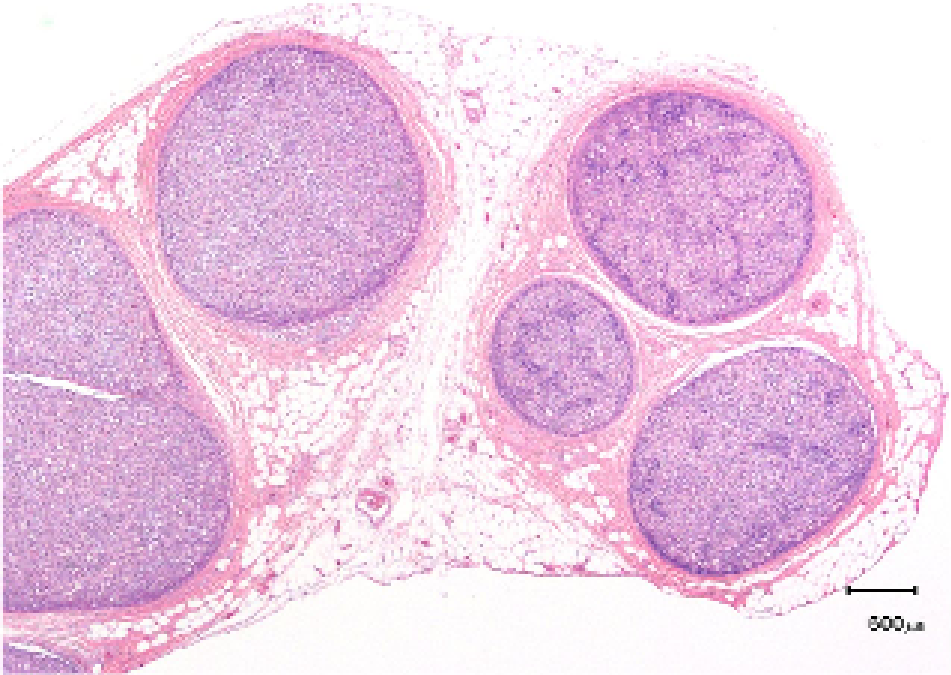


# SLIDE H3.21 TEASED SMOOTH MUSCLE

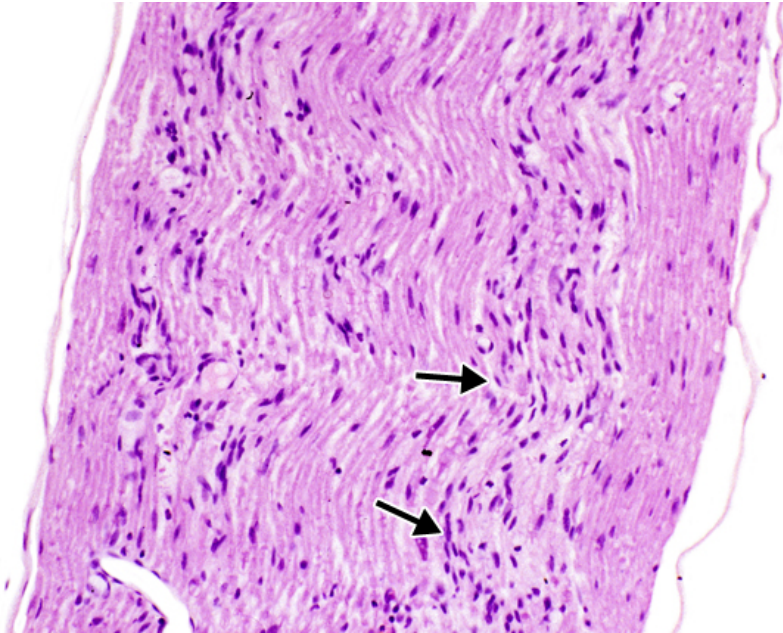


# PRACTICAL 10: NERVE TISSUE

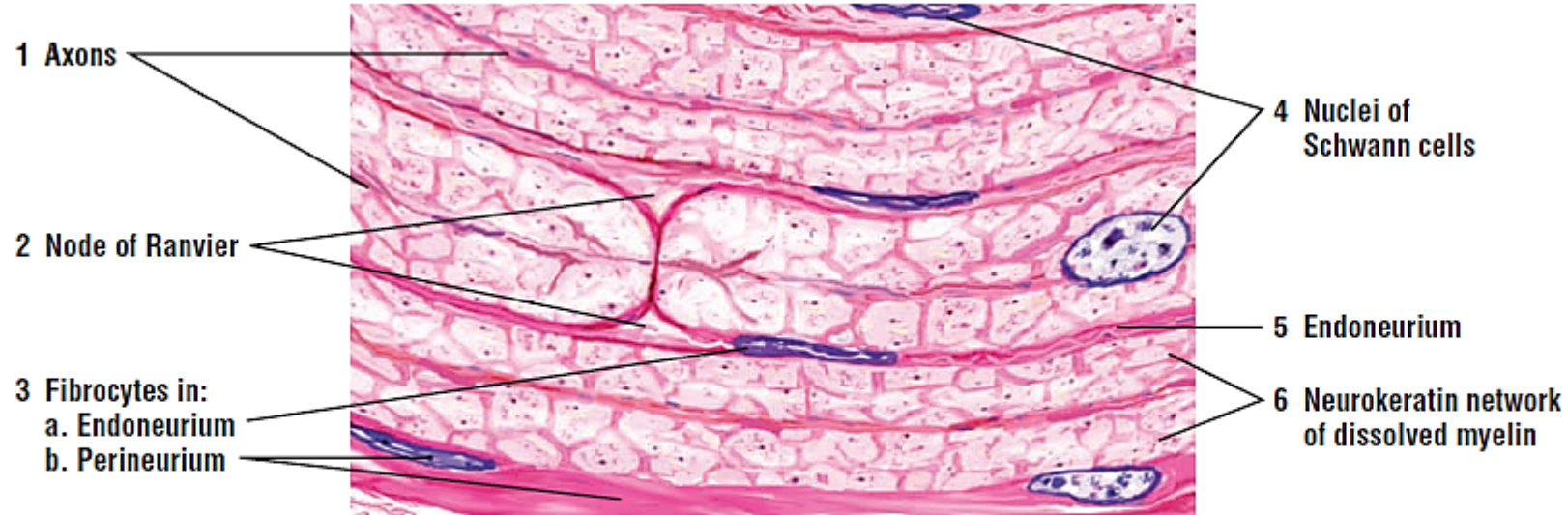
# Slide 13 TS & LS Sciatic Nerve (H&E) LP



8

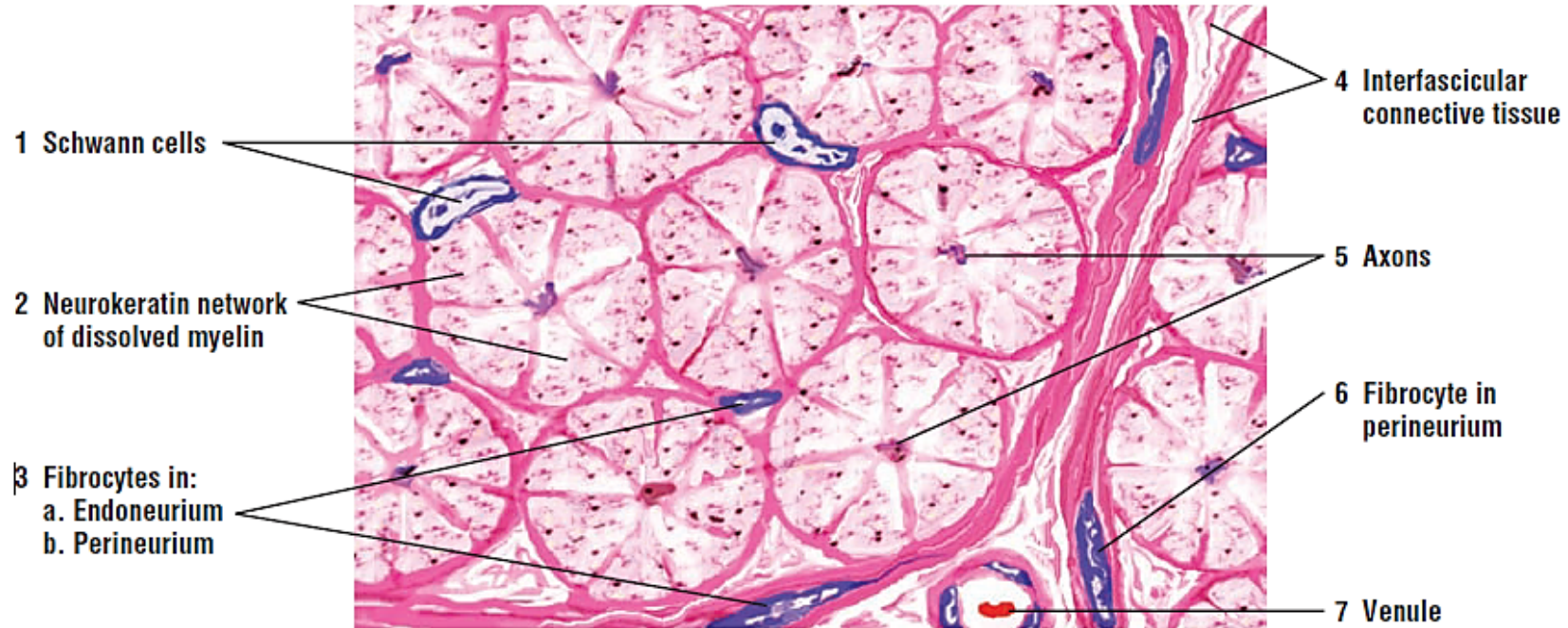


# Slide 13 TS & LS Sciatic Nerve (H&E) HP



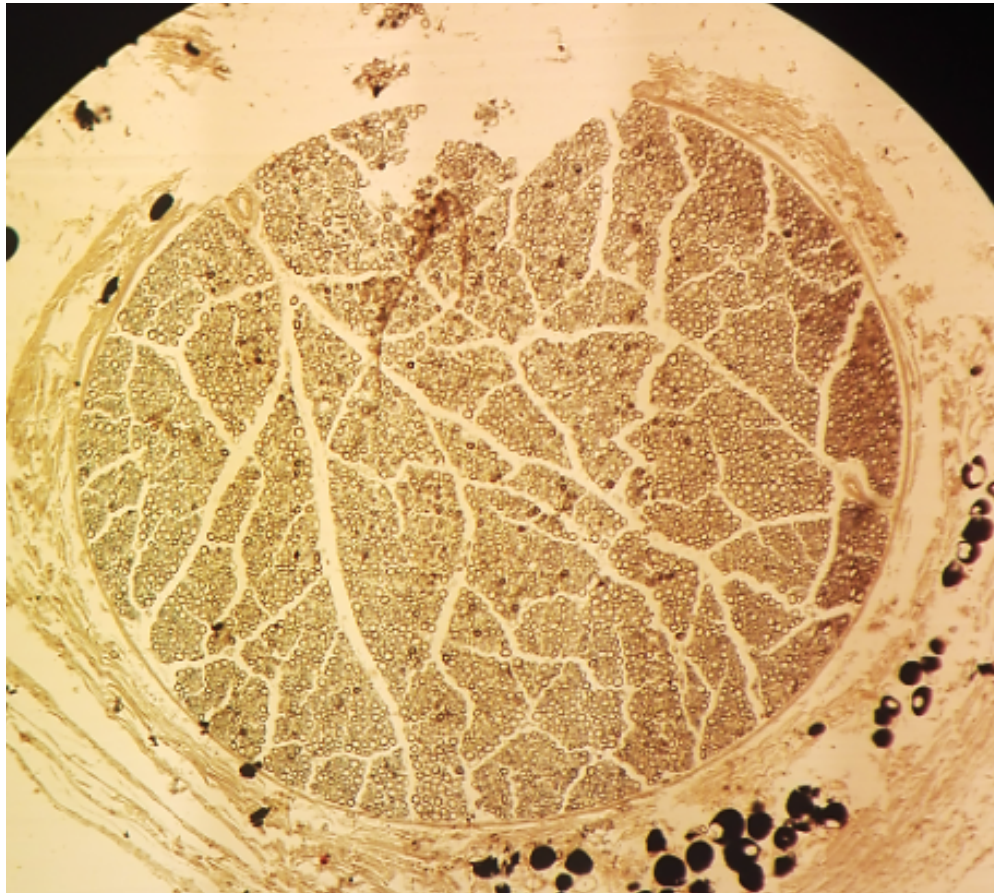
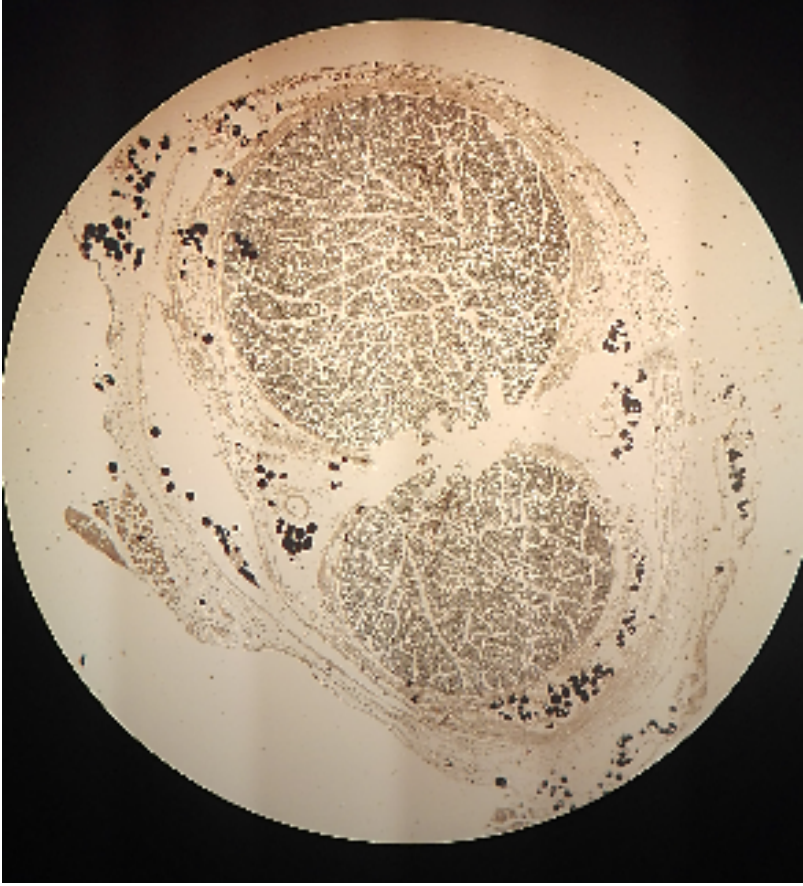
**FIGURE 7.18** ■ Sciatic nerve (longitudinal section). Stain: hematoxylin and eosin. High magnification (oil immersion).

# Slide 13 TS & LS Sciatic Nerve (H&E) HP

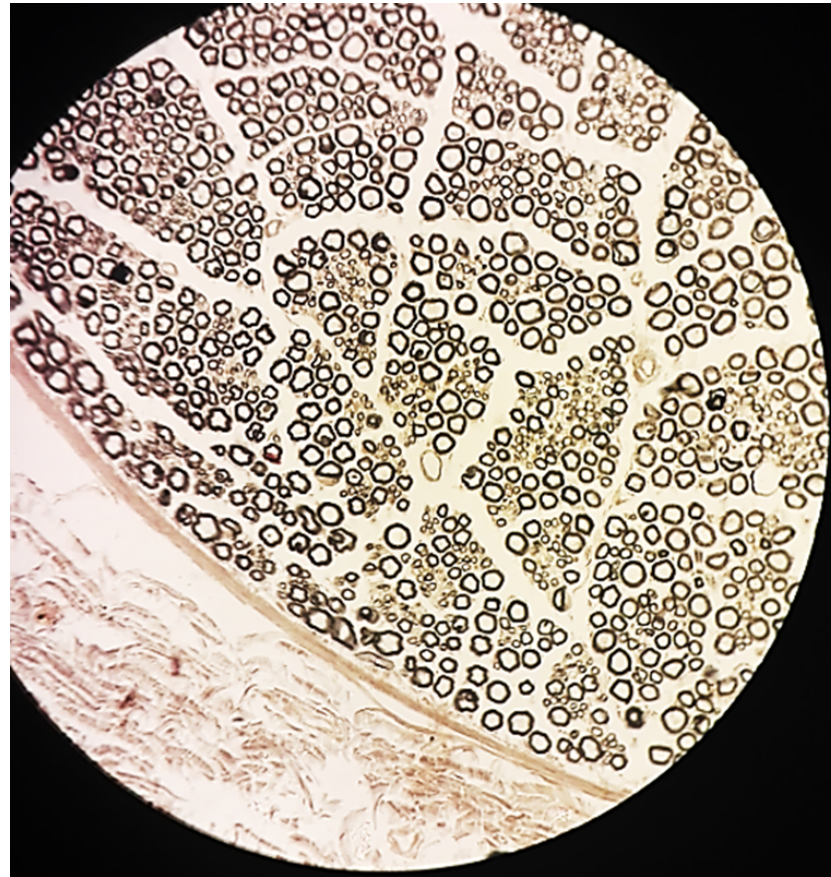


**FIGURE 7.19** ■ Sciatic nerve (transverse section). Stain: hematoxylin and eosin. High magnification (oil immersion).

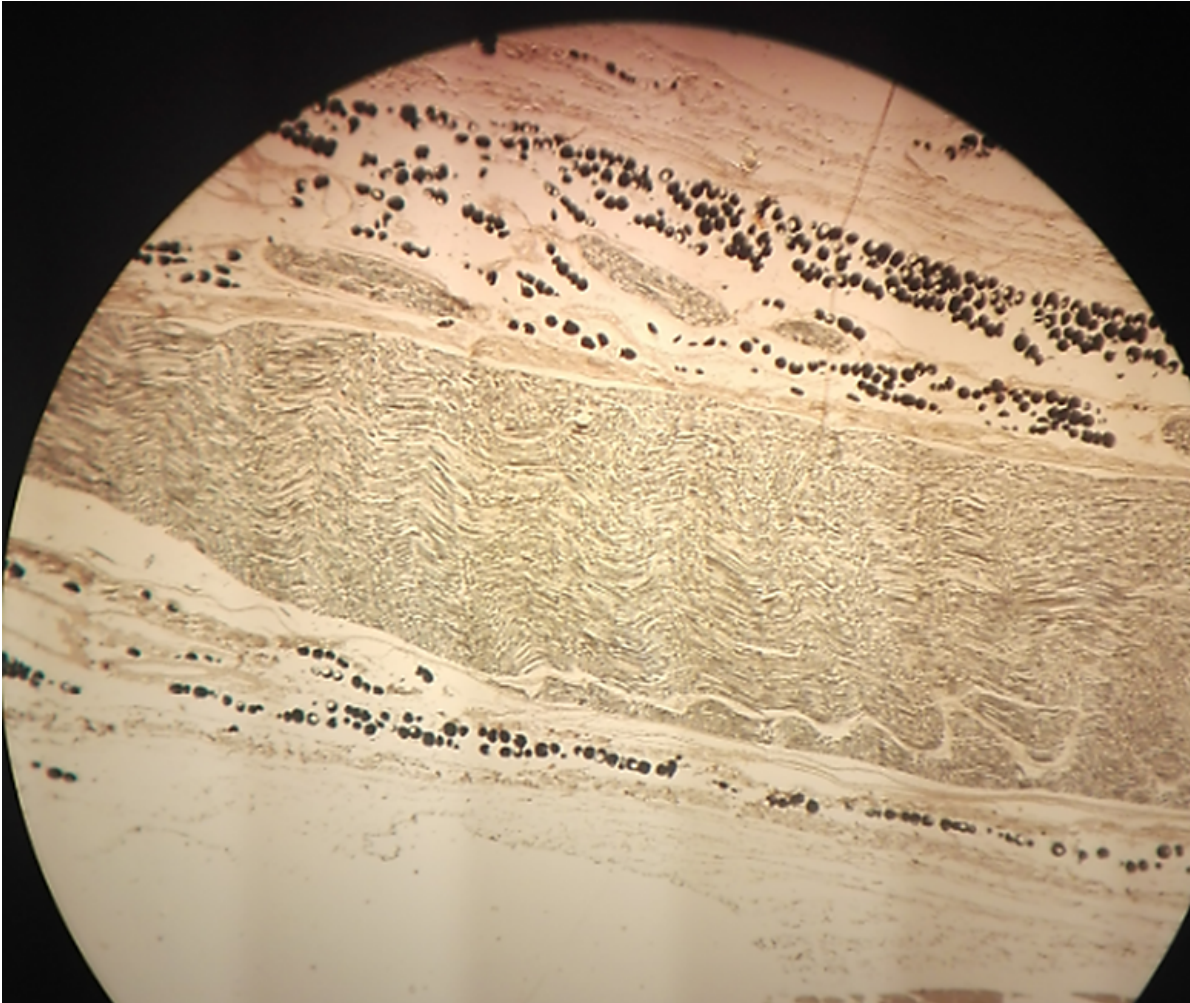
# Slide 14: TS & LS Sciatic Nerve LP (TS)



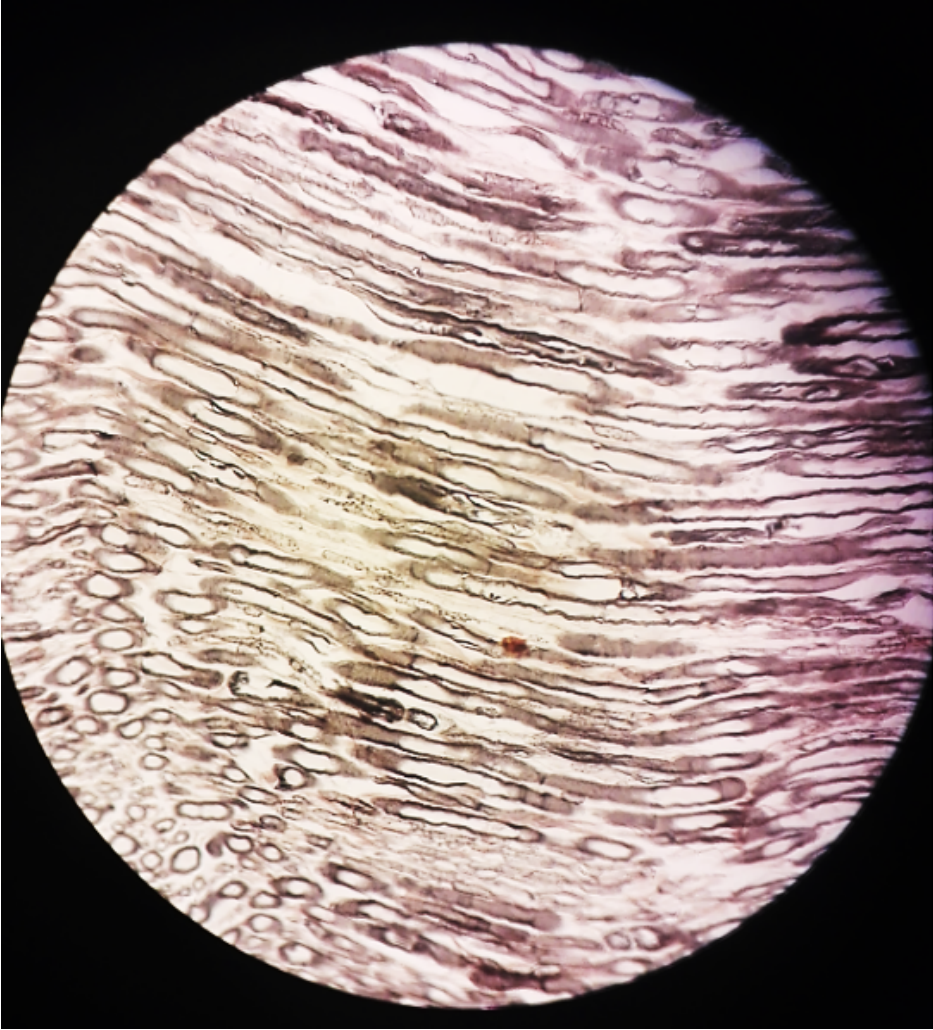
# Slide 14: TS & LS Sciatic Nerve LP (TS)



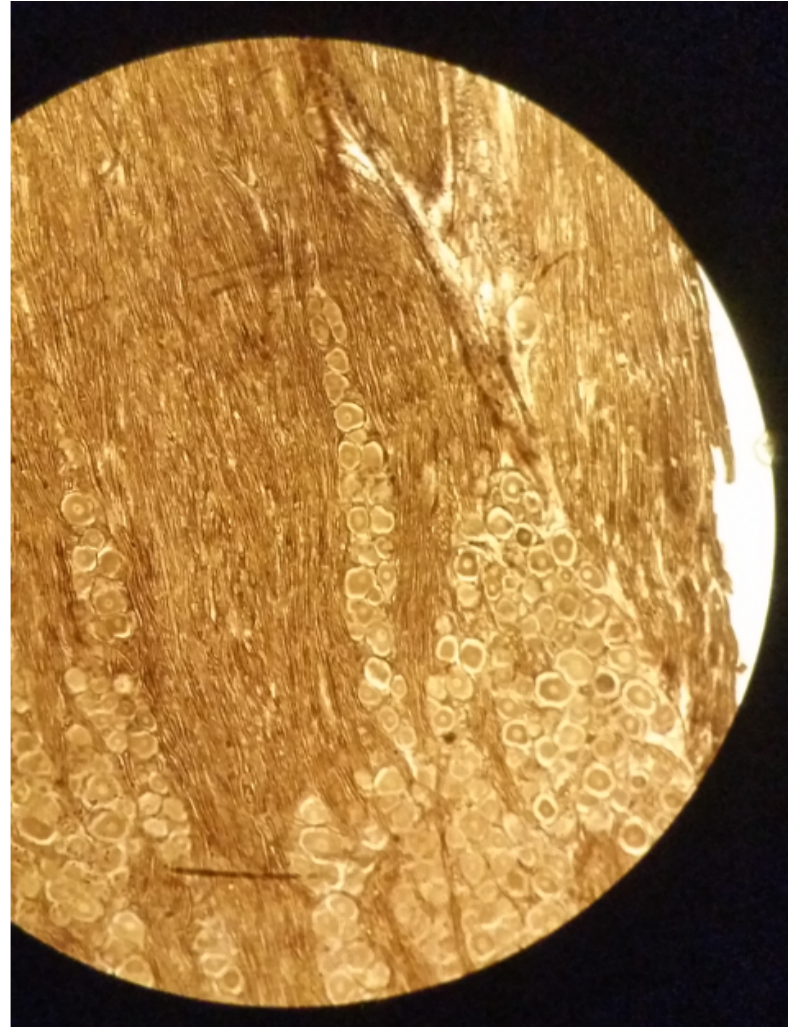
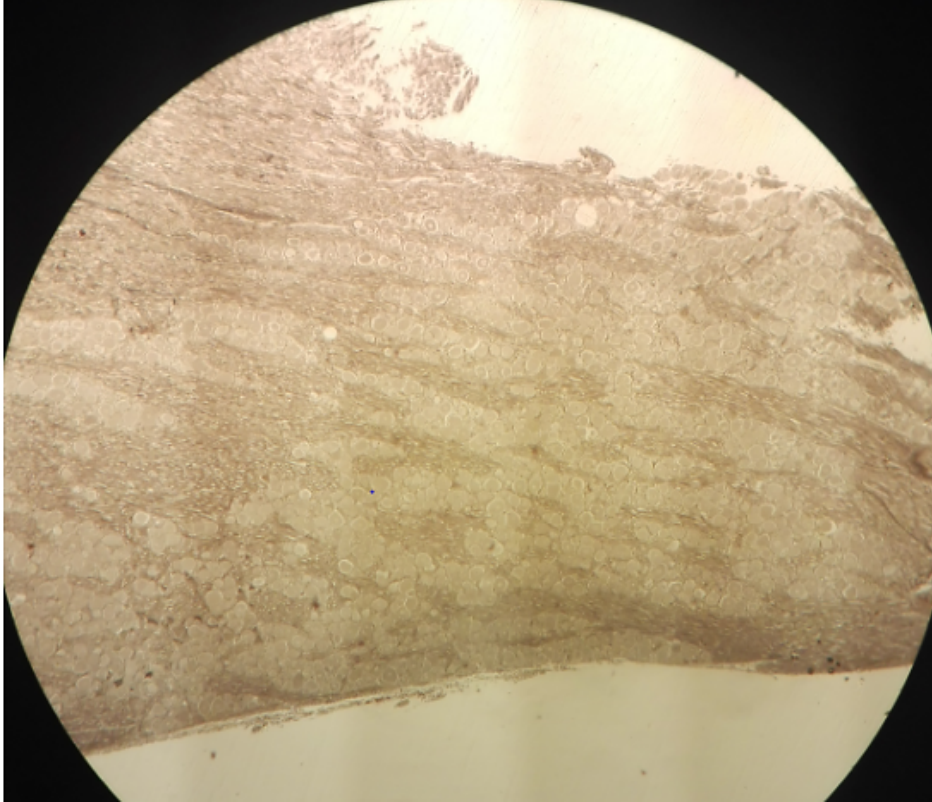
# Slide 14: TS & LS Sciatic Nerve LP (LS)



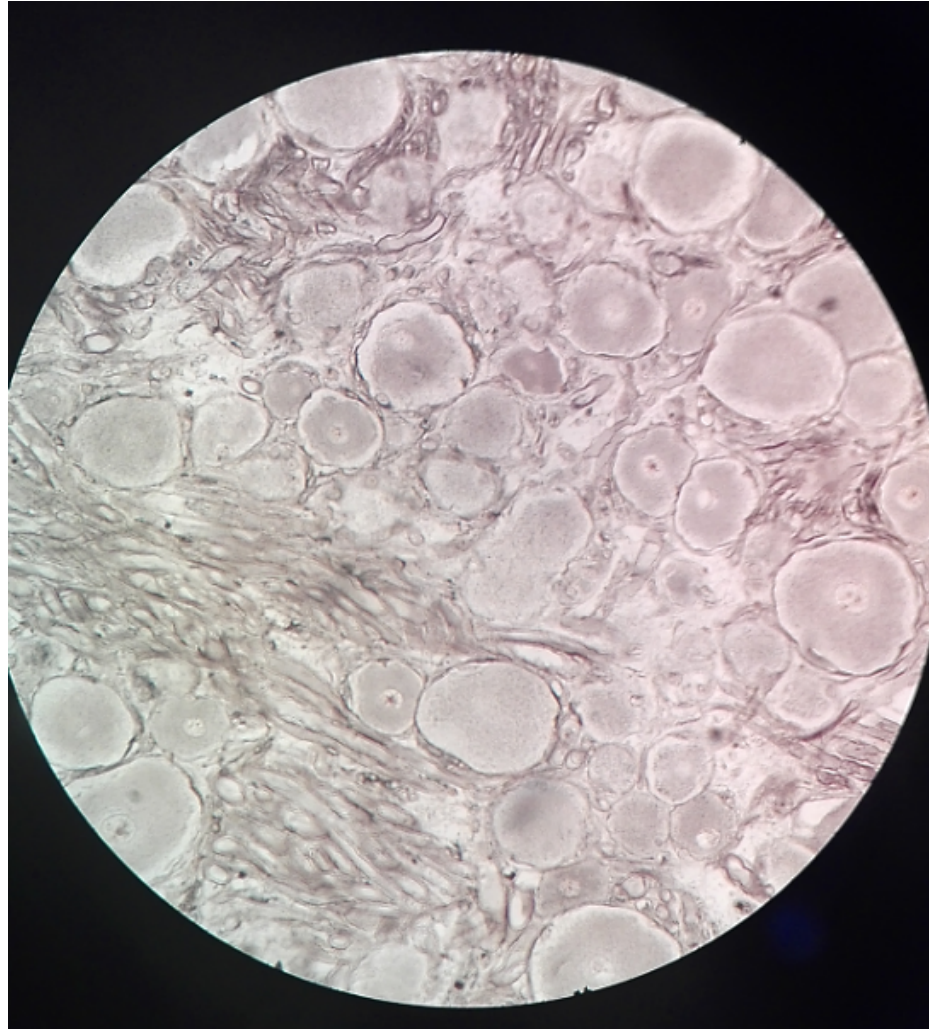
# Slide 14: TS & LS Sciatic Nerve HP (LS)



# Sensory ganglion: Slide 15 Trigeminal Ganglion LP & MP


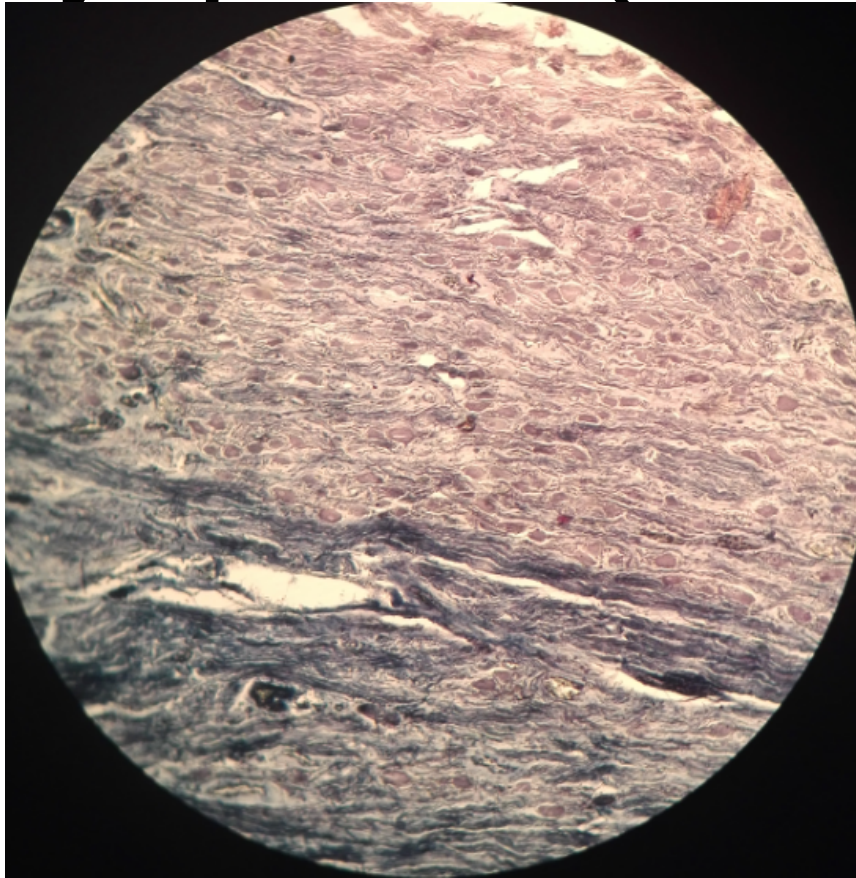


# Sensory ganglion: Slide 15 Trigeminal Ganglion HP



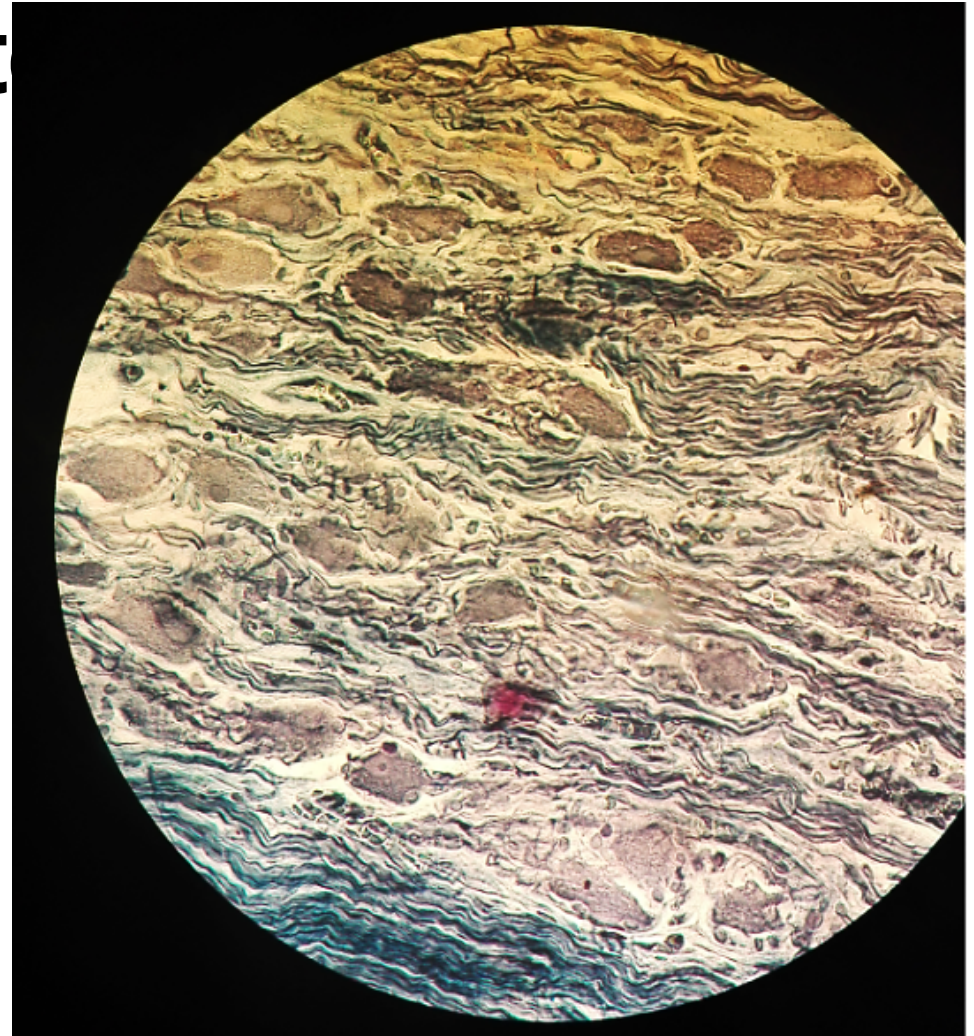
# Autonomic Ganglion: Slide 17

## Sympathetic (Stellate) Ganglion LP & MP

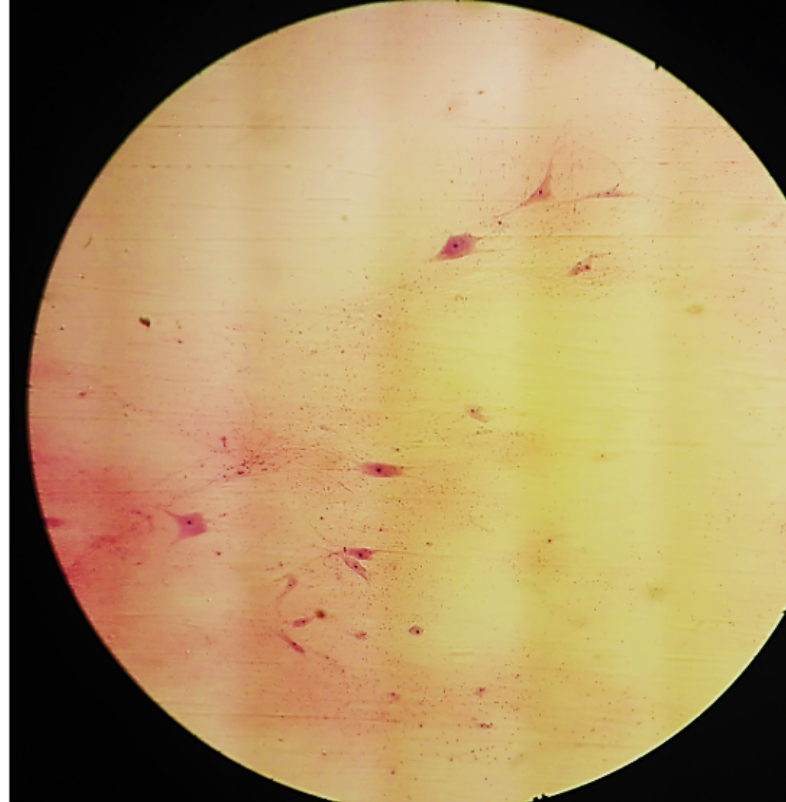


# Autonomic Ganglion: Slide 17

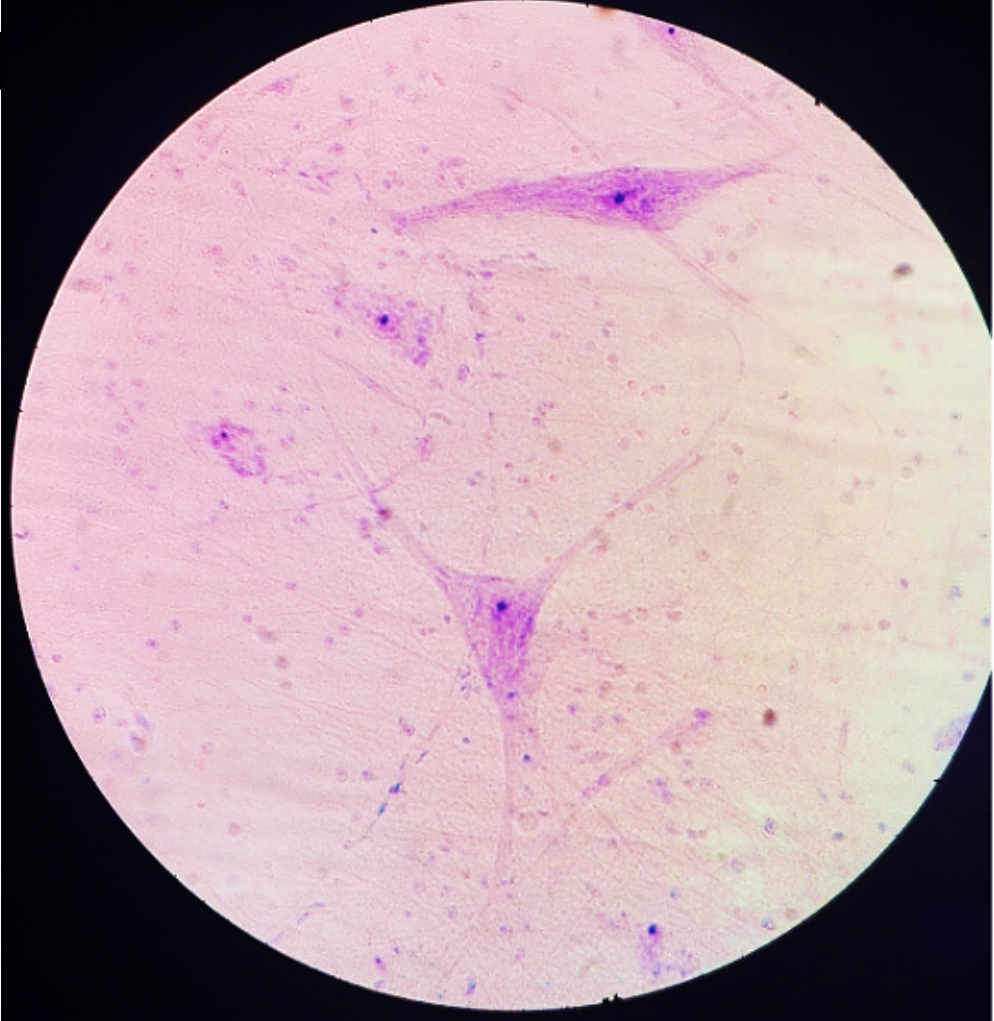
## Sympathetic (Stellat



# Multipolar Neurons: Slide H4.11 0x Spinal Cord LP



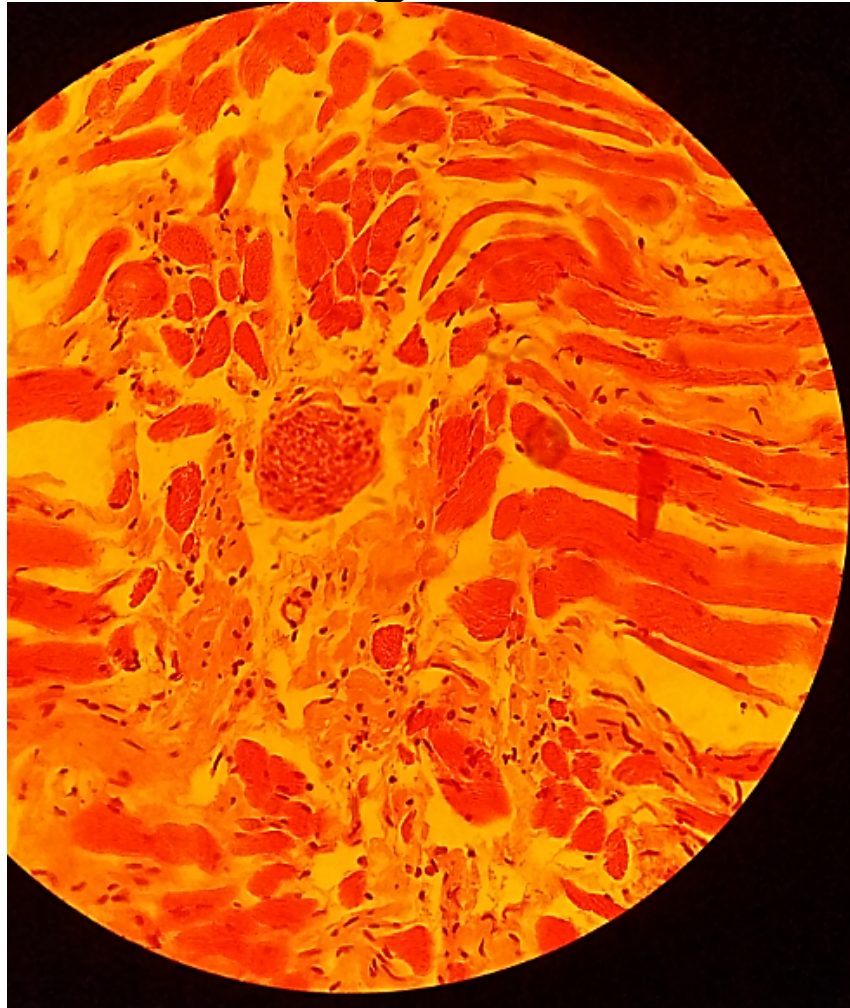
# Multipolar Neurons: Slide H4.11 Ox Spinal Cord



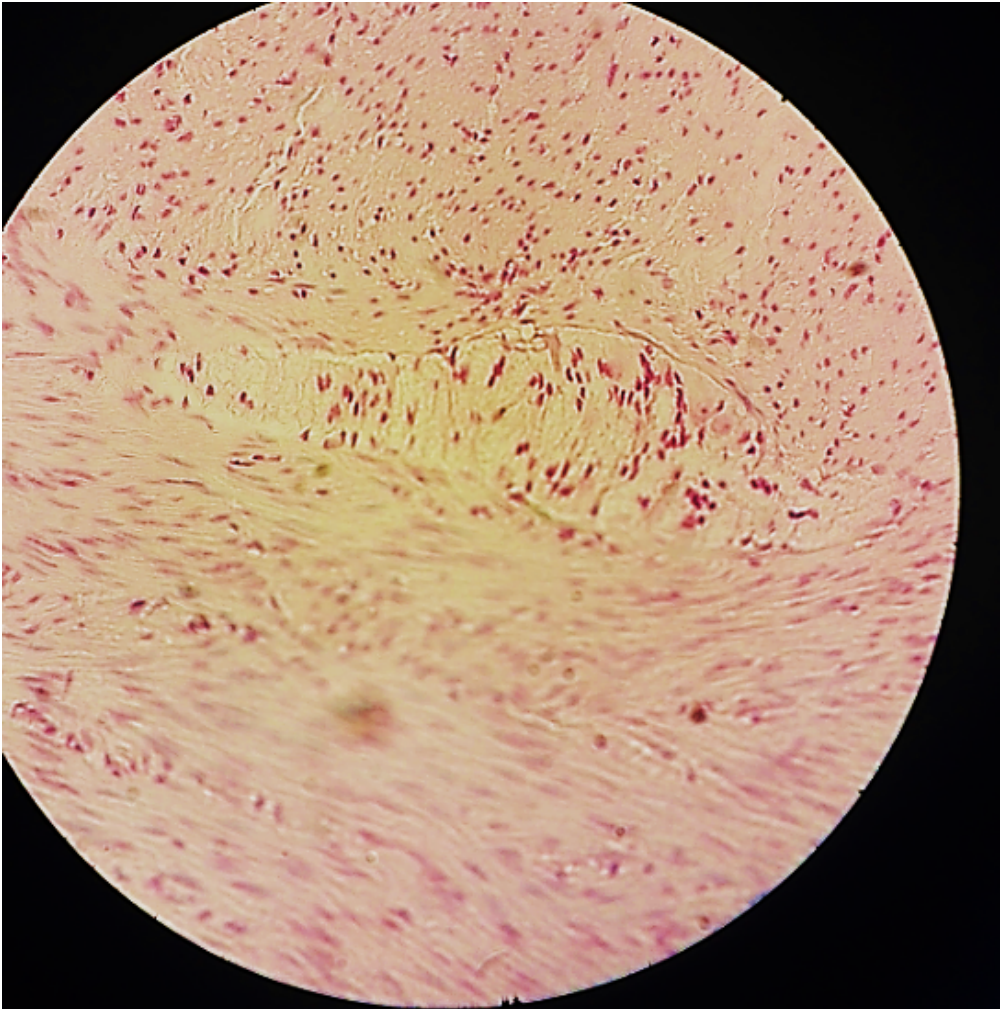
# **PERIPHERAL AND AUTONOMIC NERVES IN TISSUE**

# Slide 43/44: Tongue


HP



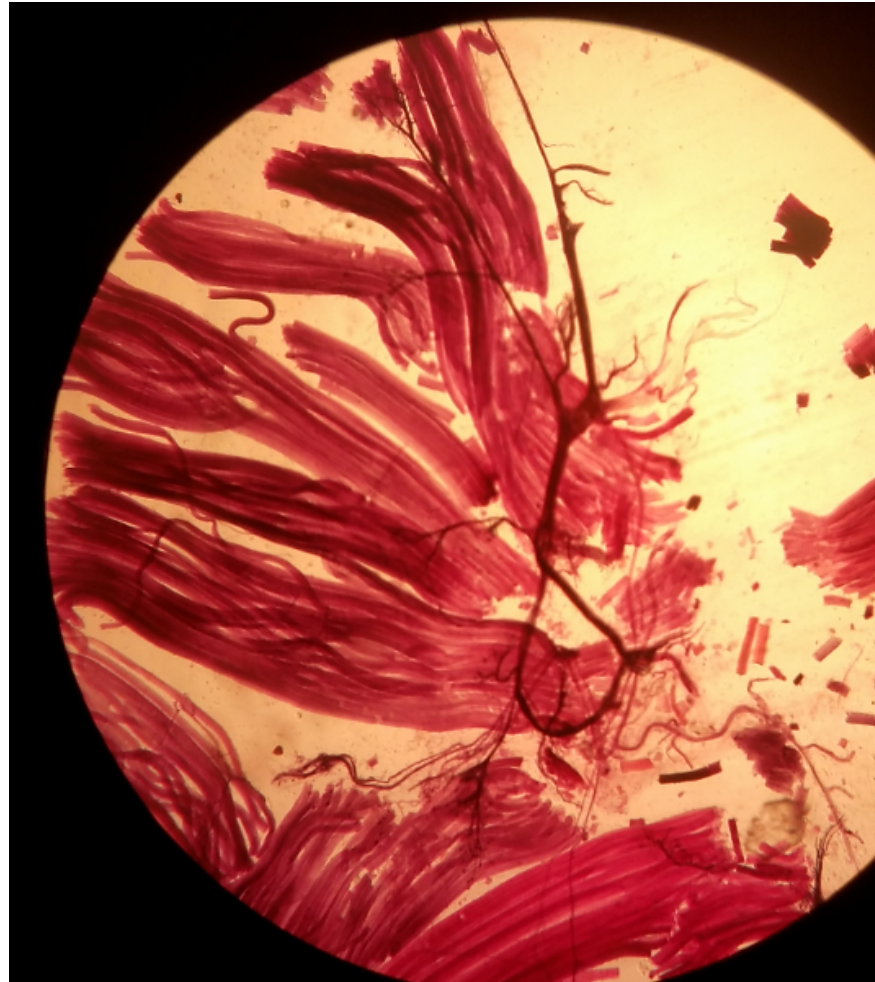
# Slide 57: Colon HP



# Slide 24: Motor End Plate (Ache reaction) LP (only)



# Slide H4.31 Motor Nerve Endings LP (only)

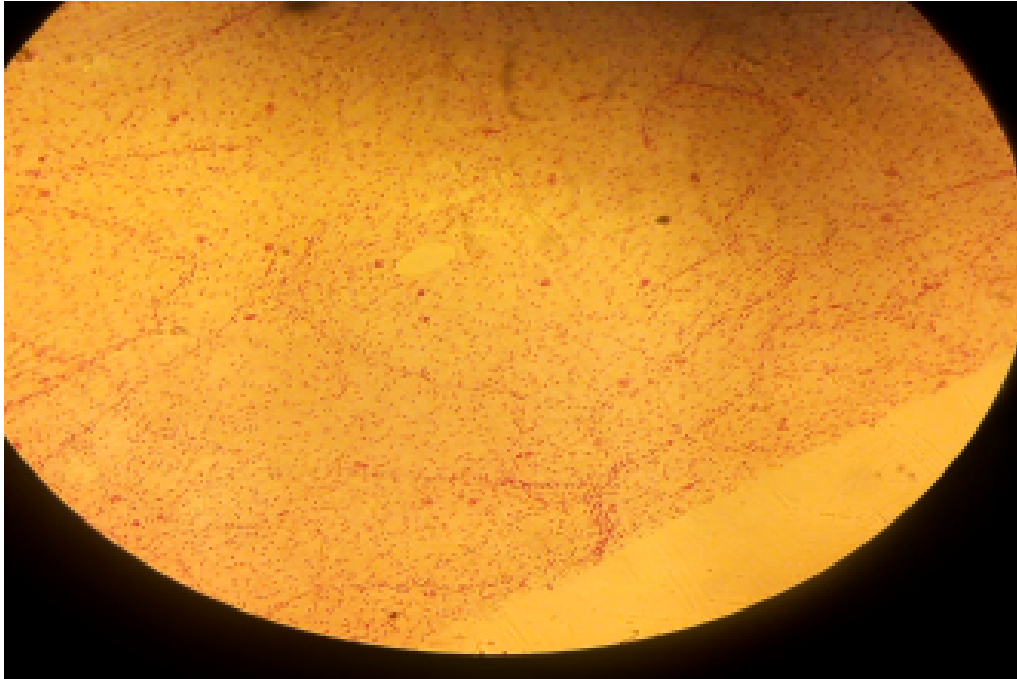


# PRACTICAL 11

BLOOD VASCULAR SYSTEM

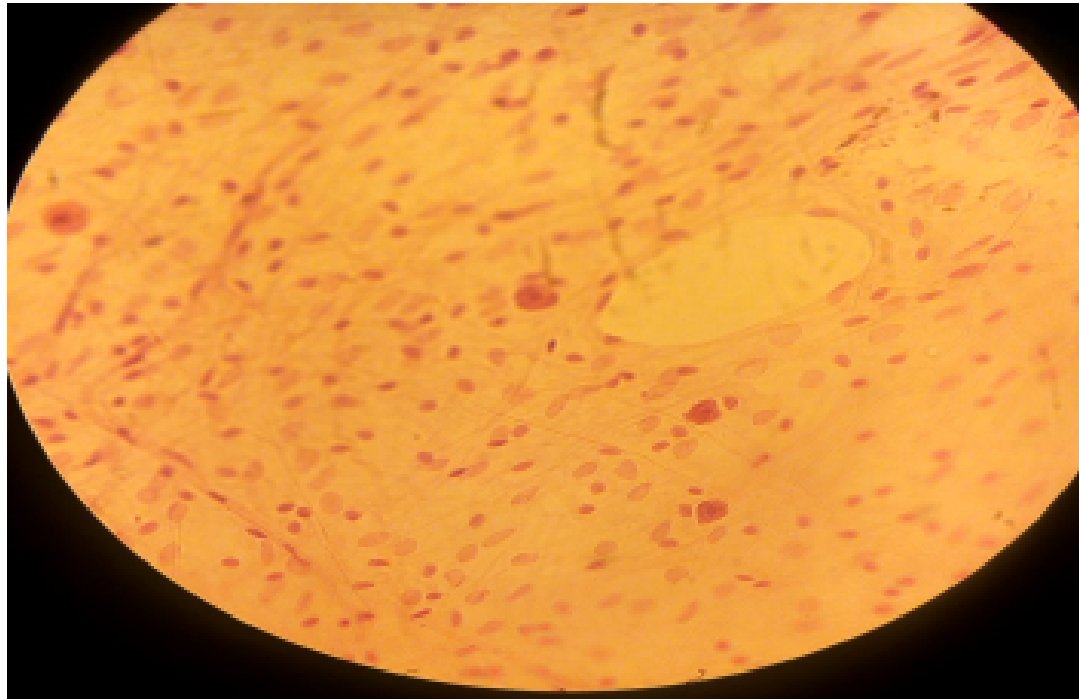
# SLIDE 1 SUBCUTANEOUS TISSUE SPREAD ( H&E + FERRITIN)

- LP, LOOSE/ AREOLAR CONNECTIVE TISSUE



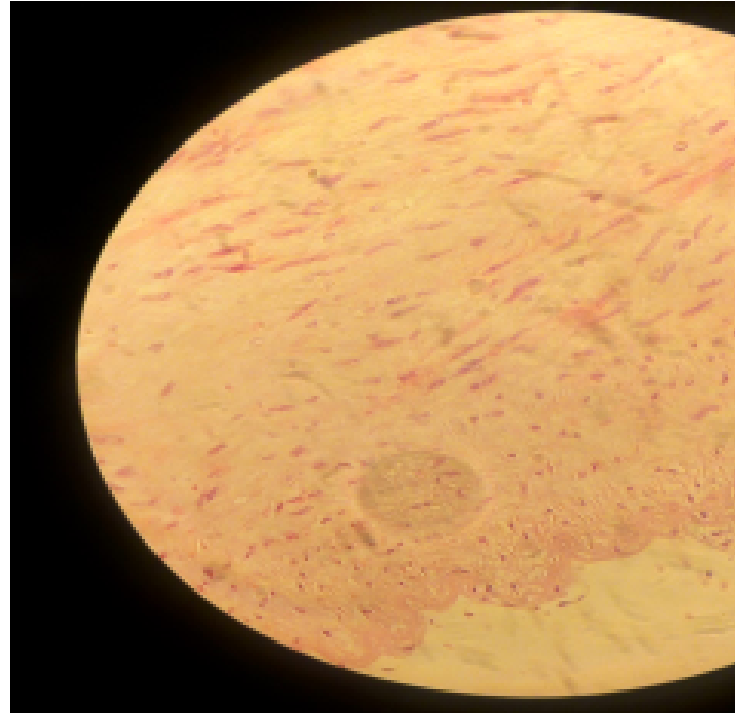
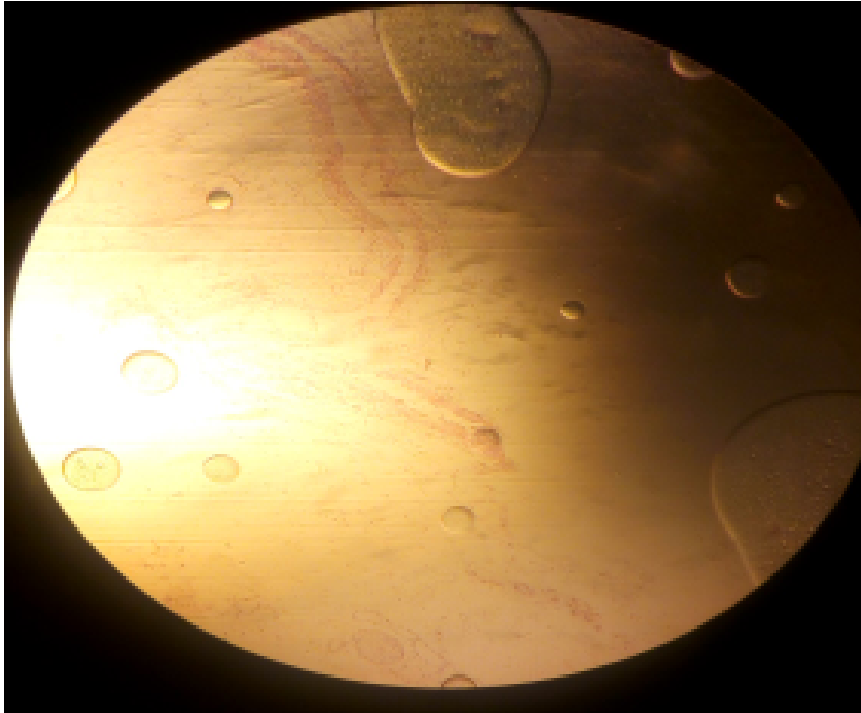
# SLIDE 1 SUBCUTANEOUS TISSUE SPREAD ( H&E + FERRITIN)

- HP, LOOSE/ AREOLAR CONNECTIVE TISSUE

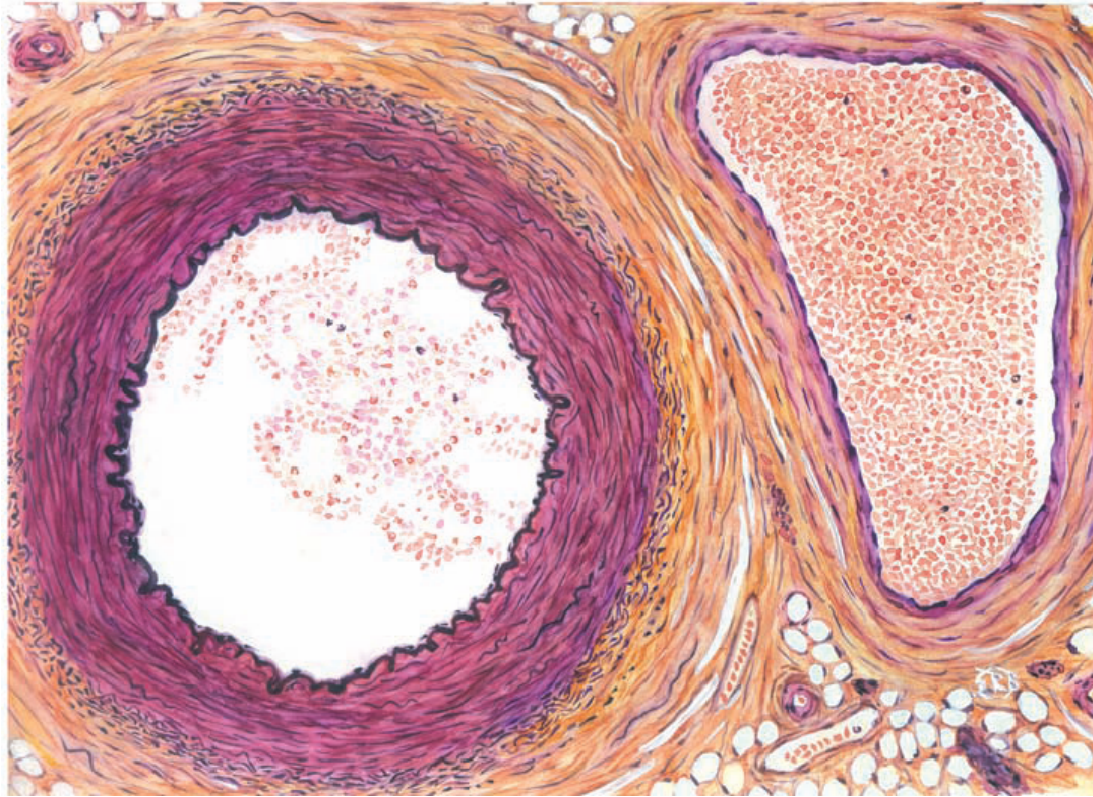


# SLIDE 27 AORTA AND VENA CAVA (H&E)


- LP/MP



# MUSCULAR ARTERY AND VEIN

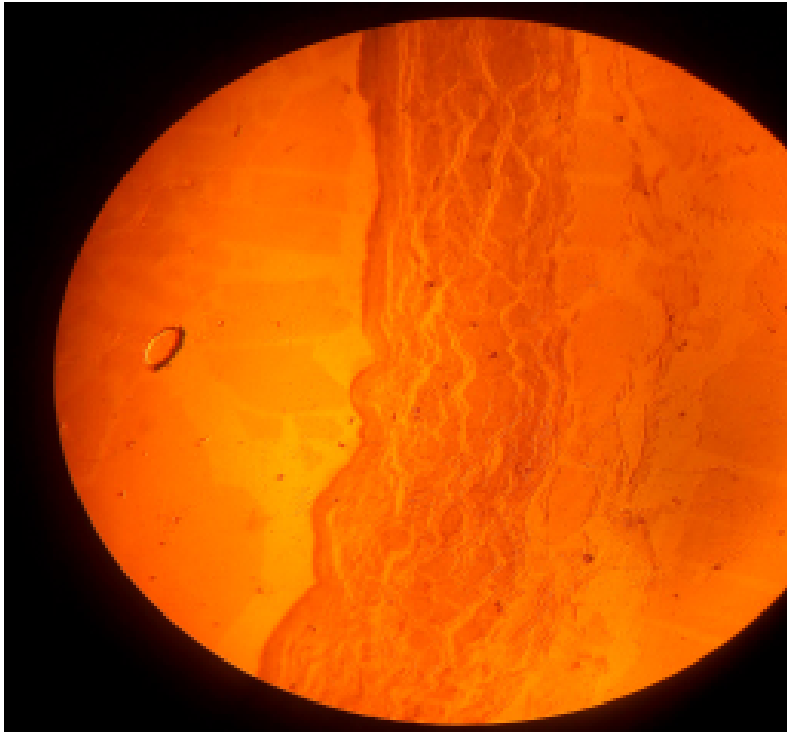


# MUSCULAR ARTERY

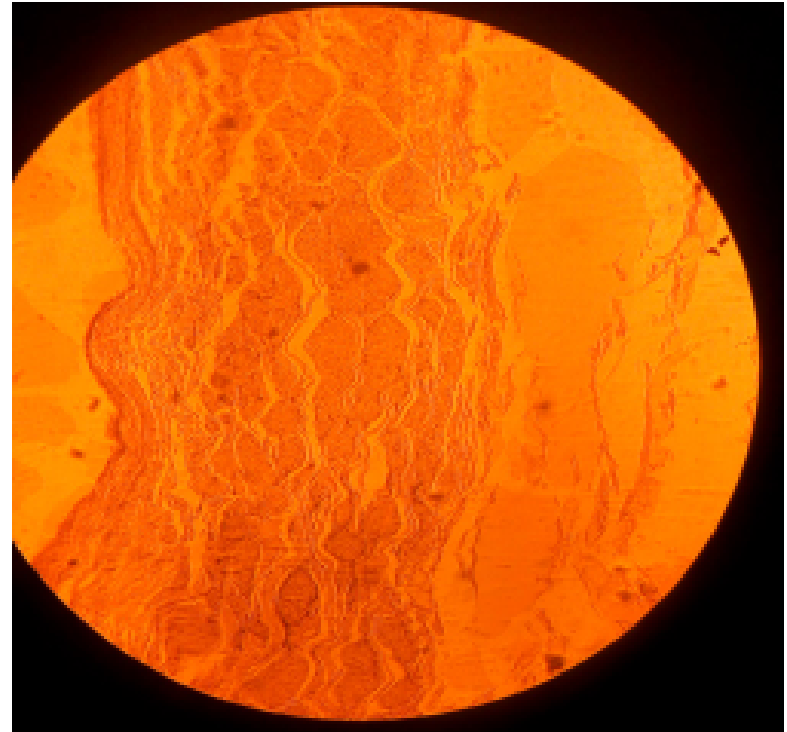


# SLIDE H 8.32 VENA CAVA, HUMAN (H&E)

- LP

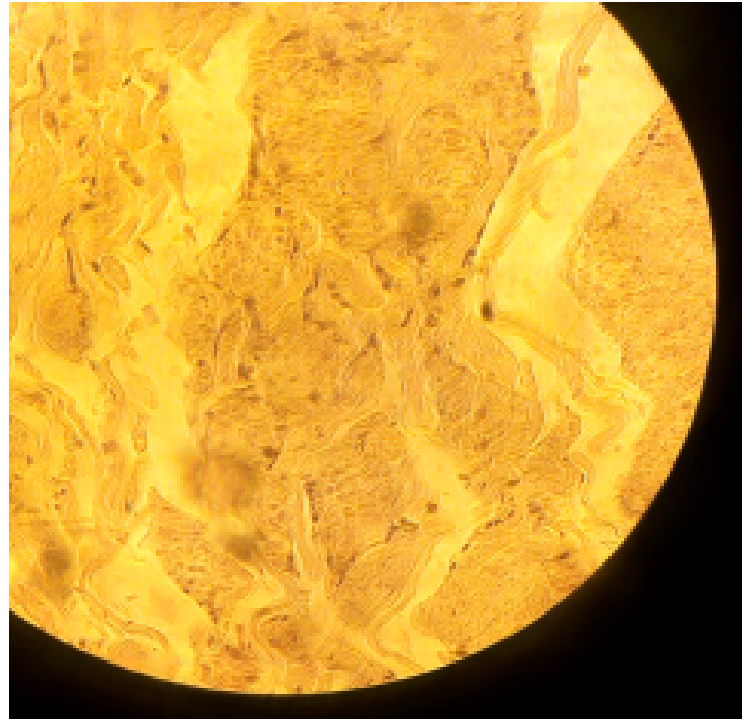
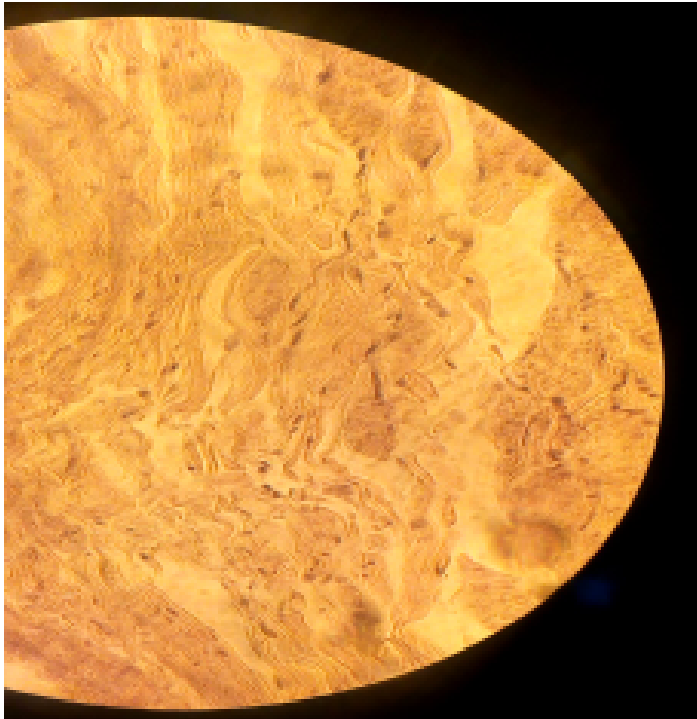


MP

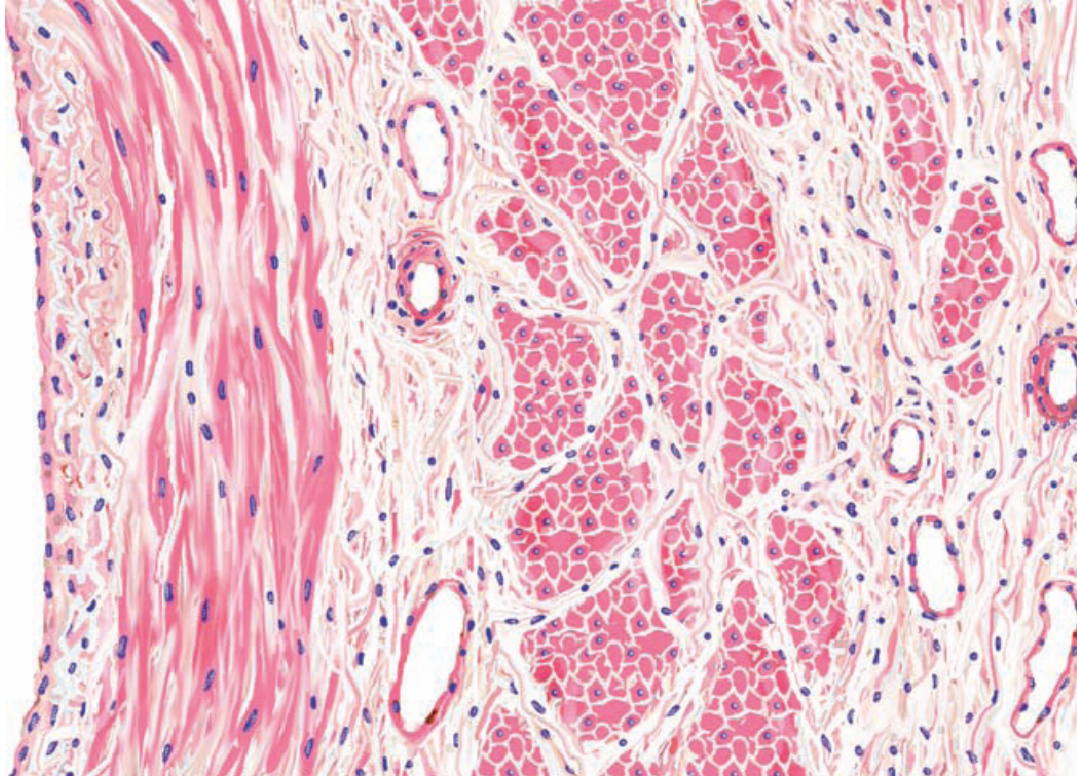


# SLIDE H 8.32 VENA CAVA, HUMAN (H&E)

- HP, TUNICA ADVENTITIA WITH SMOOTH MUSCLES

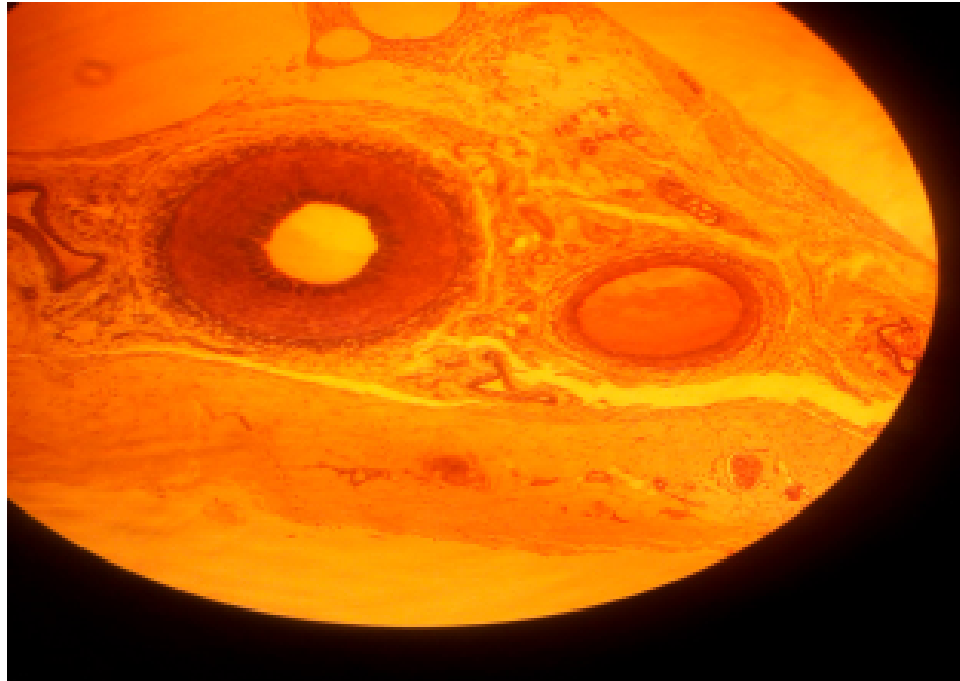


# LARGE VEIN



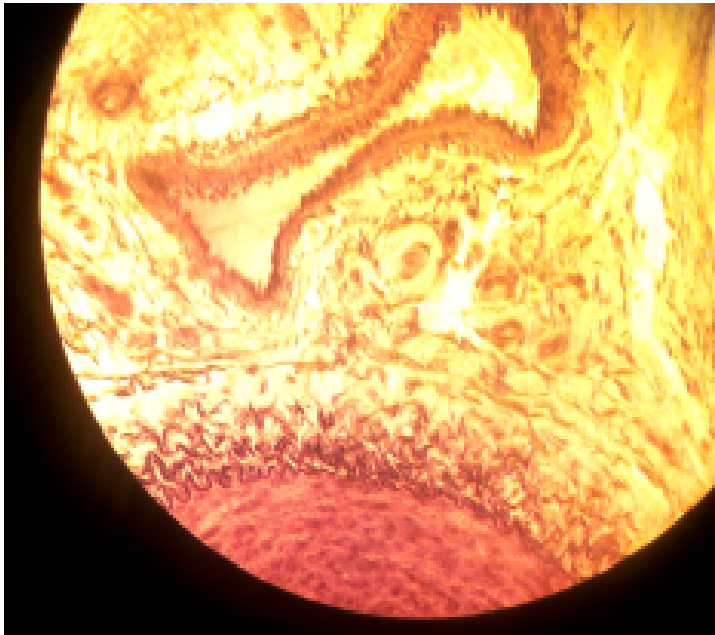
# SLIDE H 8.23 ARTERY, VEIN AND NERVE

- LP

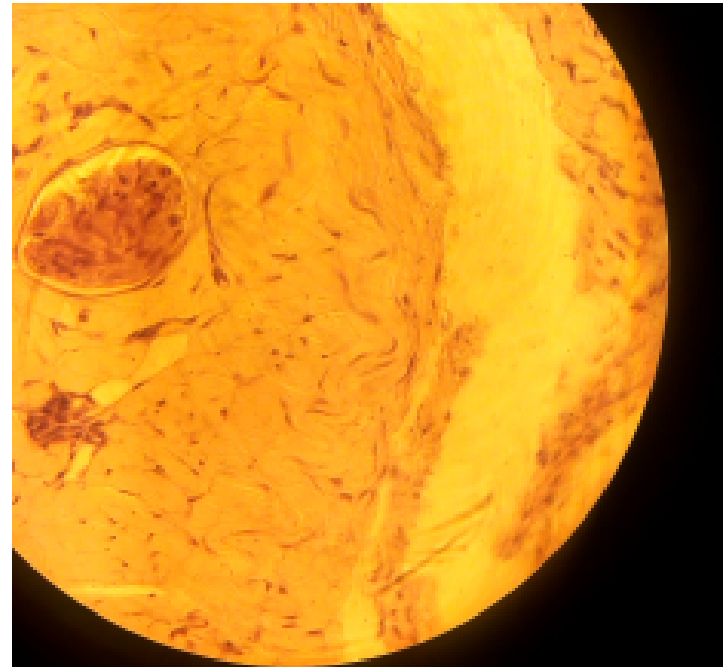


# SLIDE H 8.23 ARTERY, VEIN AND NERVE

• MP VEIN

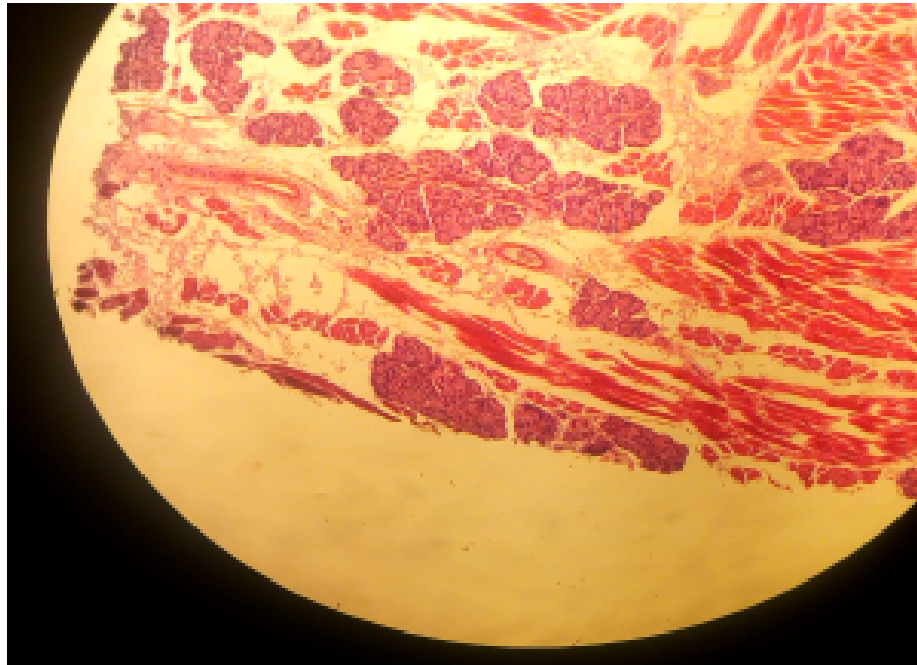


NERVE



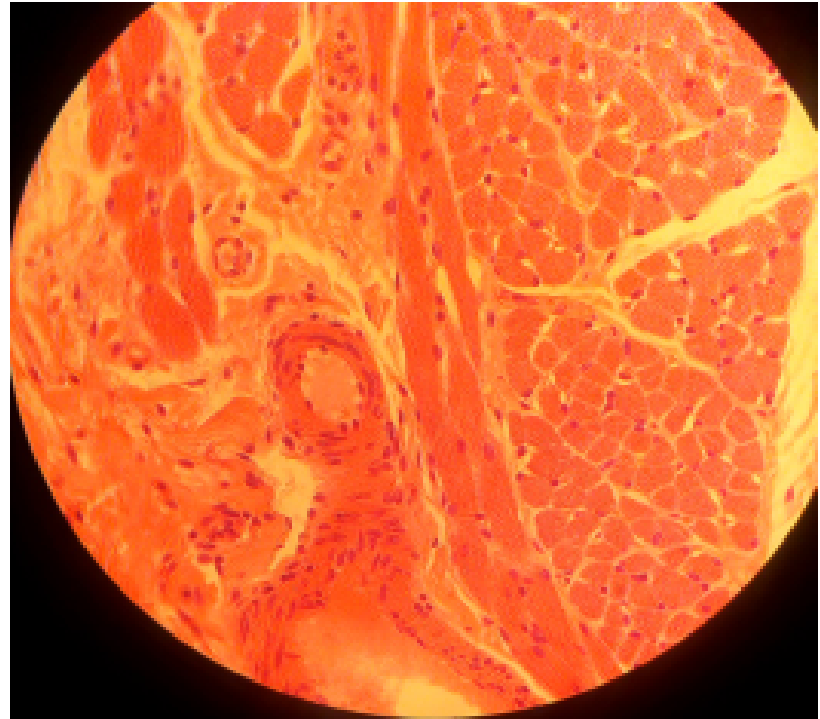
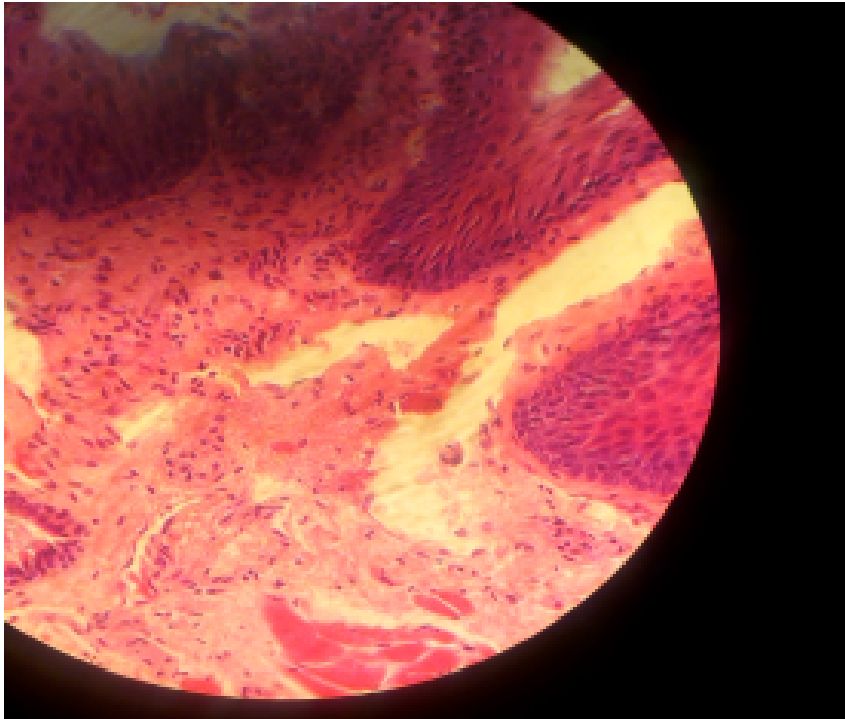
# SLIDE 44 TONGUE, RABBIT (MALLORY)

- LP



# SLIDE 44 TONGUE, RABBIT (MALLORY)

- HP

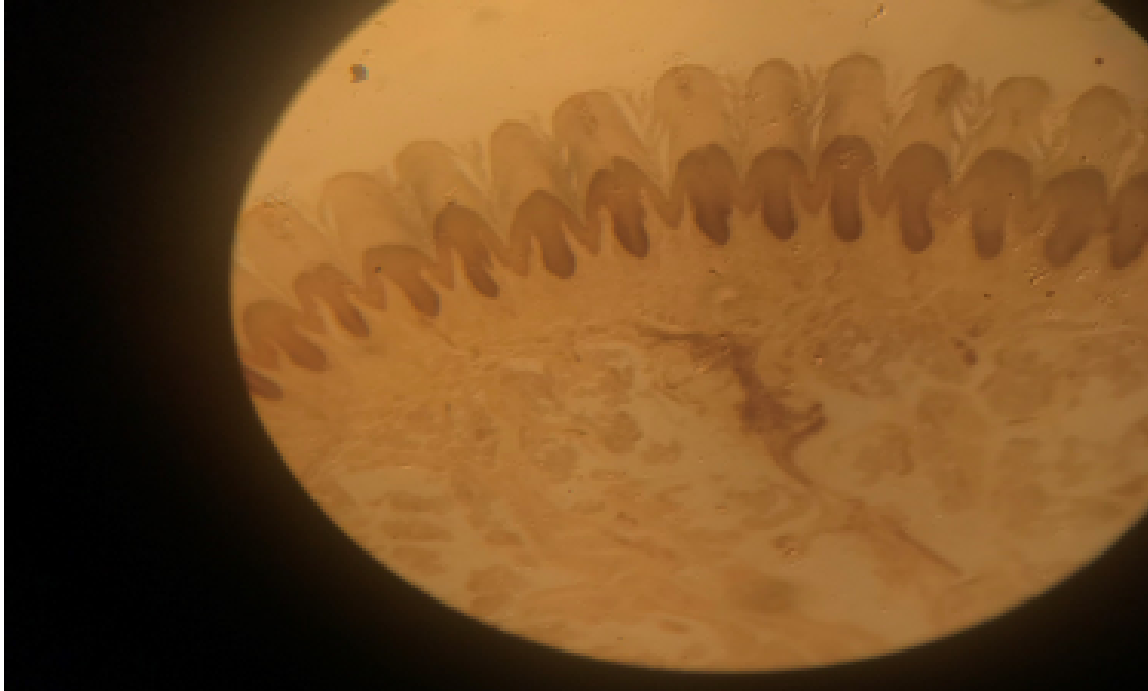


# PRACTICAL 13

INTEGUMENTARY SYSTEM

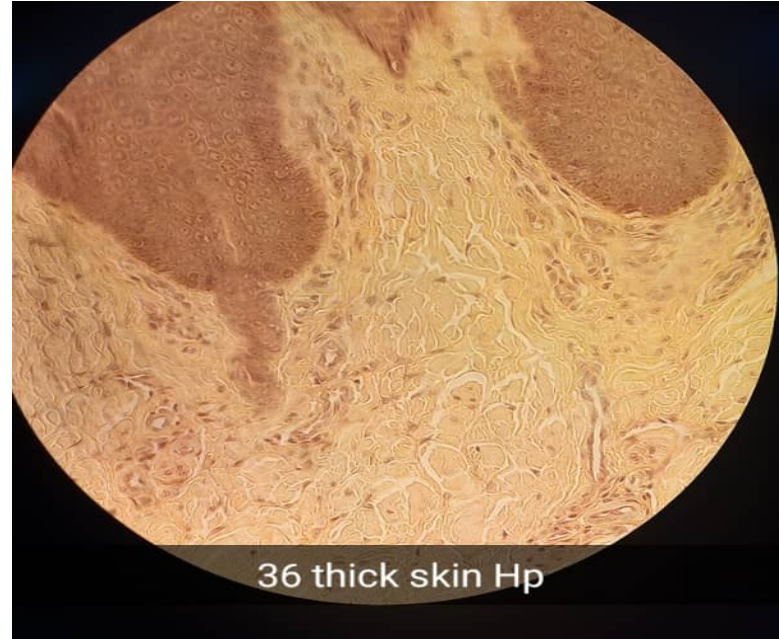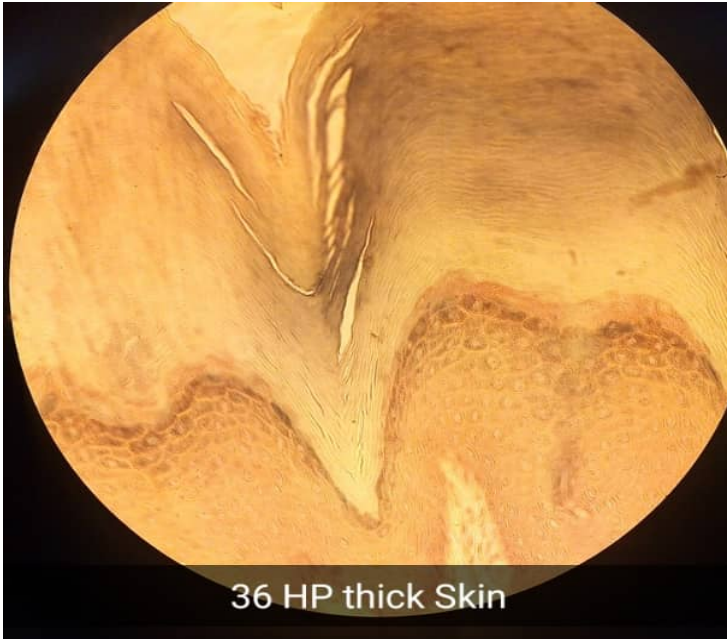# SLIDE 36 THICK SKIN, HEEL (H & E)

- LP



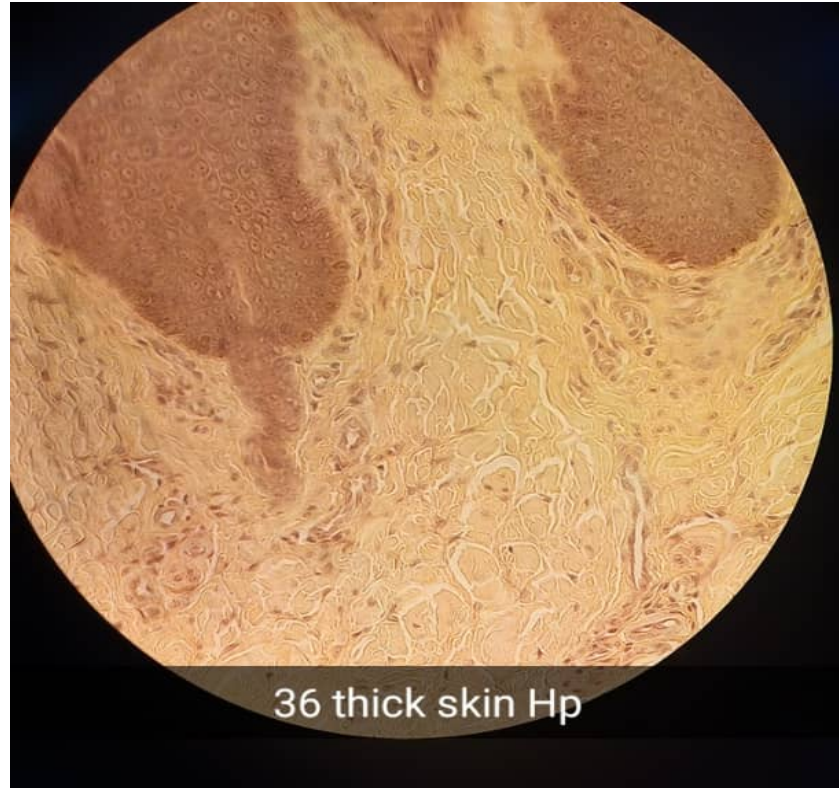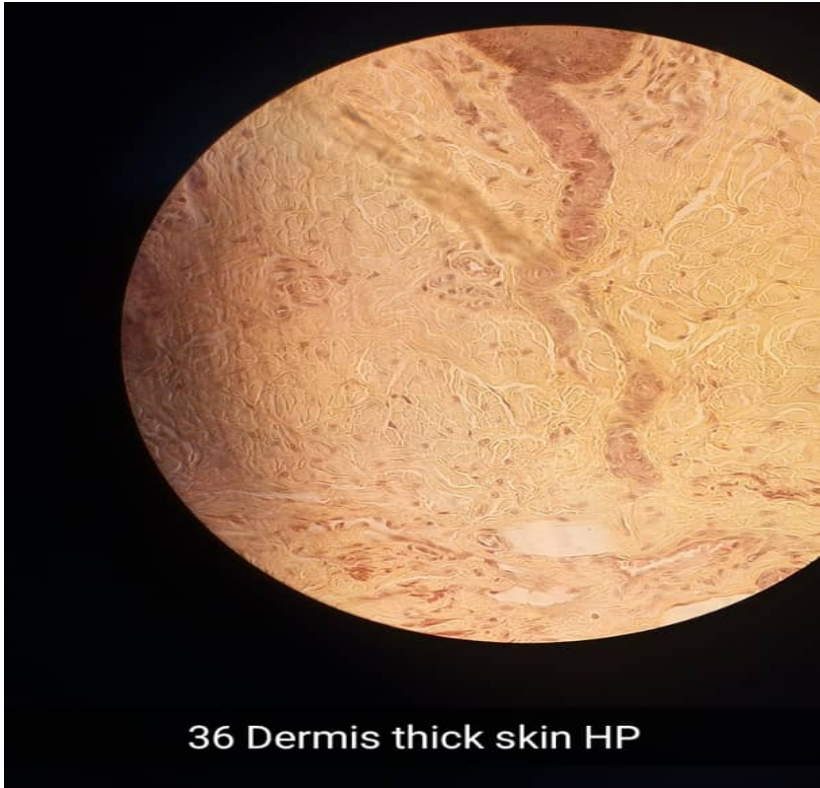
# SLIDE 36 THICK SKIN, HEEL (H & E)

- HP



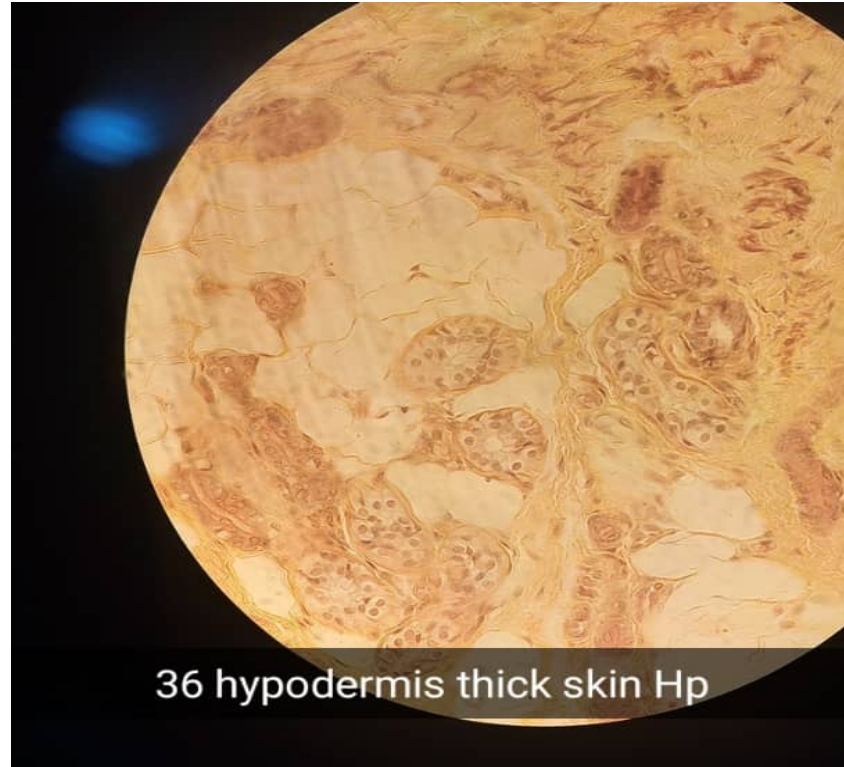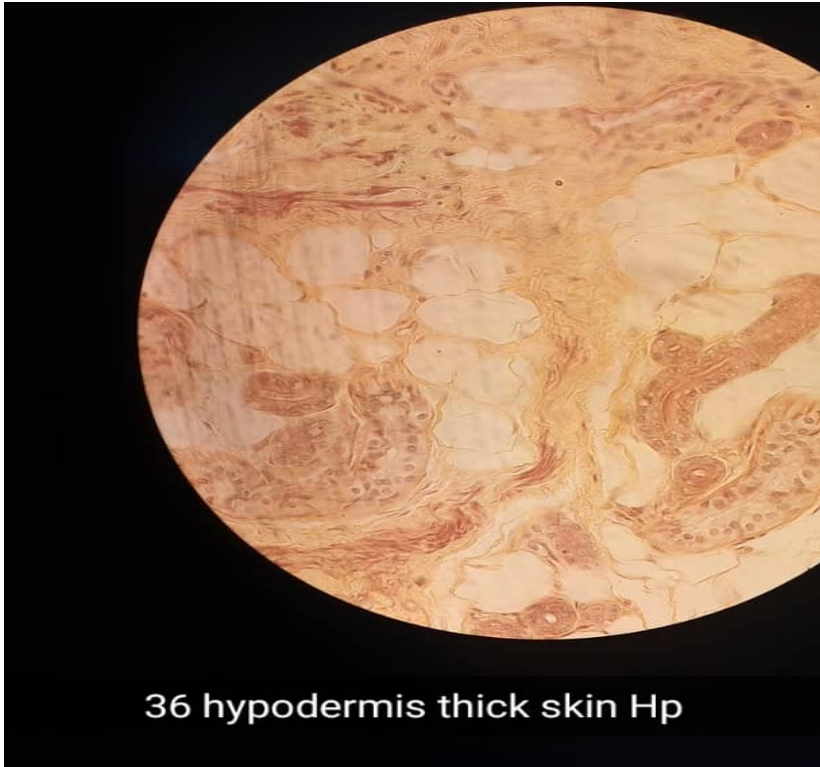# SLIDE 36 THICK SKIN, HEEL (H & E)

- HP



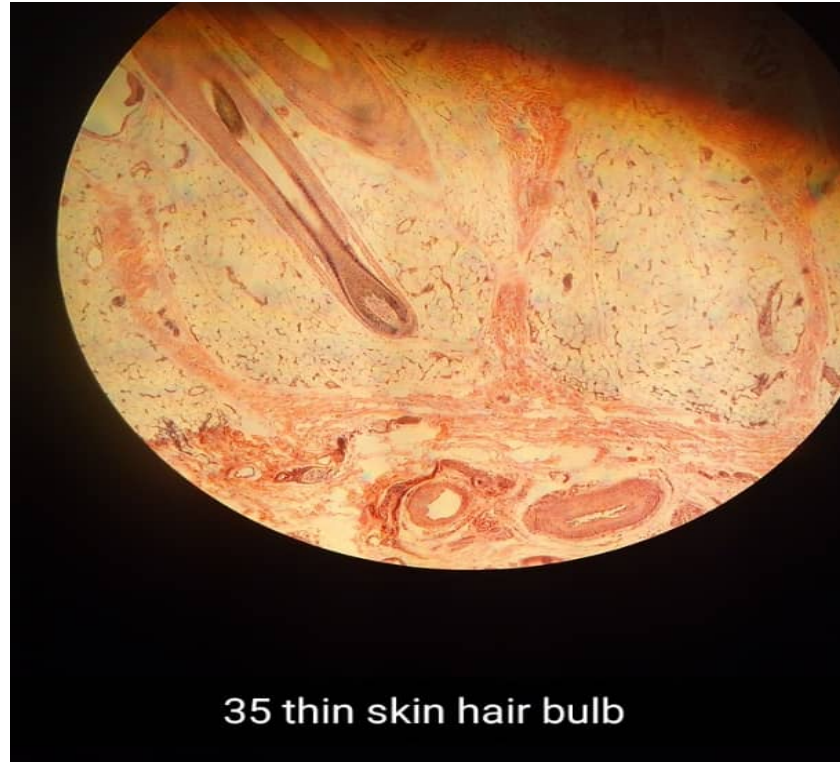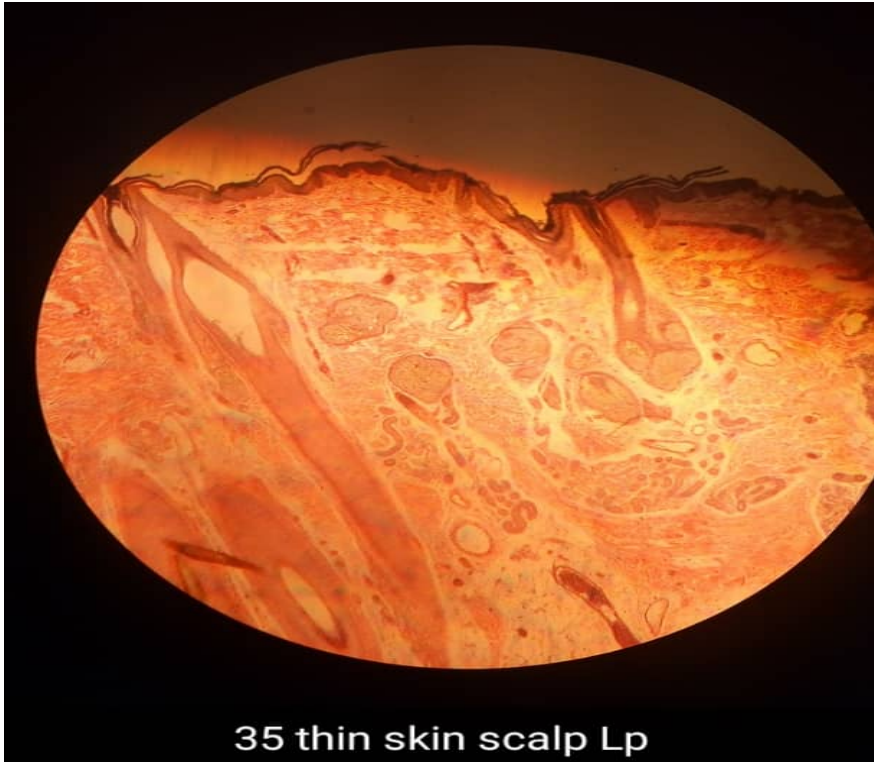# SLIDE 36 THICK SKIN, HEEL (H & E)

- HP



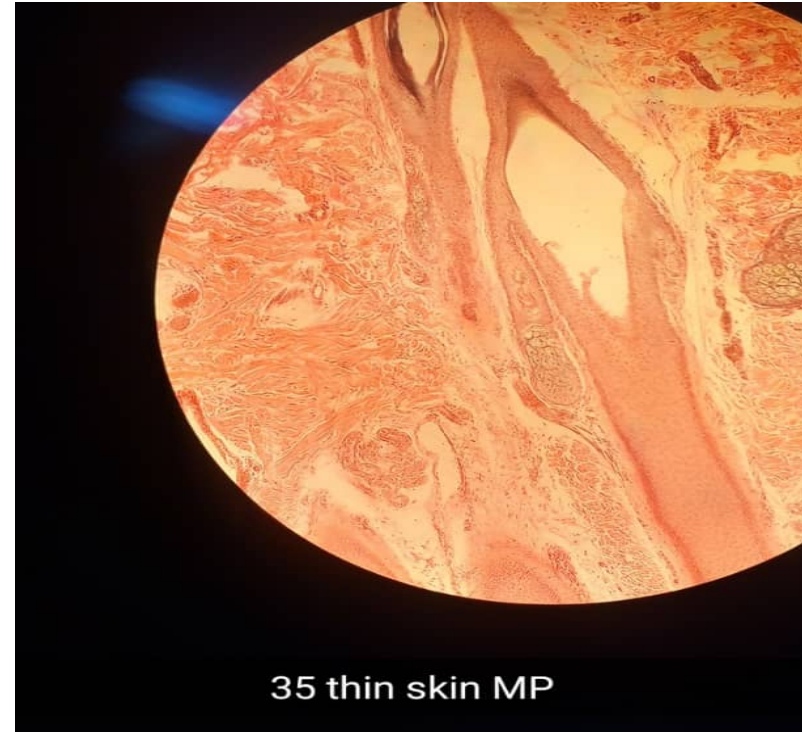
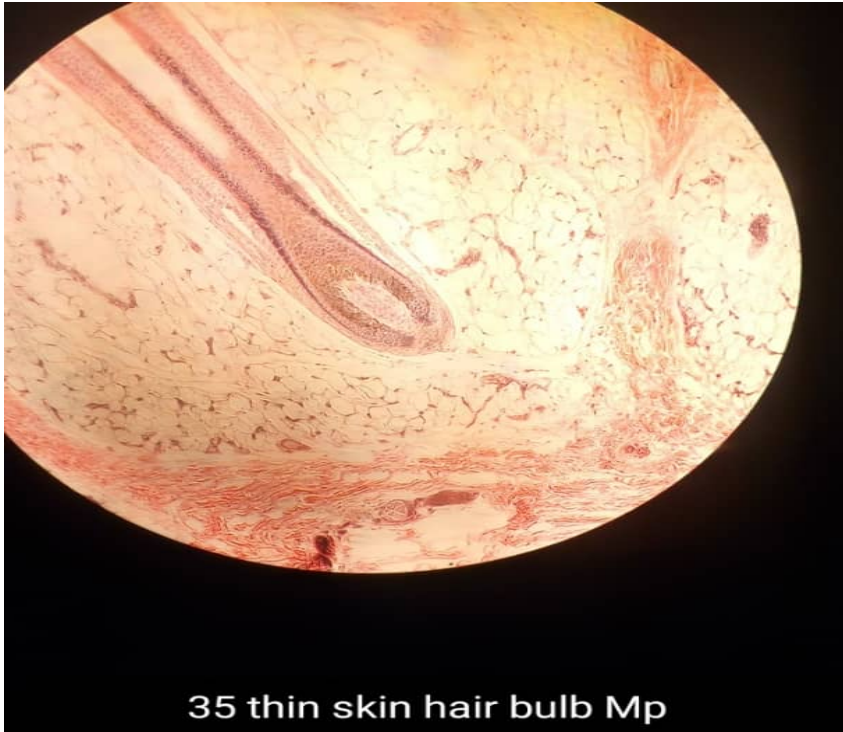# SLIDE 35 THIN SKIN, SCALP (H & E)

- LP



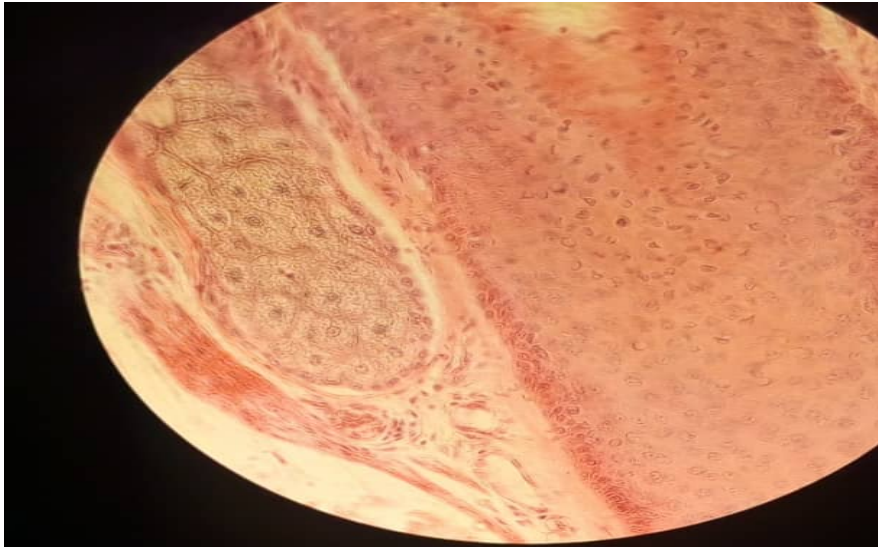
# SLIDE 35 THIN SKIN, SCALP (H & E)

- MP

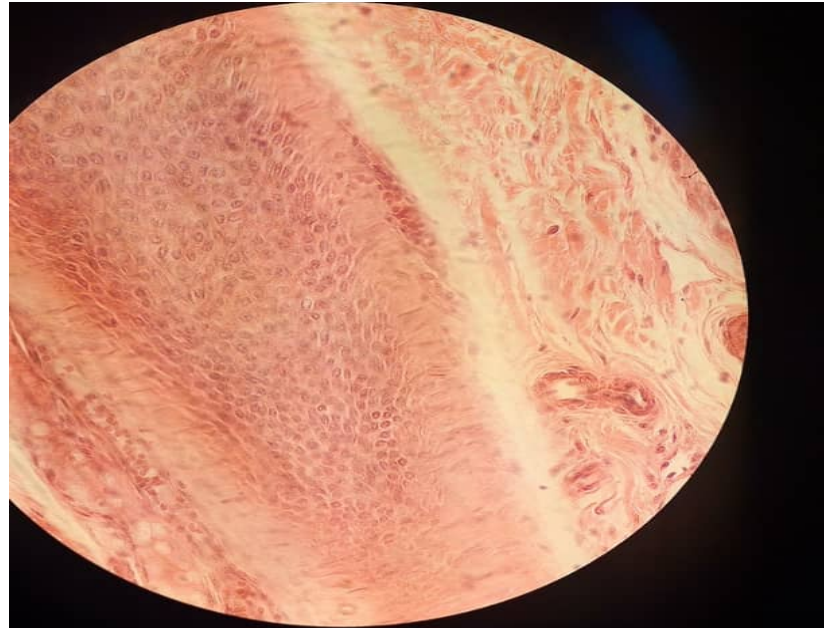


# SLIDE 35 THIN SKIN, SCALP (H & E)

- HP



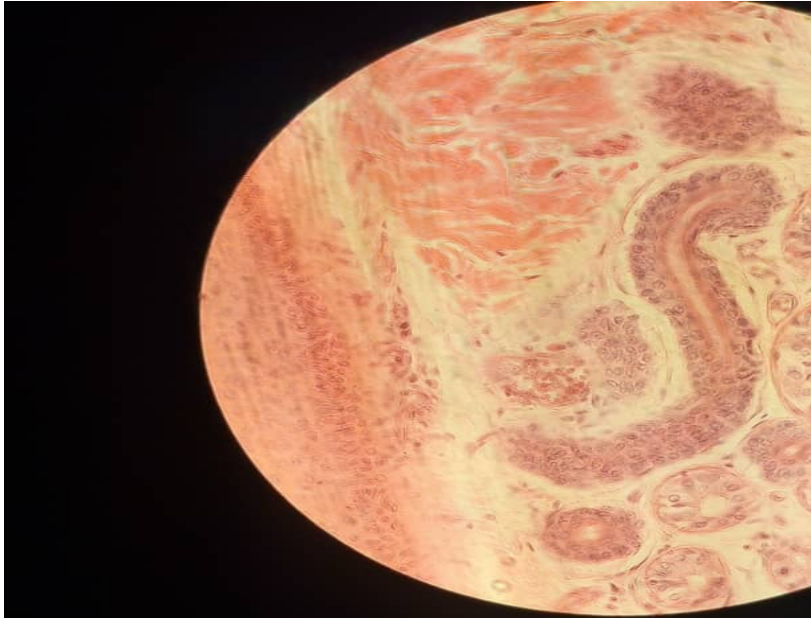
35 thin skin hair follicle + arrector pili muscle



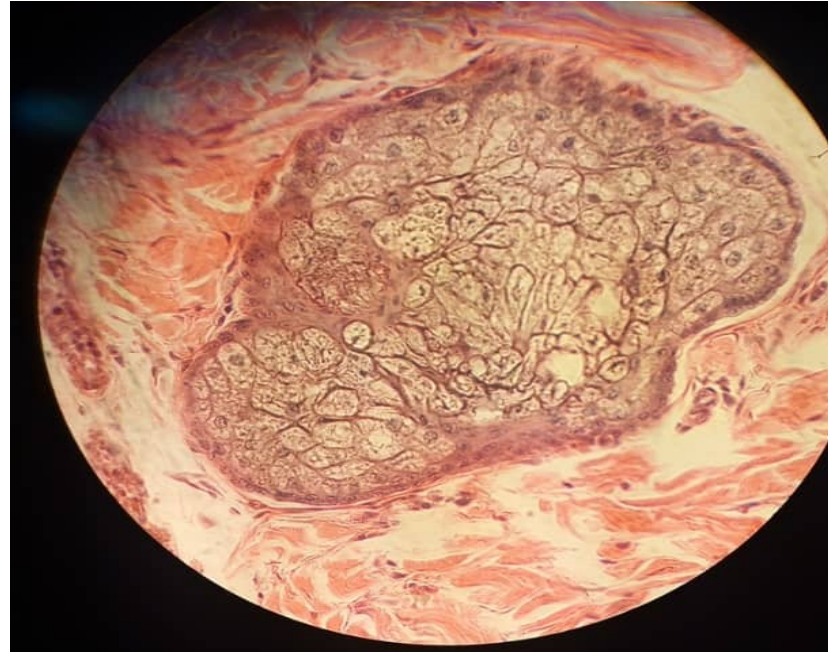
35 thin skin hair follicle Hp

# SLIDE 35 THIN SKIN, SCALP (H & E)

- HP



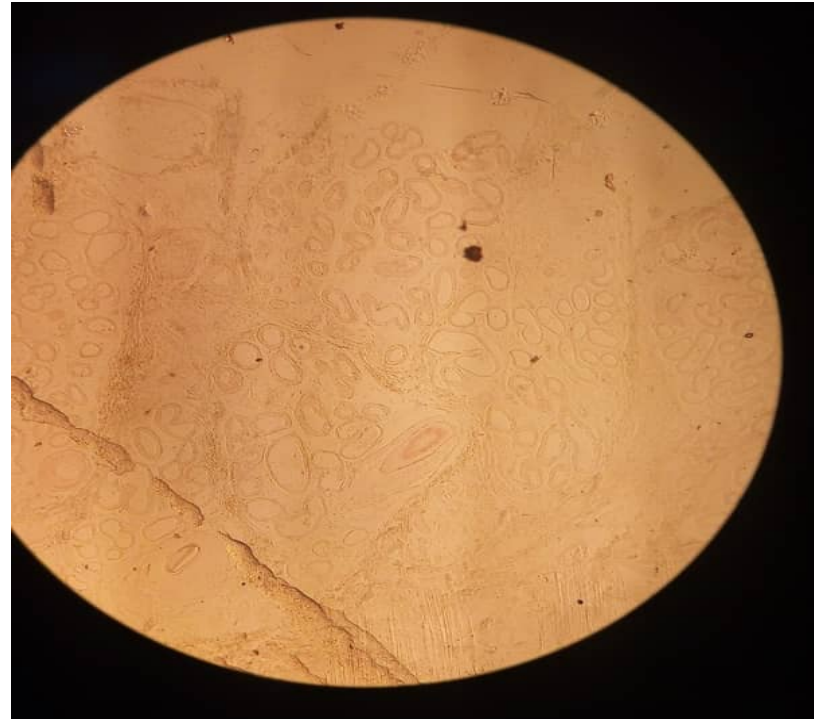
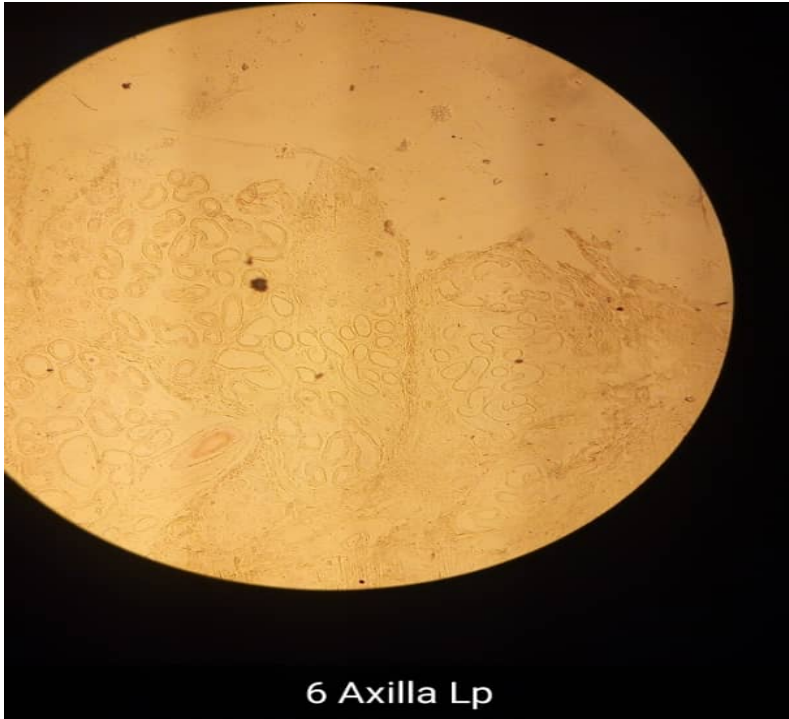
Thin skin sweat eccrine sweat gland duct



Sebaceous gland

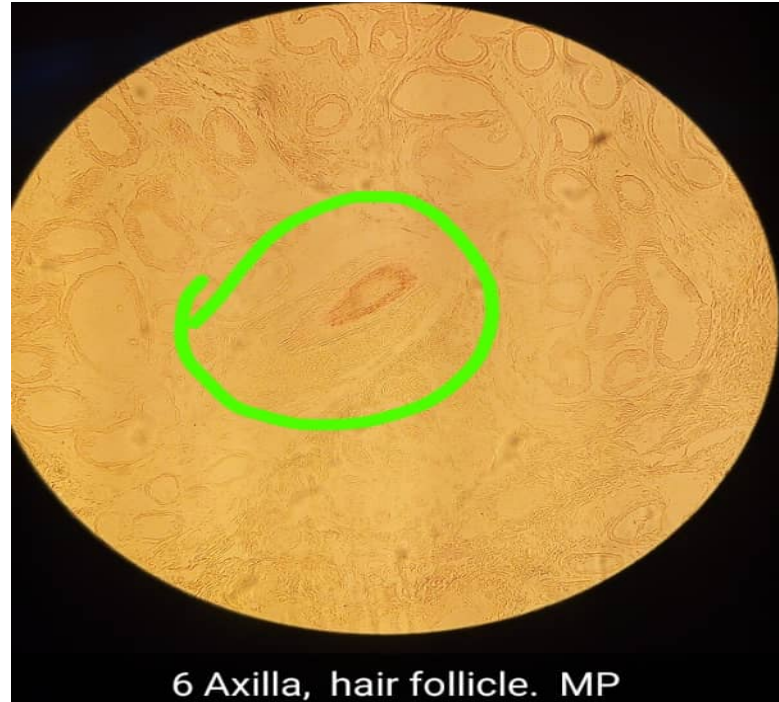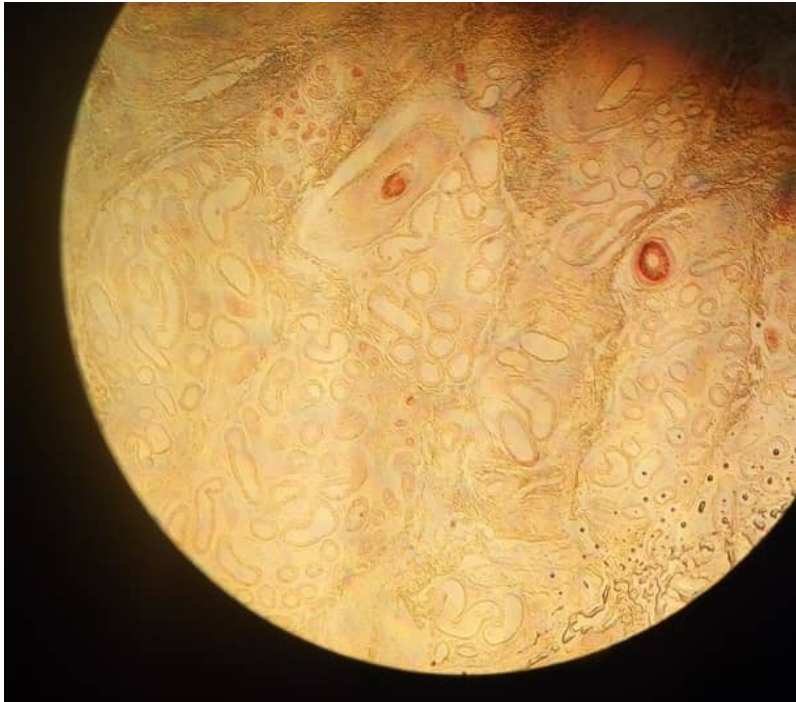# SLIDE 40 SKIN OF AXILLA ( H&E)

- LP



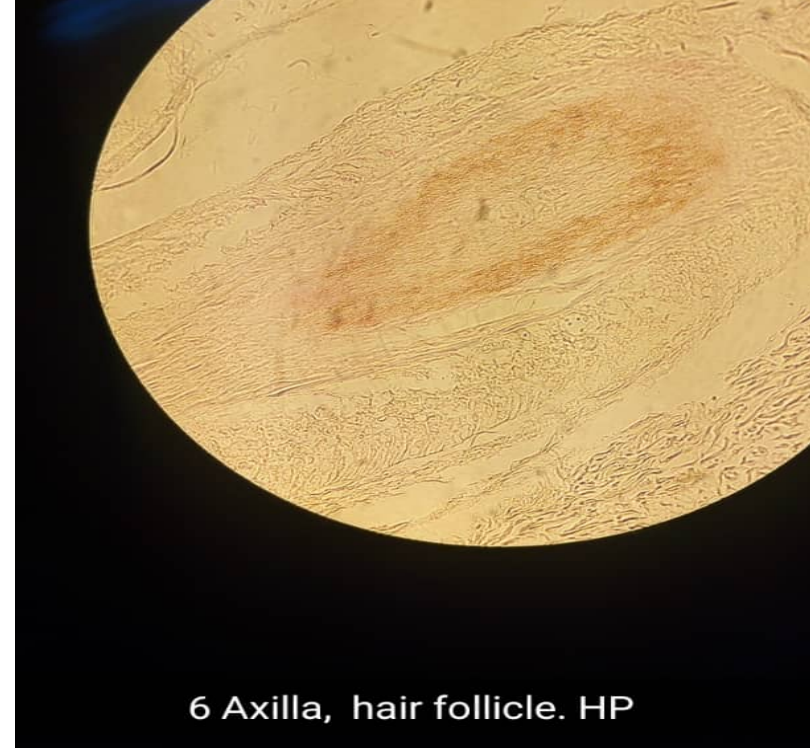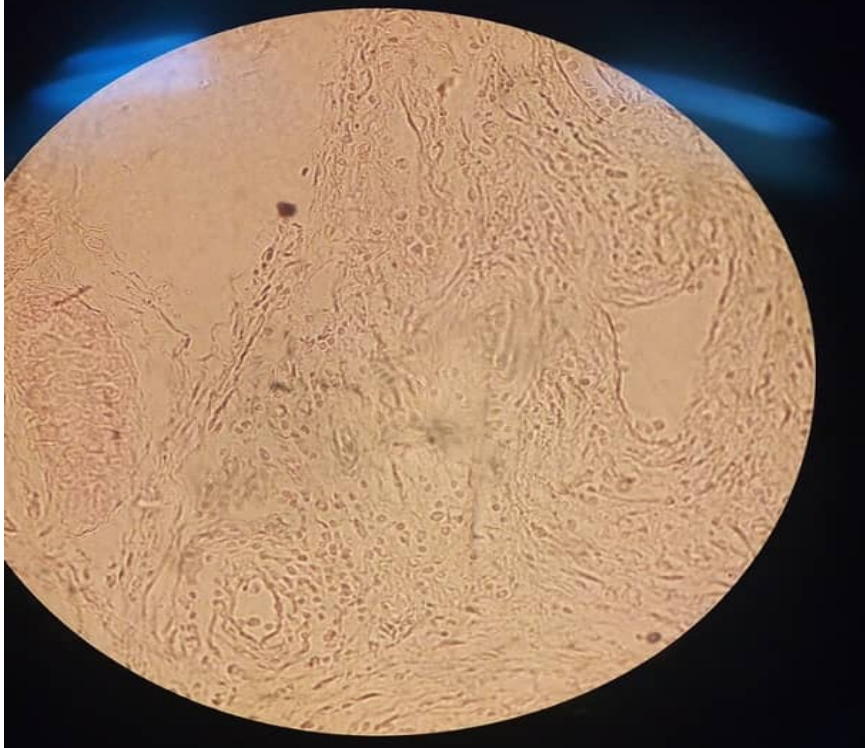
# SLIDE 40 SKIN OF AXILLA ( H&E)

- MP



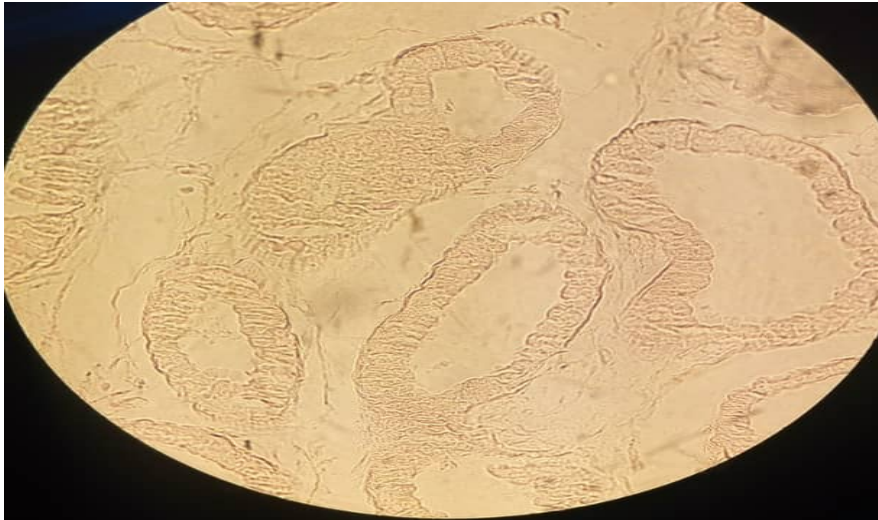
# SLIDE 40 SKIN OF AXILLA ( H&E)

- HP

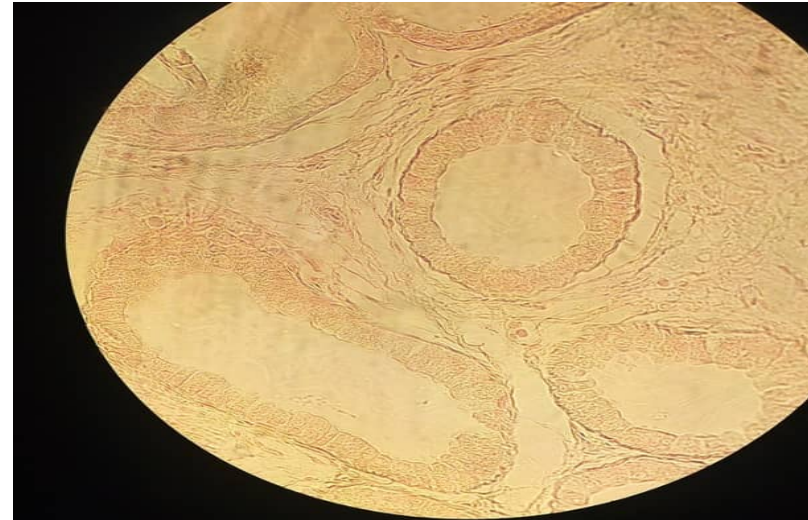


# SLIDE 40 SKIN OF AXILLA ( H&E)

- HP



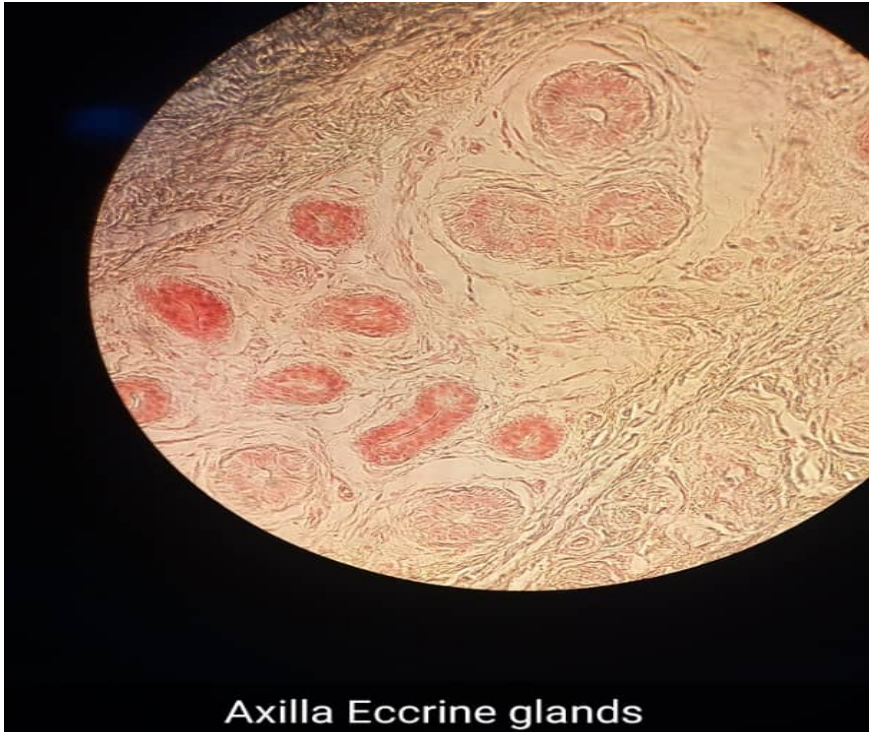6 Axilla, glands. HP



Axilla Apocrine glands HP

# SLIDE 40 SKIN OF AXILLA ( H&E)

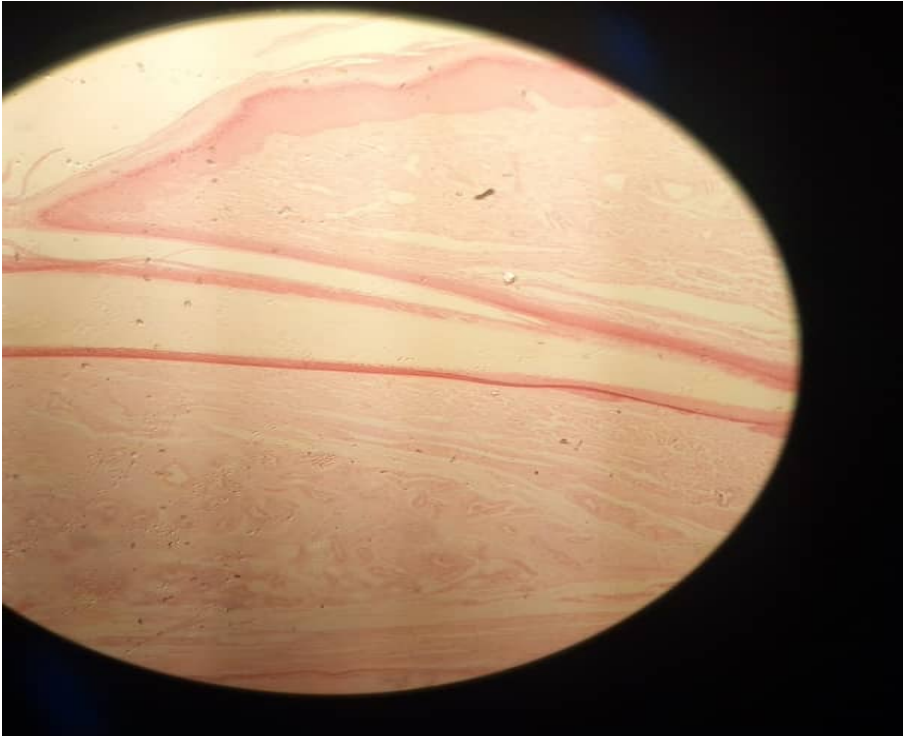
- HP



Axilla Eccrine glands

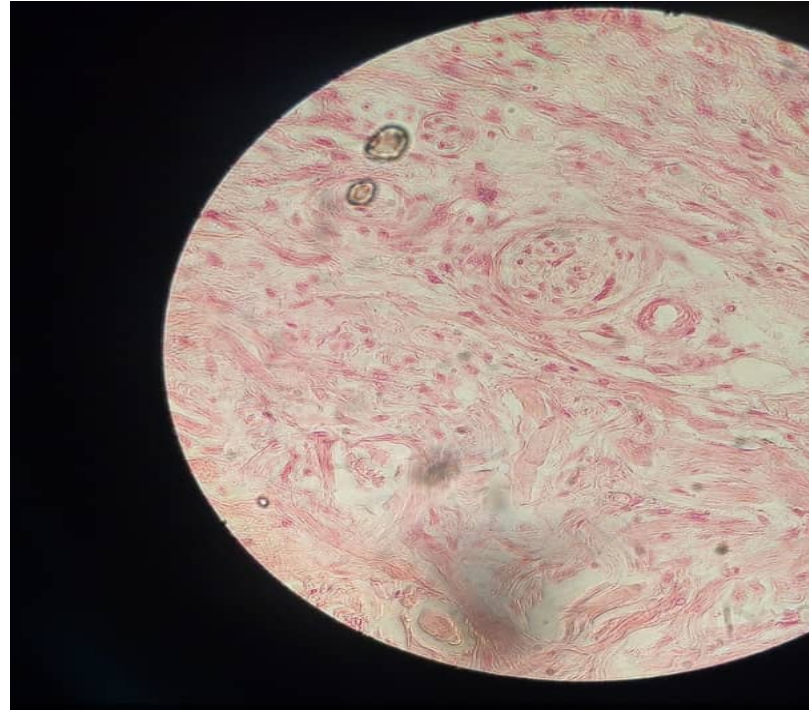
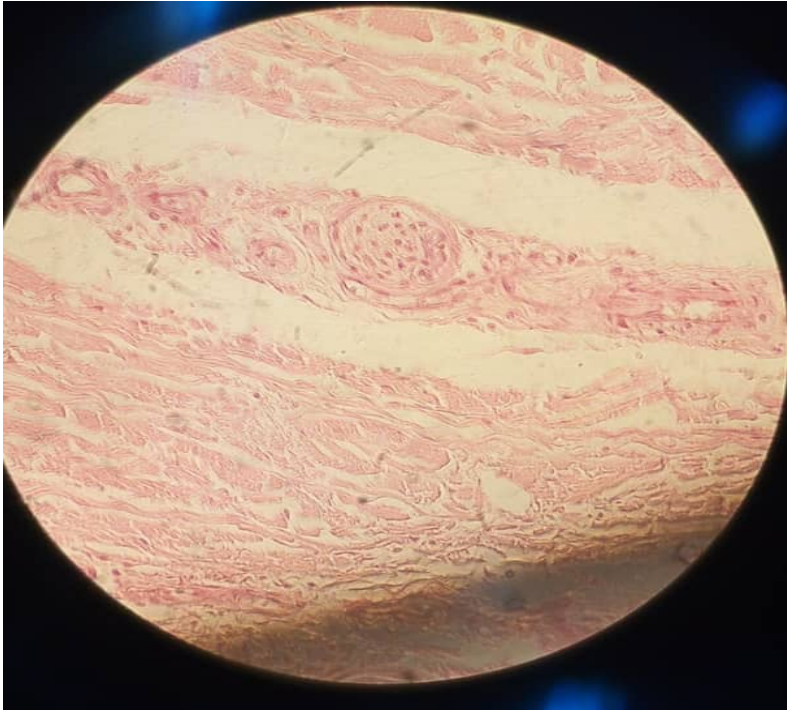
# SLIDE 11.36 NAIL, LS (FINGER OR TOE)

- LP



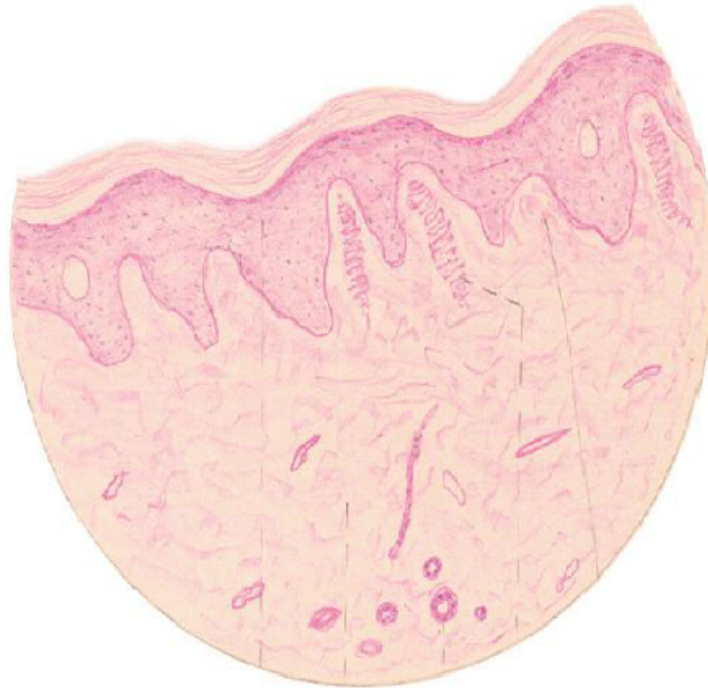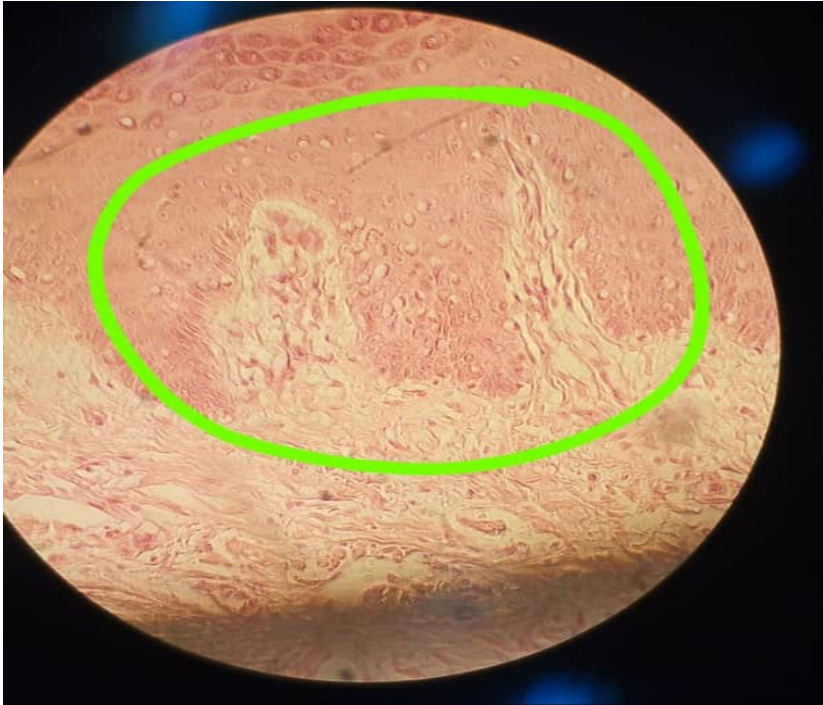# SLIDE 11.36 NAIL, LS (FINGER OR TOE)

- HP, LAMELLATED OR PANCINIAN CORPUSCLES



# SLIDE 11.36 NAIL, LS (FINGER OR TOE)

- HP, MEISSNER'S CORPUSCLES



# **PRACTICAL 20: MALE REPRODUCTIVE SYSTEM**

**PRESENTER: ROZALIA NJOBVU**

# Male reproductive system

- Responsible for production of *spermatozoa* and their delivery into female reproductive tract; Divided four major functional areas;
- Testis
- Ducts
- Seminal vesicles and Prostate gland
- Penis.

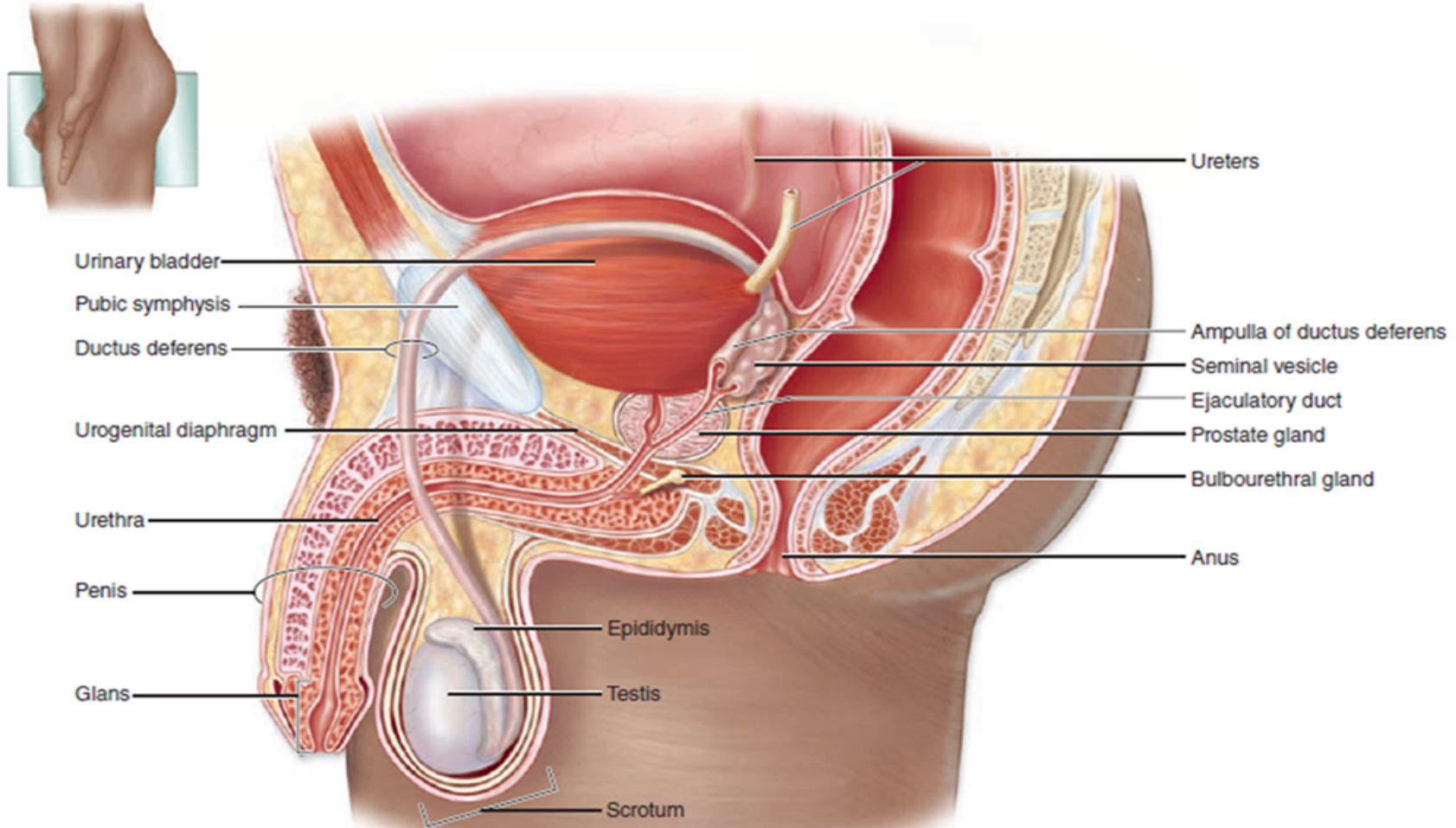
# Function of Male Reproductive organs

- **1. *Testes*** or male gonads, paired organs lying in the ***scrotal sac***, responsible for production of the male gametes, ***spermatozoa***, and secretion of male sex hormones, principally ***testosterone***.
- **2. A system of ducts - *ductuli efferentes, epididymis, ductus (vas) deferens* and *ejaculatory duct***;
- Stores and carries spermatozoa from each testis.
- Ejaculatory ducts converge on the urethra, where spermatozoa are expelled into female reproductive tract during copulation.

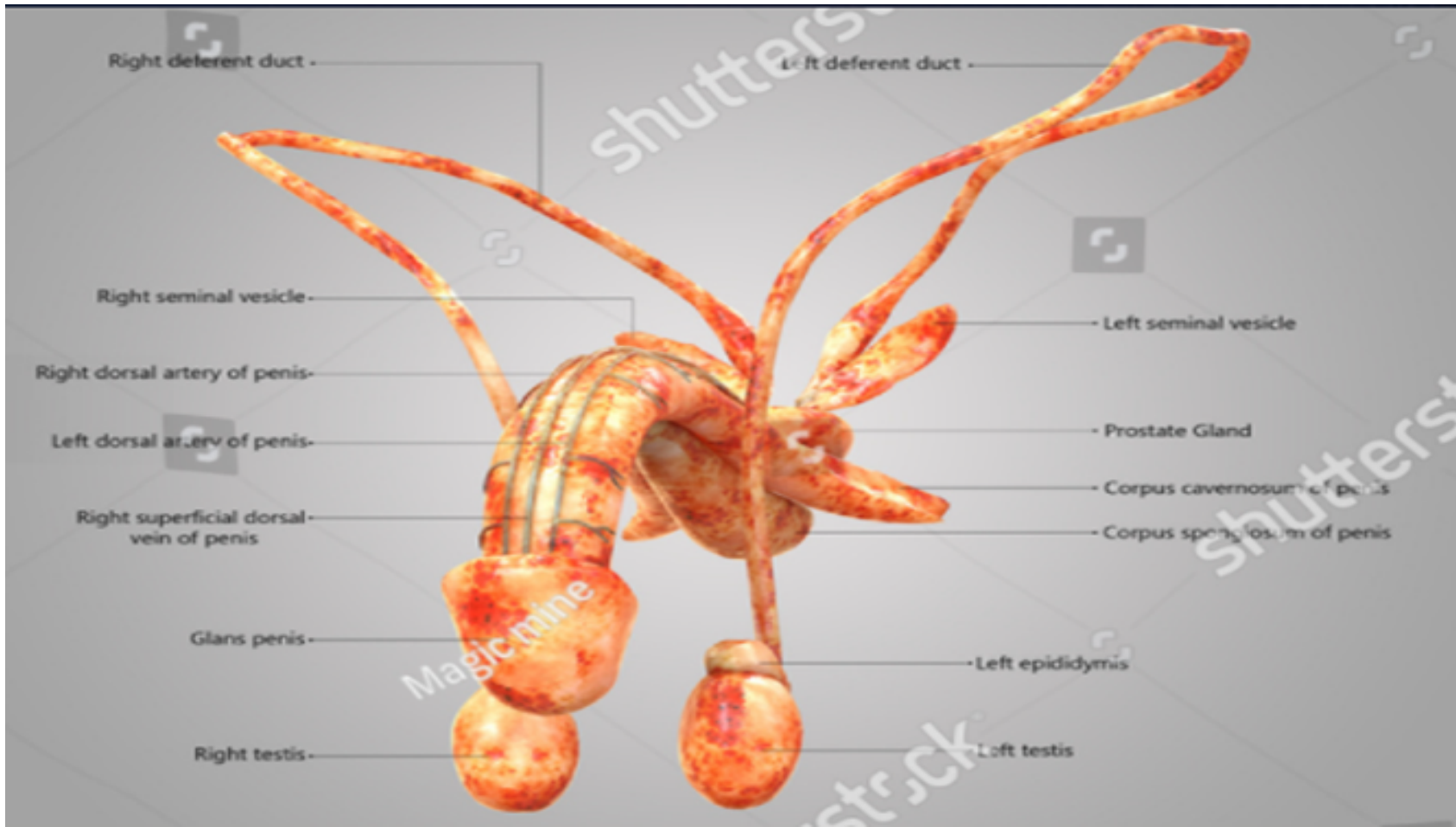
# Contd

- **3. Paired seminal vesicles** and single **prostate gland**, secrete a nutritive and lubricating fluid - **seminal fluid** where spermatozoa are conveyed to female reproductive tract. **Semen**, fluid expelled during ejaculation, consists of seminal fluid, spermatozoa, and some desquamated duct lining cells.
- **4. Penis** organ of copulation, pair of small **bulbourethral glands of Cowper**, secrete lubricating fluid - passage of semen at ejaculation.

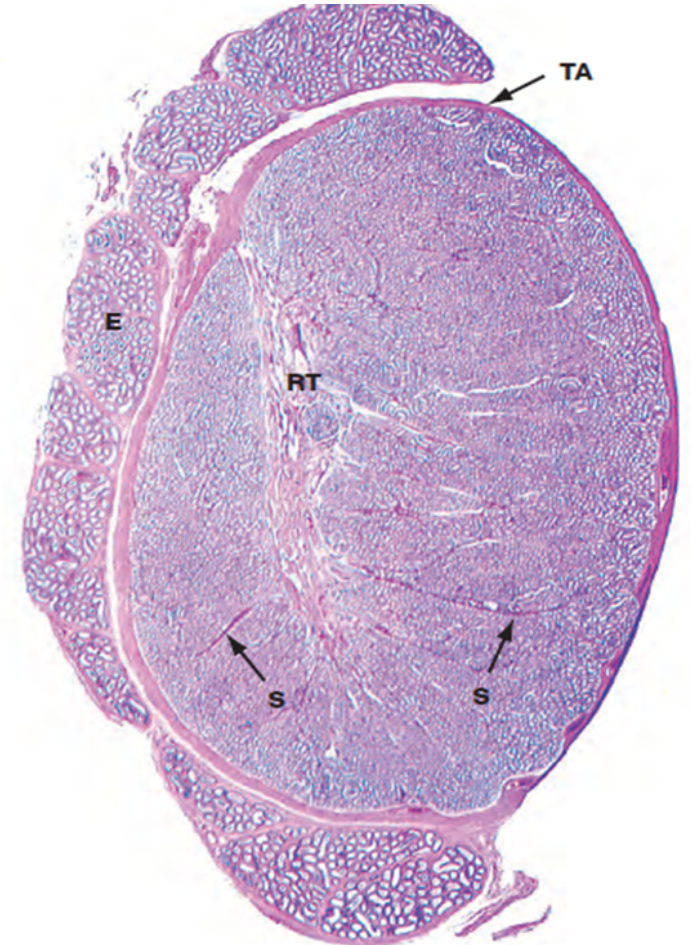
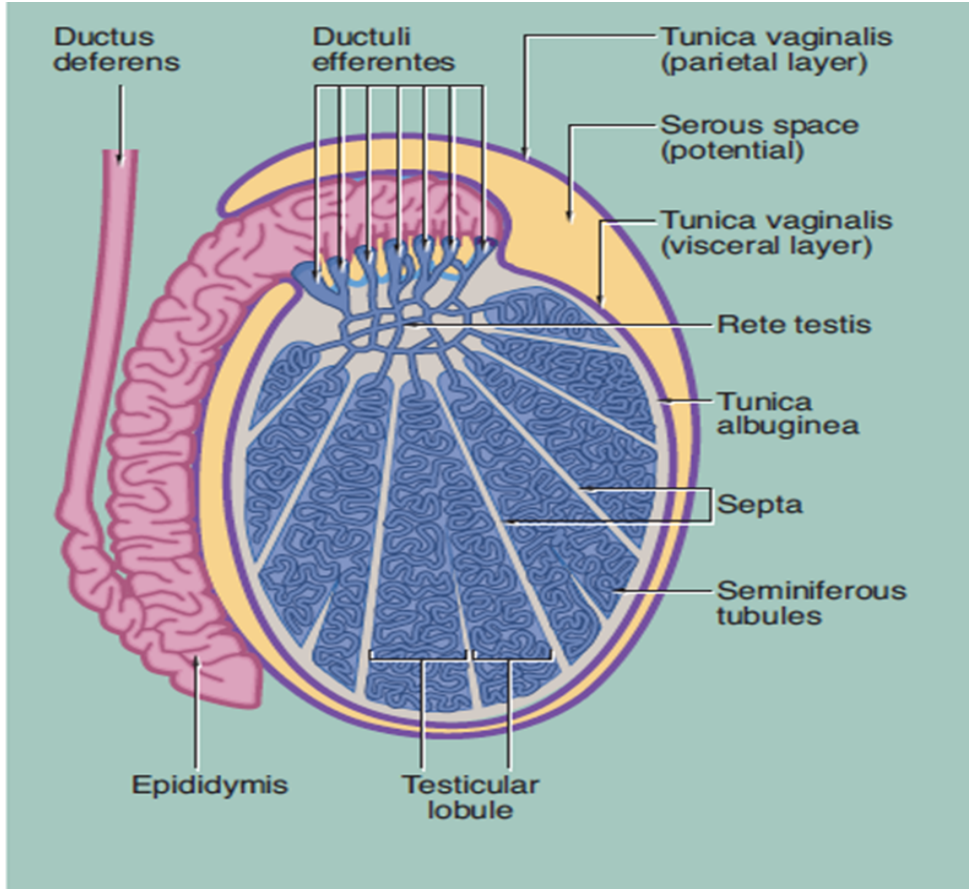
# Male reproductive organs



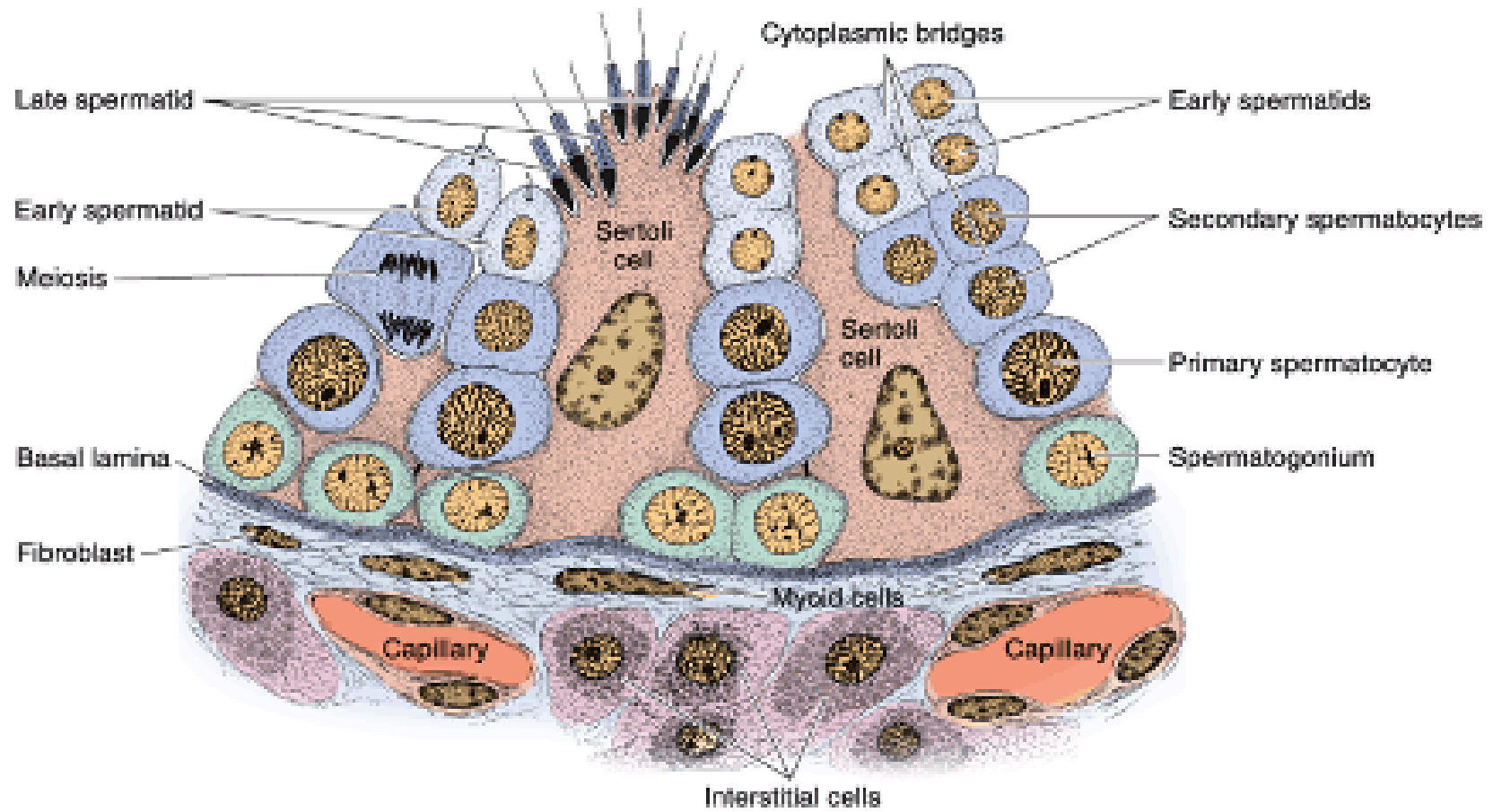
# Male reproductive organs



# Testis

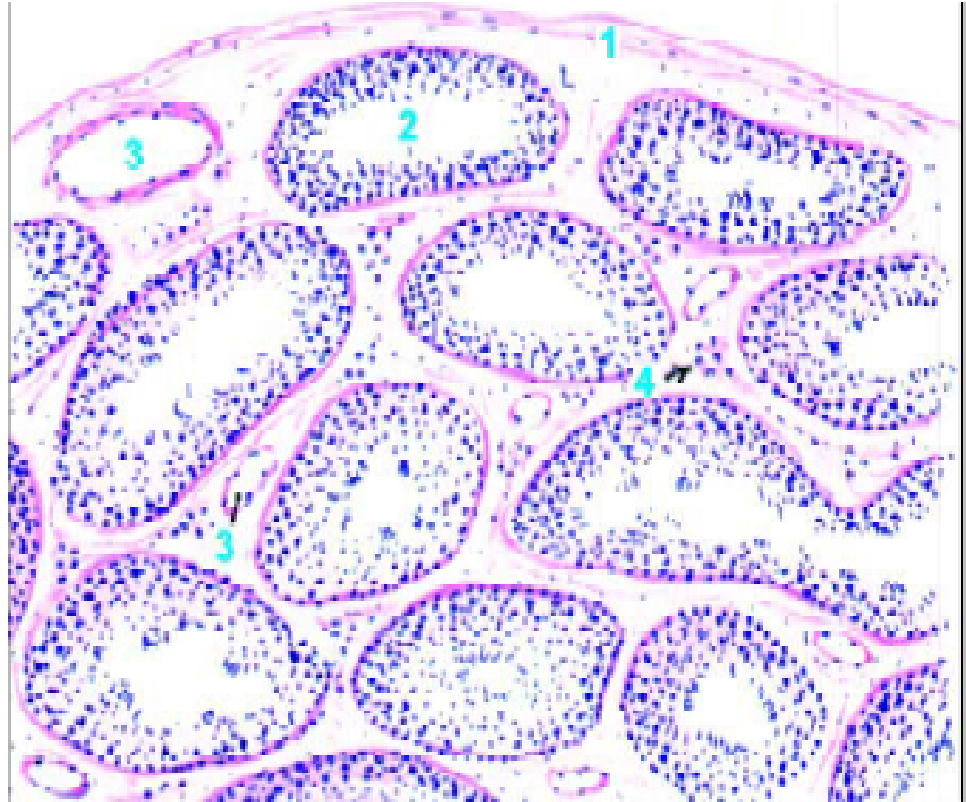


# Spermatogenic cells

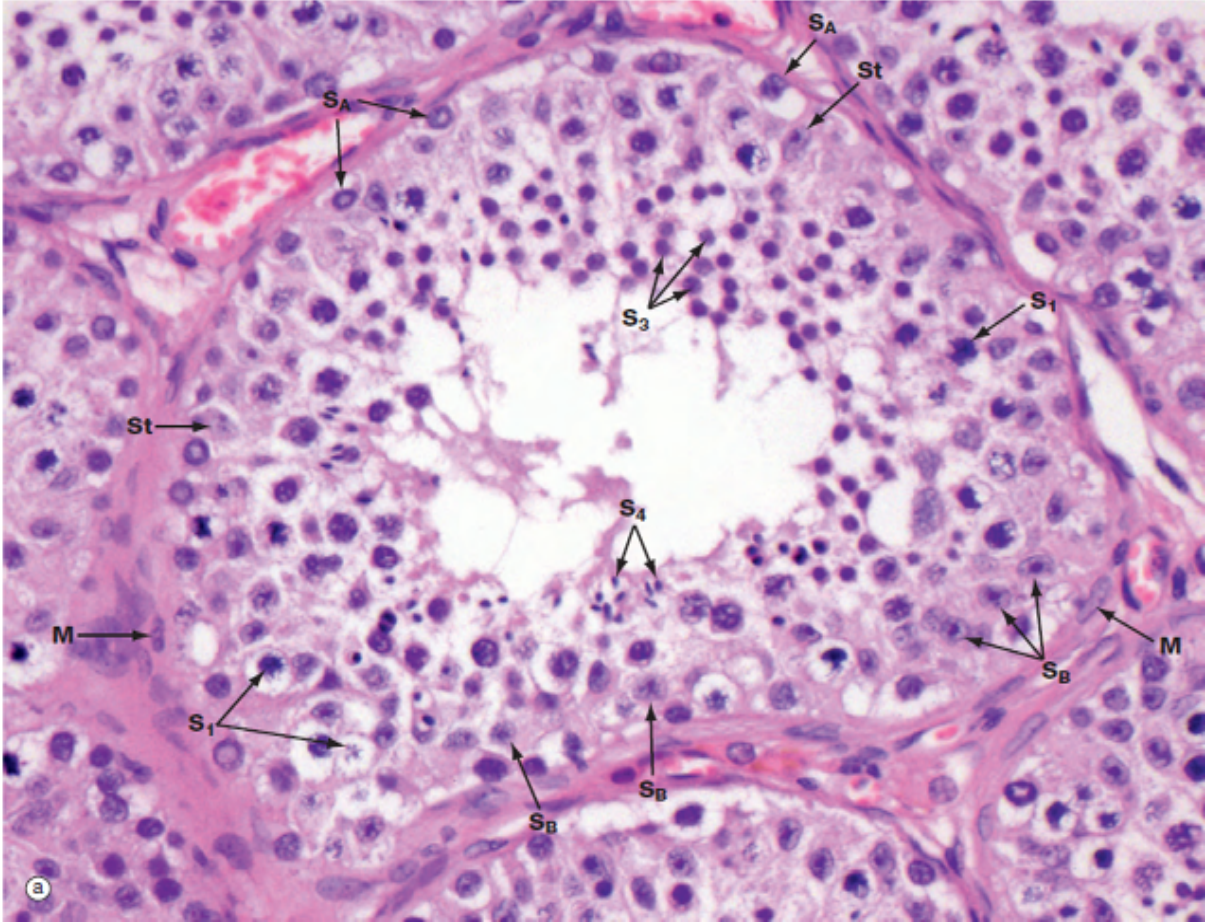


# Testis drawing LP.

- 1-Tunica albuginea.
- 2-Seminiferous tubule.
- 3-Blood vessel.
- 4-Interstitial cells (leydig cells – clusters).



# Slide H9.411: Testis Human (H&E) HP -

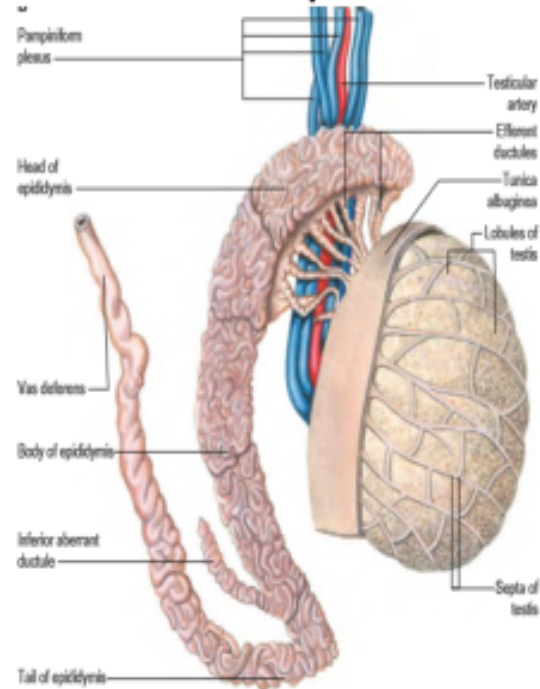


# Key for identifying testis

- 1. A large number of seminiferous tubules seen
- 2. Spermatogenic cells and sertoli cells seen
- 3. Presence of leydig cells – in clusters in between seminiferous tubules

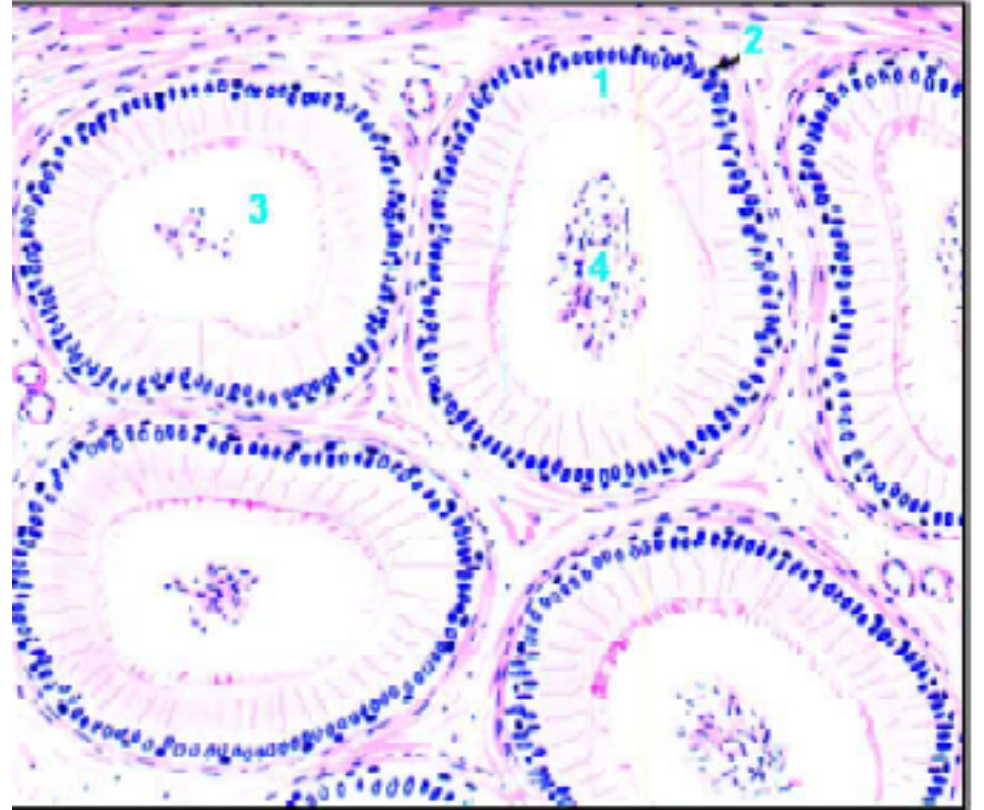
# Epididymis – 4-5 m Maturation of spermatozoa

Epididymis- comma shaped elongated

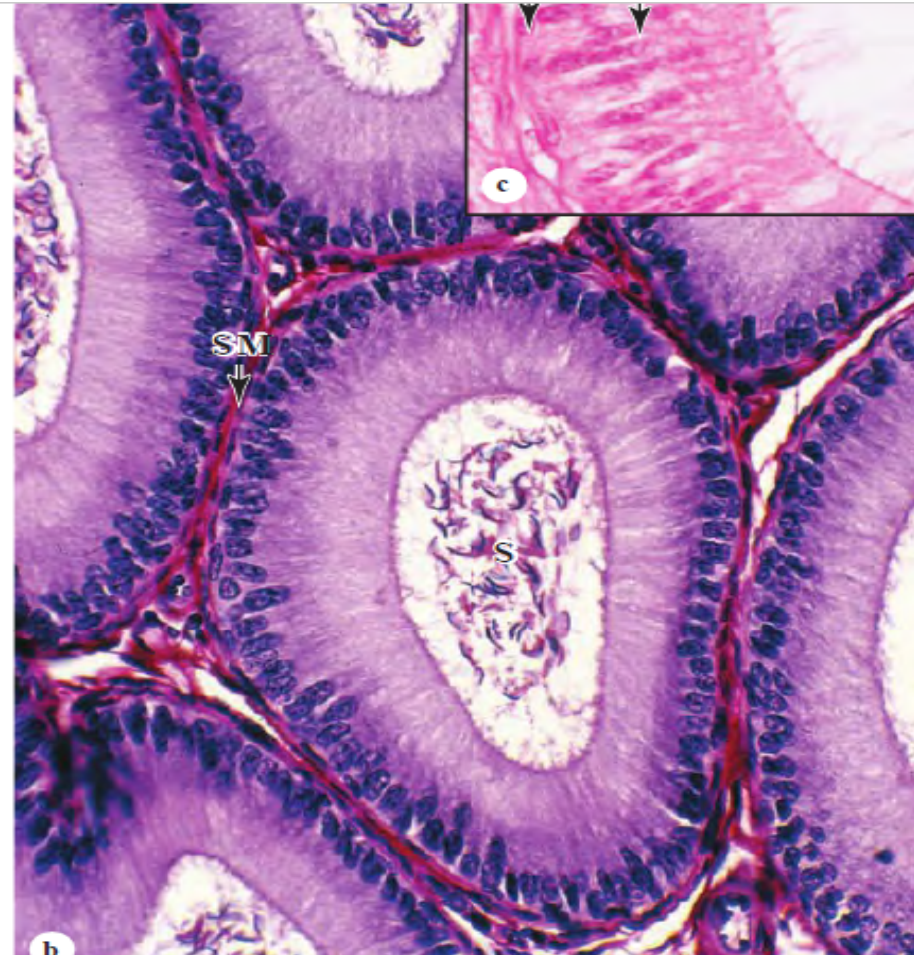
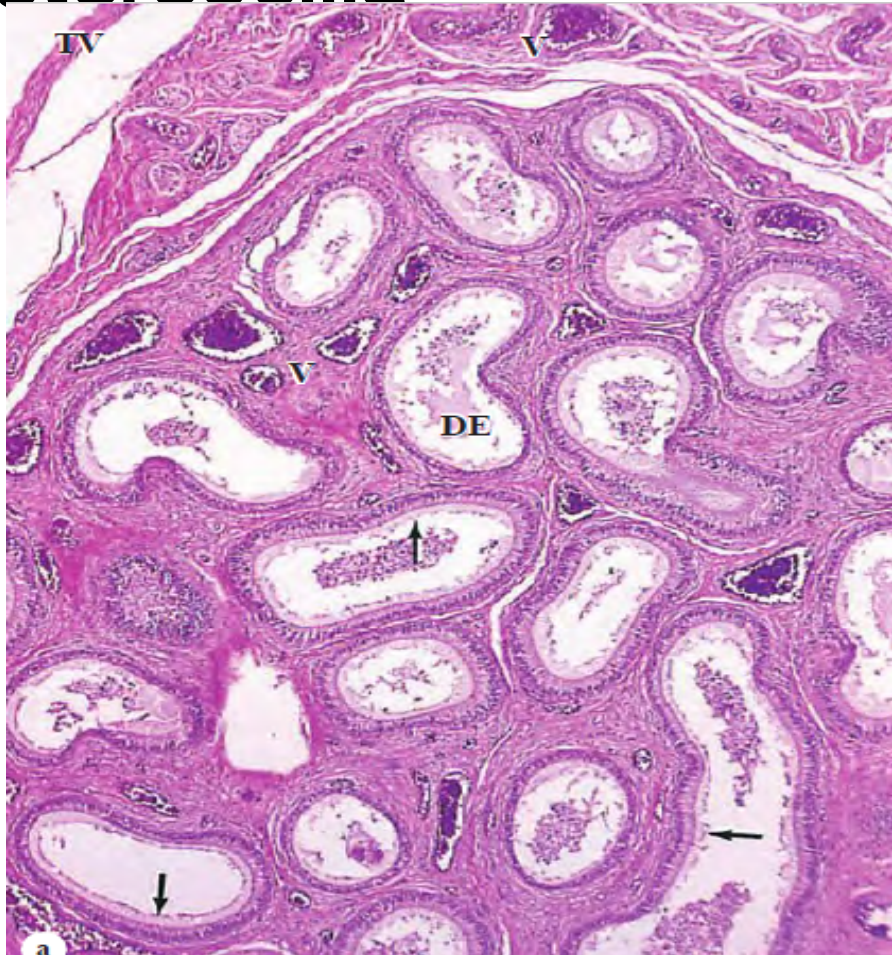

# Fig. 18.9. Epidydimis (drawing).

- 1-Lining of tall columnar cells.
- 2-Basal cell.
- 3-Stereocilia.
- 4-Clump of spermatozoa.



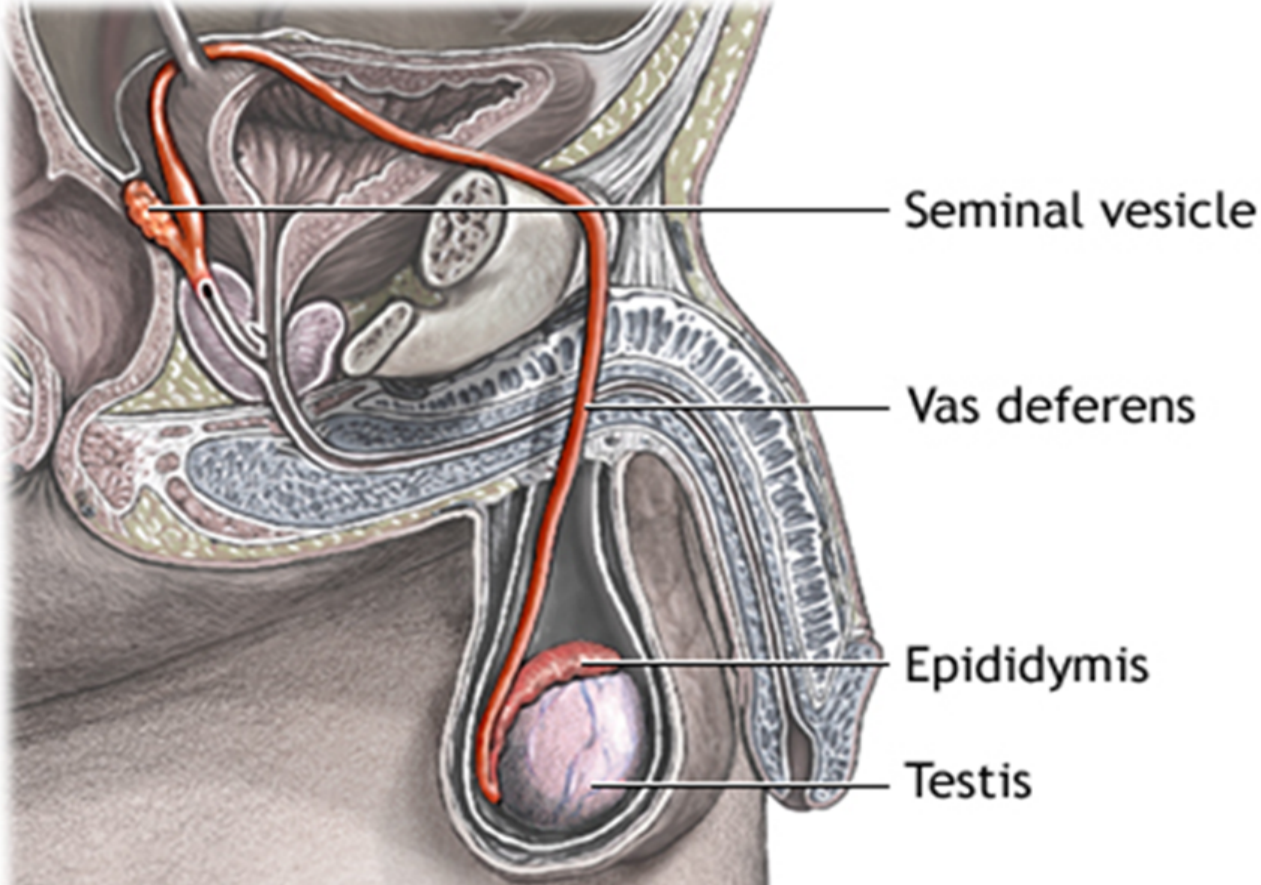
# Pseudostratified columnar epithelium - stereocilia



# Key for identifying Epididymis

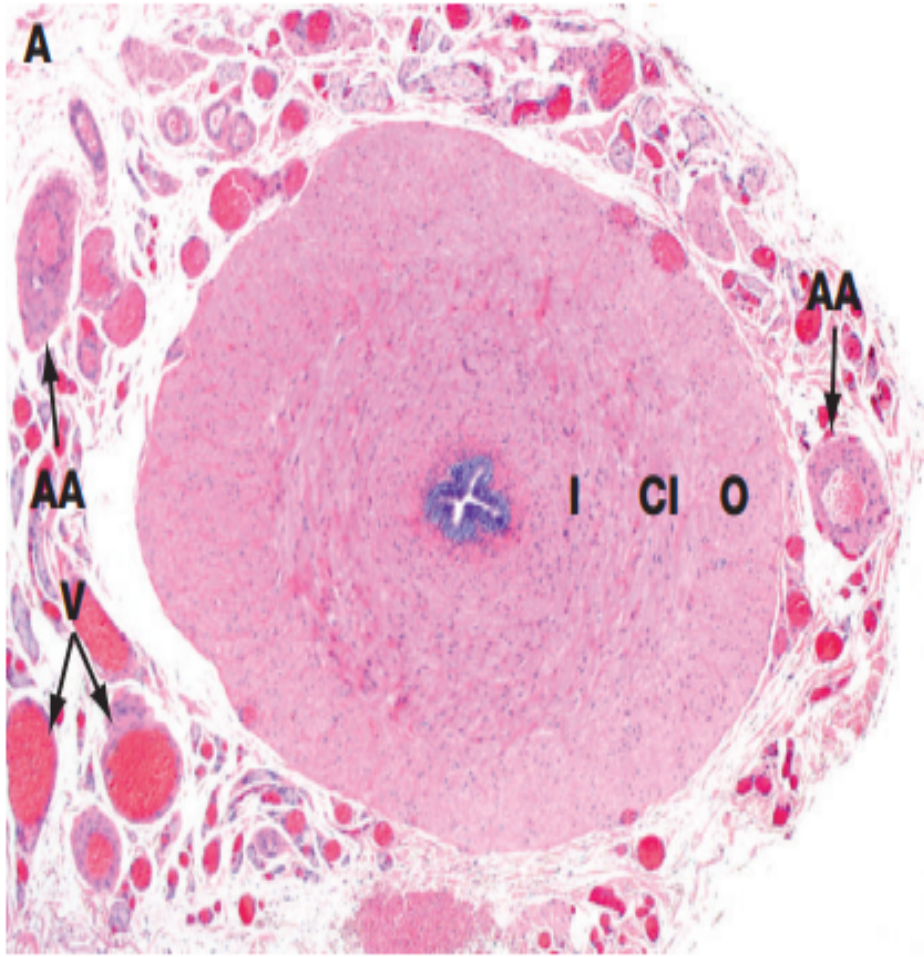
- Tubules lined with stereocilia – Two types of cells seen;
- 1. Columnar with elongated nuclei secretory in nature –nourish sperms in lumen, Stereocilia absorbs testicular fluid, prevent capacitation of sperm in male reproductive system
- 2. Basal cells – with round nucleus close to basement membrane
- In the lumen sperms are seen
- Smooth muscles fibres surround the tubules

# Vas deferens – Parts



# Histology- mucosa, Lamina Propria, muscularis, & adventicia NB: No Submucosa!

- Narrow lumen and a thick layer of smooth muscle.
- Mucosa is folded longitudinally, lined along most of its length by **pseudostratified columnar epithelium** with **sparse stereocilia**.
- The **lamina propria** is rich in **elastic fibers** and the very **thick muscularis** consists of **longitudinal inner and outer layers** and a **middle circular layer**.
- The muscles produce strong peristaltic contractions during ejaculation which rapidly move sperm along this duct from the epididymis.



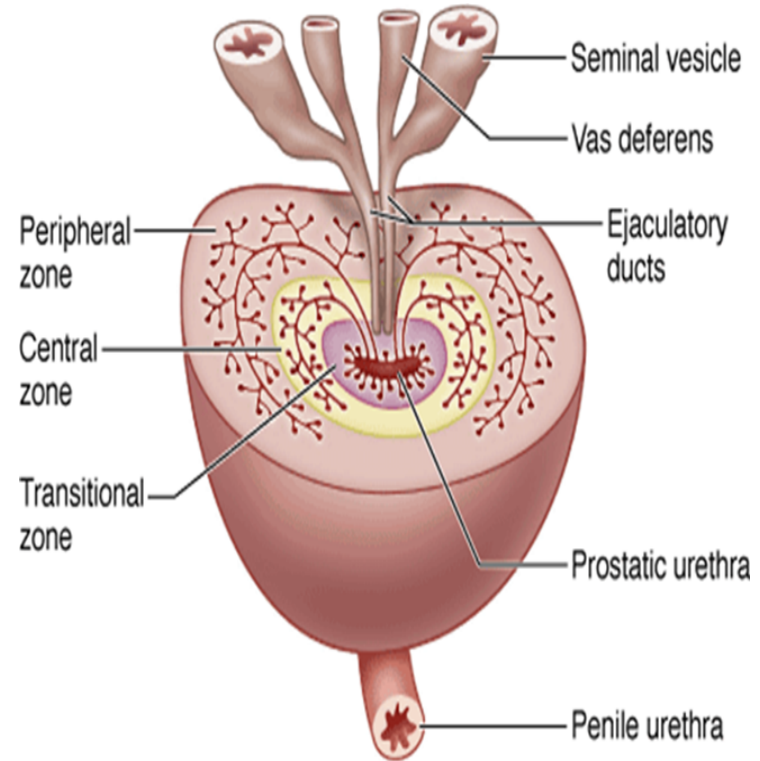
- The *vas* (or *ductus*) *deferens*, which conducts spermatozoa from the epididymis to the urethra, is a thick-walled muscular tube consisting of inner **I** and outer **O** longitudinal layers and a thick intermediate circular layer **CI**.

# Slide H9. 431 Vas deferens Human H&E

- Lined by a pseudostratified columnar epithelium similar to that of the epididymis;
- Epithelial lining and its supporting lamina propria are thrown into longitudinal folds permitting expansion of the duct during ejaculation.
- **Key for identifying Vas deferens**
- **1. Pseudostratified columnar epithelium with sparse stereocilia.**
- 2. Thick muscle coat
- 3. Stellate lumen – Small and irregular lumen

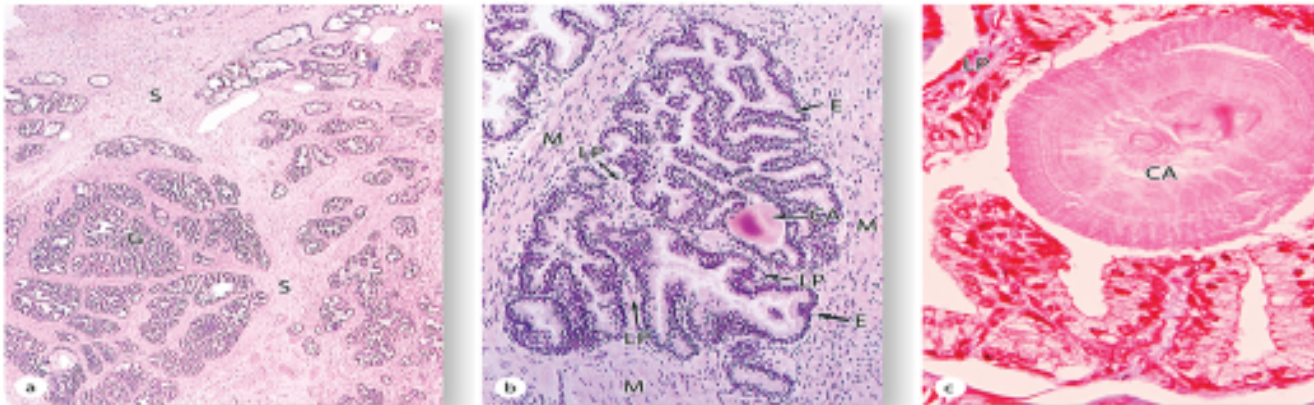
# Prostate Gland

- Anatomically; glandular tissue subdivided into three distinct zones:
- Peripheral (70% by volume)
- Central (25% by volume)
- Transitional (5% by volume)
- Non-glandular tissue (fibromuscular stroma) fills up space between peripheral zones anterior to the preprostatic urethra

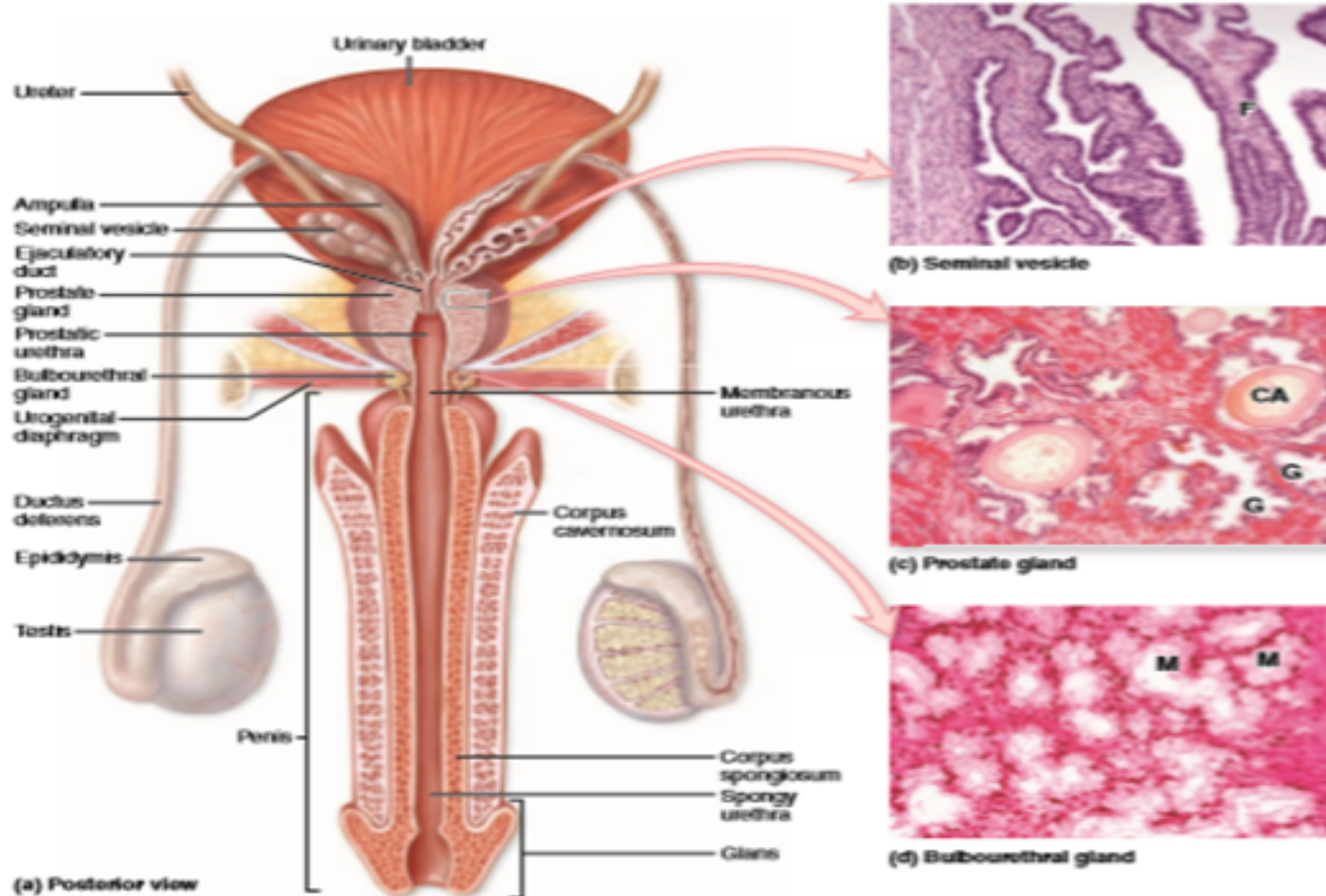


# Slide 81: Prostate gland (Mallory- Azan)

## Prostate gland - Histology



# Prostate gland

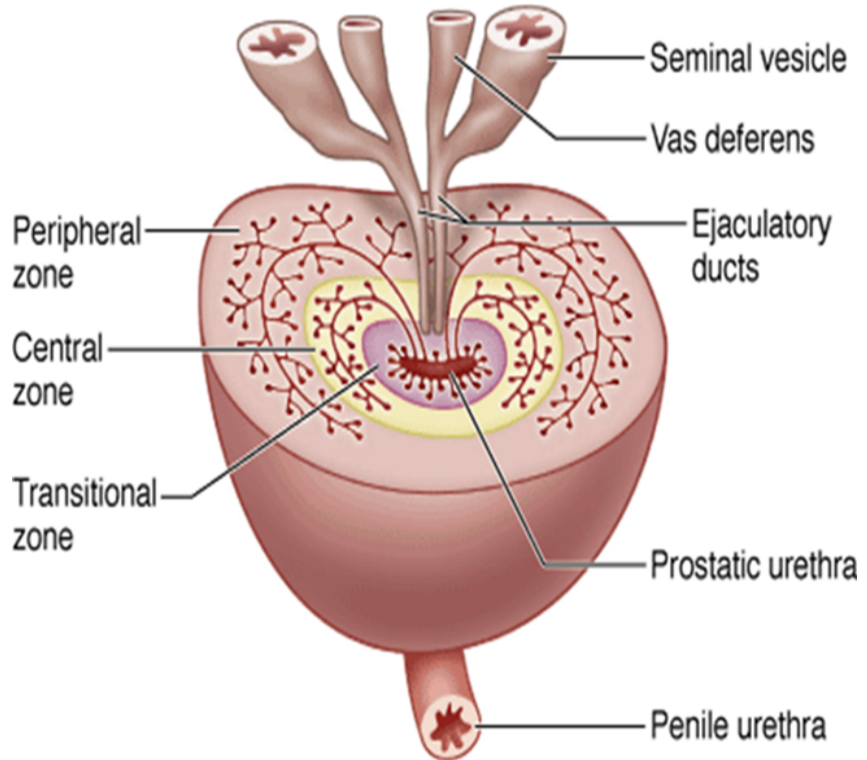


# Key for identifying Prostate gland

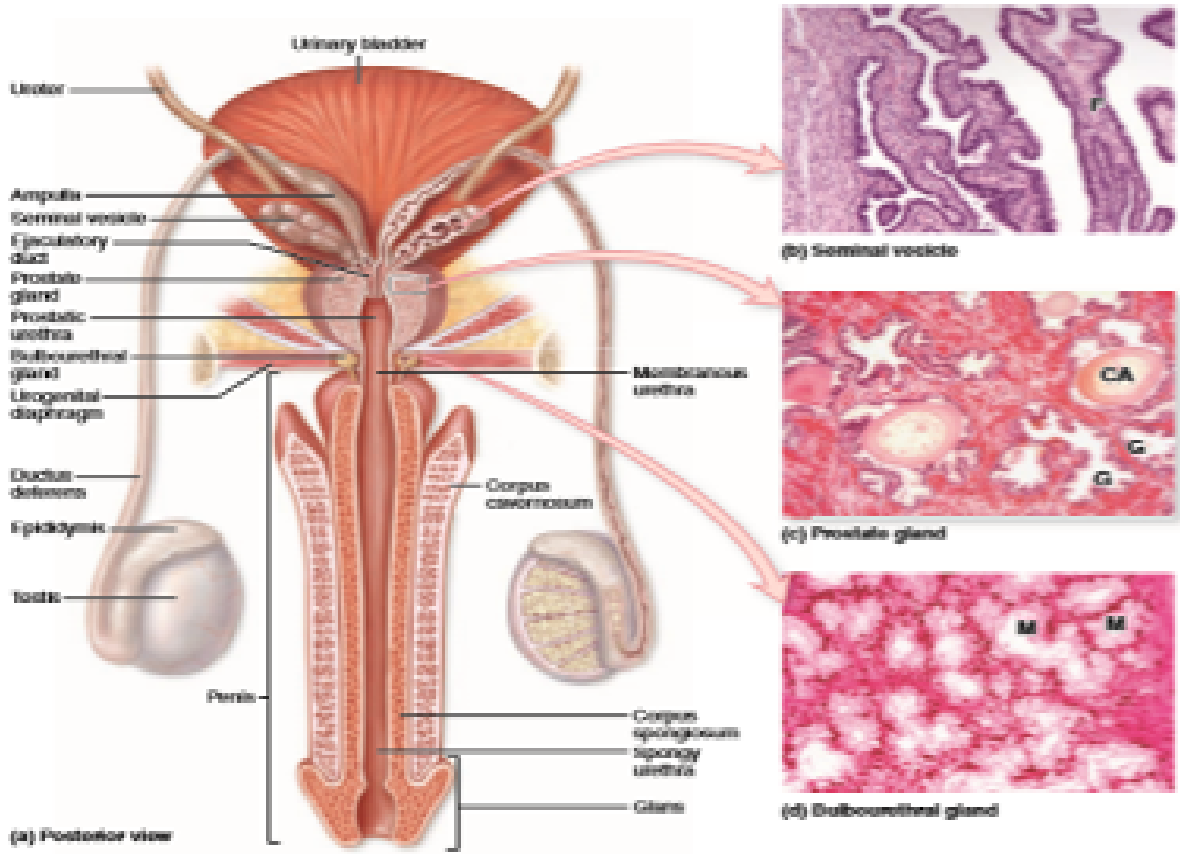
- 1. Irregular acini with epithelium folded inwards seen
- 2. Stroma is of fibromuscular
- 3. Acini are filled with corpora amylacea

# Slide H9. 422: Seminal vesicle (H&E)-Tightly closed tube, many recesses seen - honey comb.

- Complex glandular dicentriculum of ductus deferens. Secretes up to 85% of seminal fluids into ductus deferens – an alkaline fluid – neutralizes acid in the vagina, fructose provides energy for sperm, prostaglandins increase sperm viability & stimulate female uterine contraction – help sperm move into uterus.



# Slide H9. 422 Seminal vesicle (H&E)



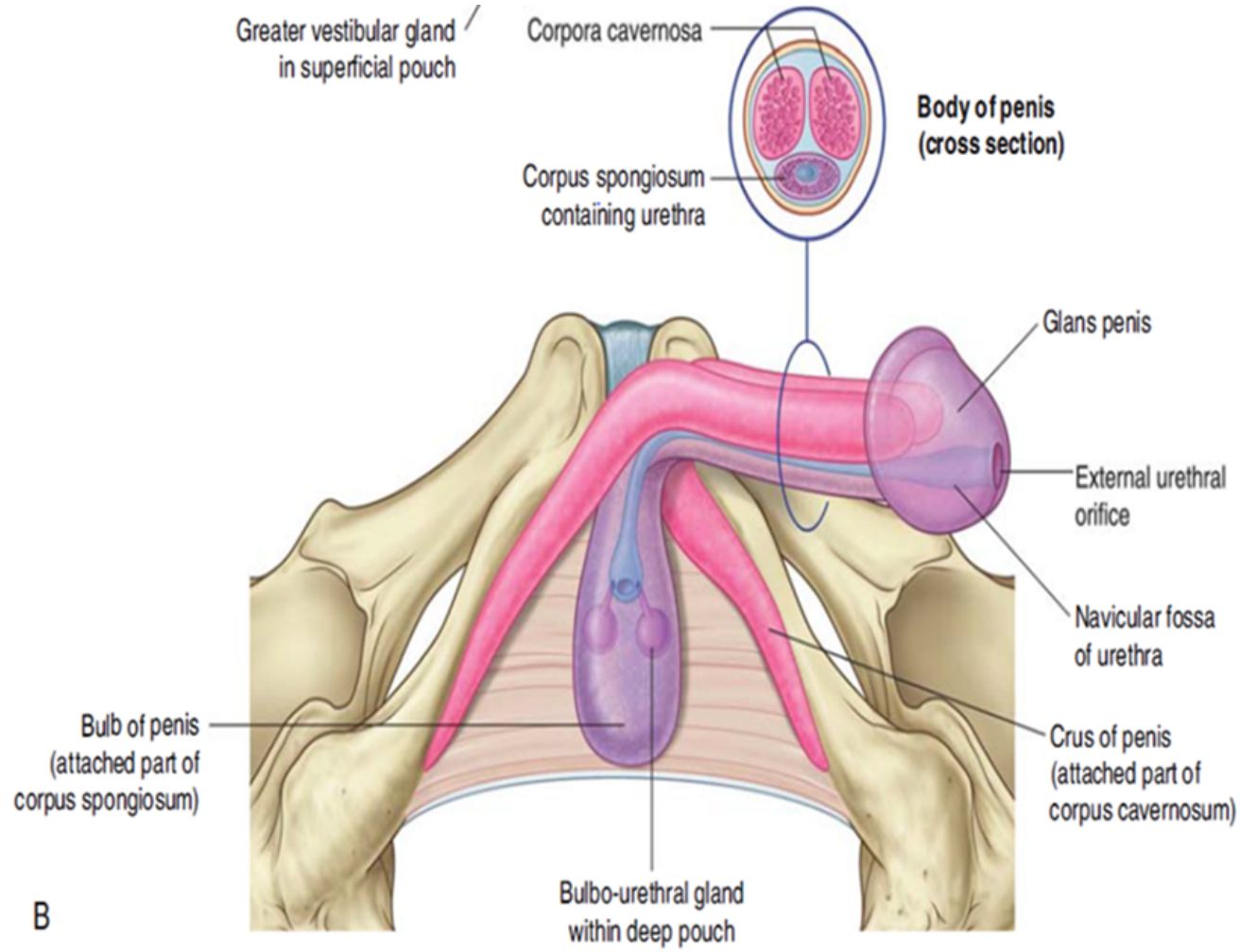
# Key for identifying Seminal vesicle slide

- 1. Mucosa is highly branched having anastomosing folds
- 2. No sperm in the lumen
- 3. Well developed muscle layer

# Penis

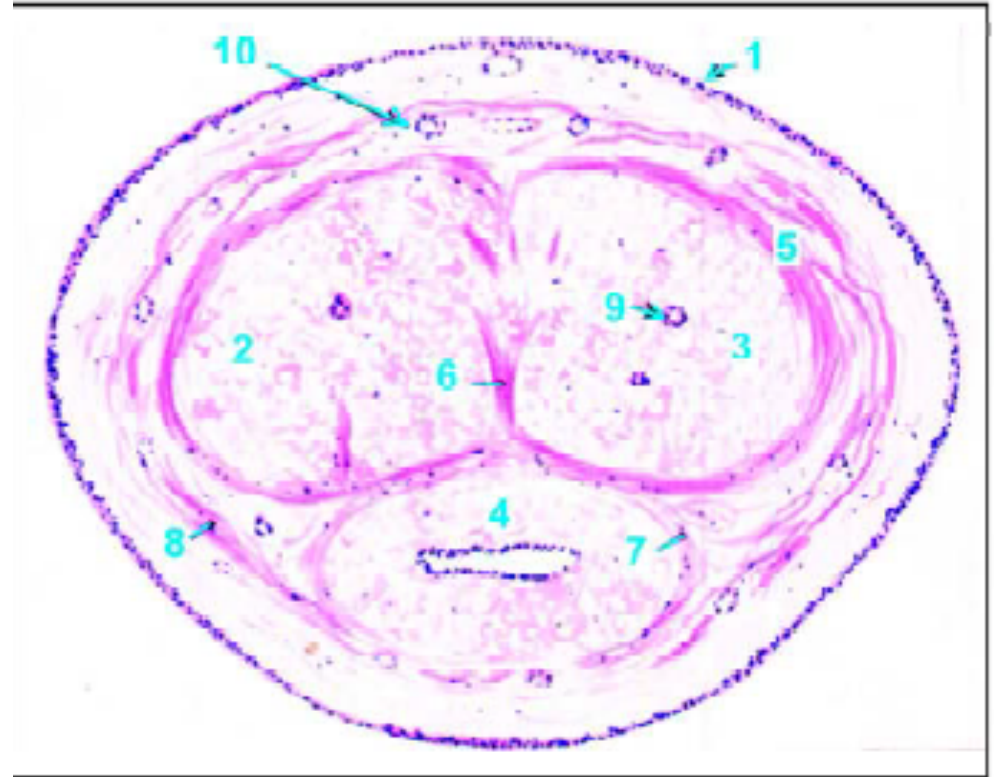
- Attached root (radix) in the perineum and a free pendulous body (corpus) which is completely enveloped in skin.

# Slide 84: Penis Monkey (H & E)

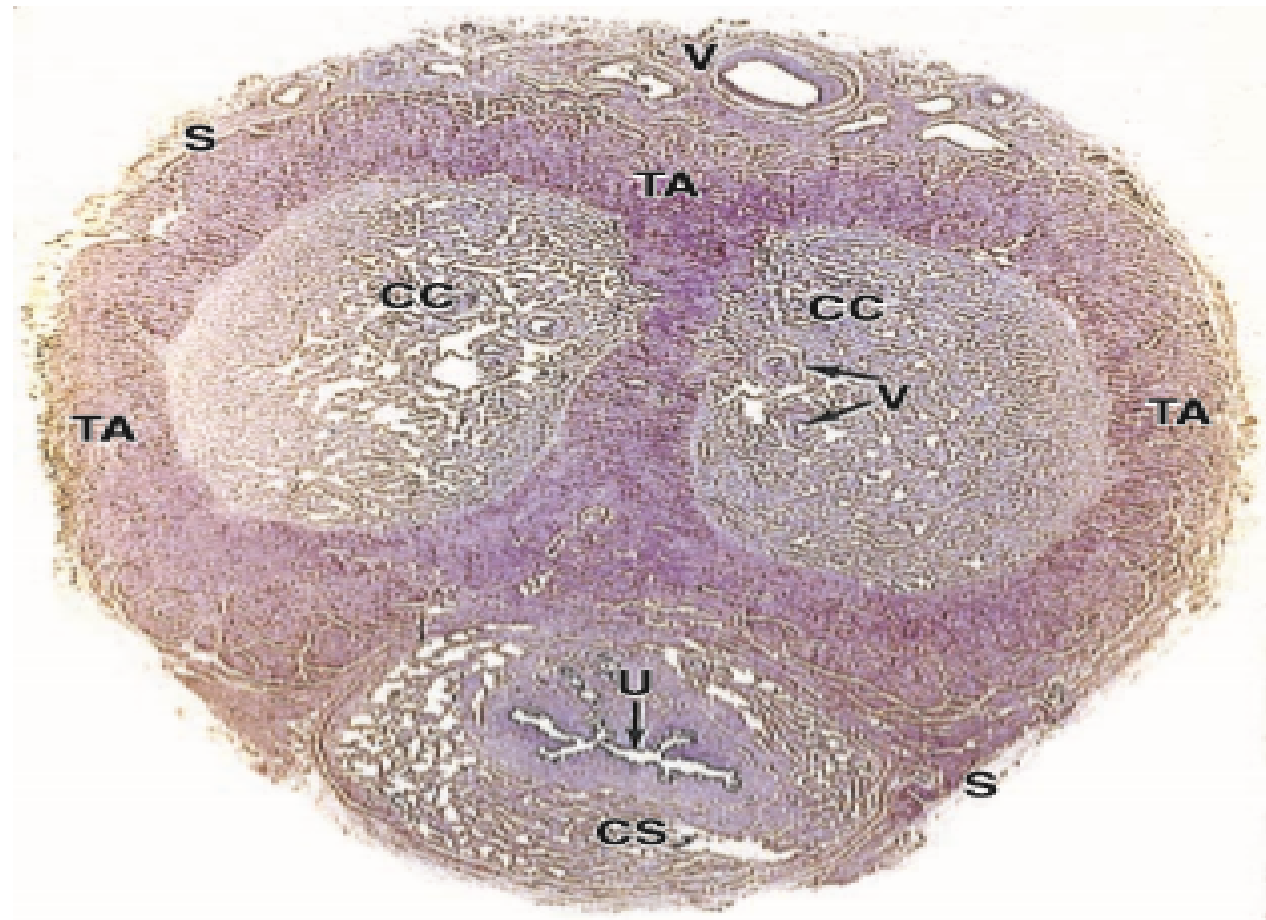


# Penis

- 1-Skin.
- 2, 3, 5-Corpora cavernosa and sheaths for them.
- 6-Median septum.
- 4,7-Corpus spongiosum and its sheath.
- 8-Common sheath.
- 10-Dorsal artery.



# Penis - Slide

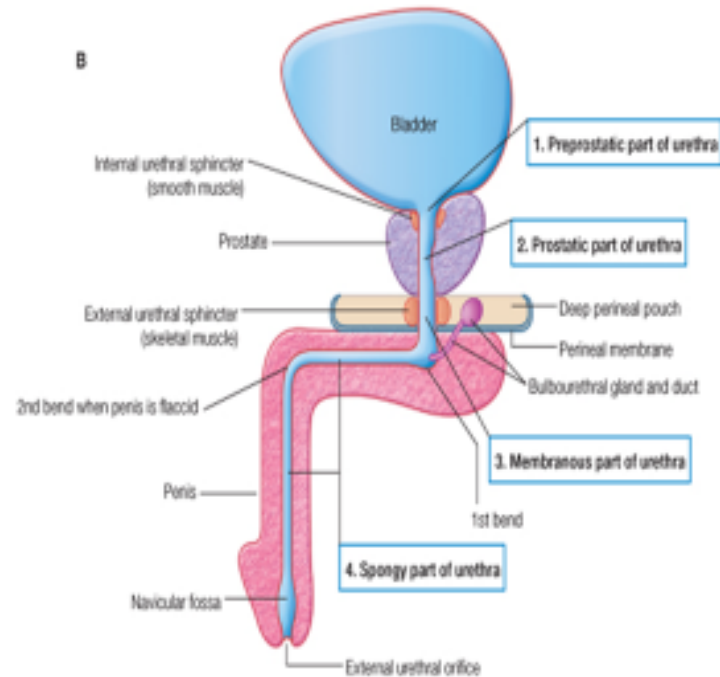


# Key for identifying Penis

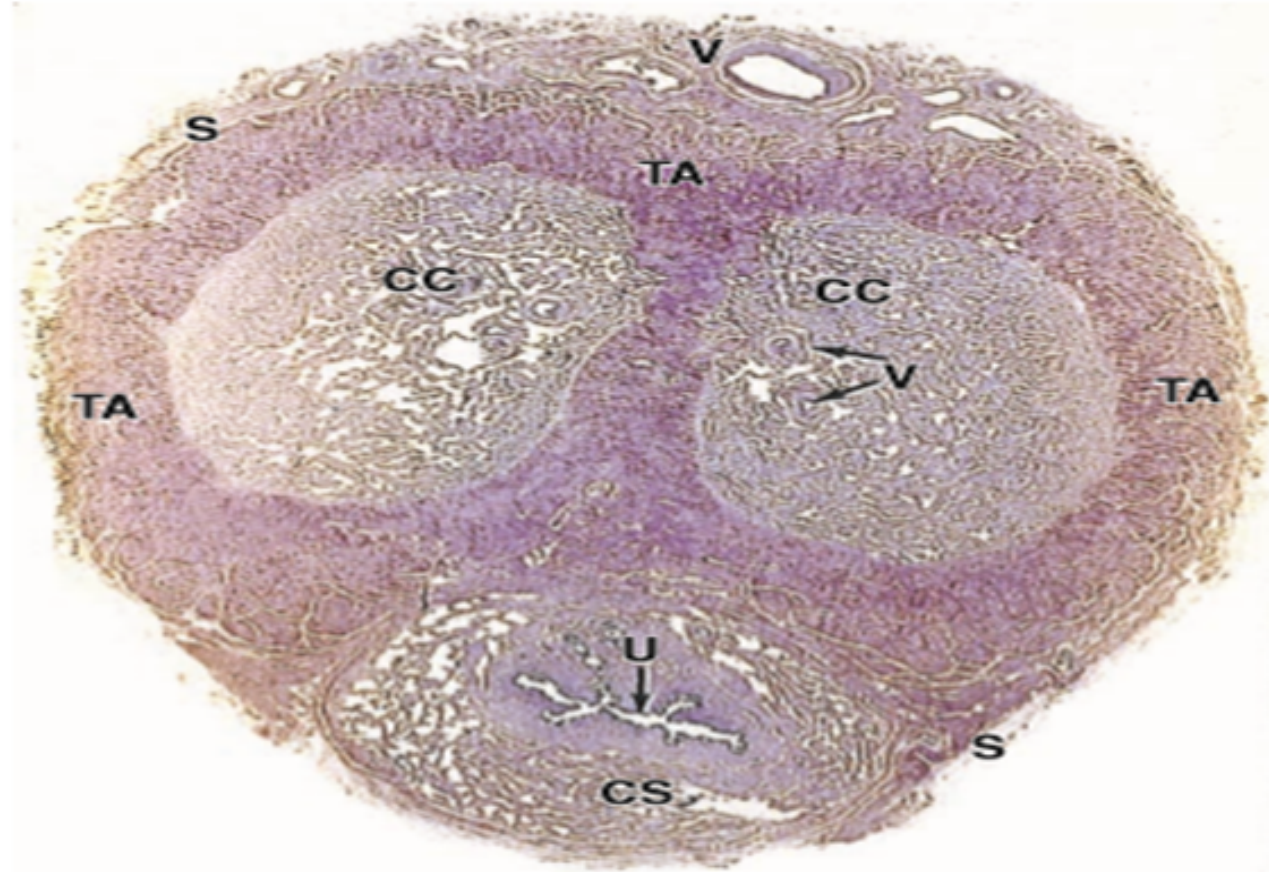
- 1. Two dorsal corpora cavernosa traversed by a deep artery of the penis covered by tunica albuginea.
- 2. A ventral corpus spongiosum traversed by penile urethra seen
- 3. Outer covering of skin seen.

# Slide X: Male urethra (Ihab)

## Anterior urethra



# Male urethra



# Key for identifying a male urethra

- 1. Mucosa lined by transitional or pseudo columnar epithelium
- 2. Lumen is irregular
- 3. Irregular venous spaces surround the lumen.

# References

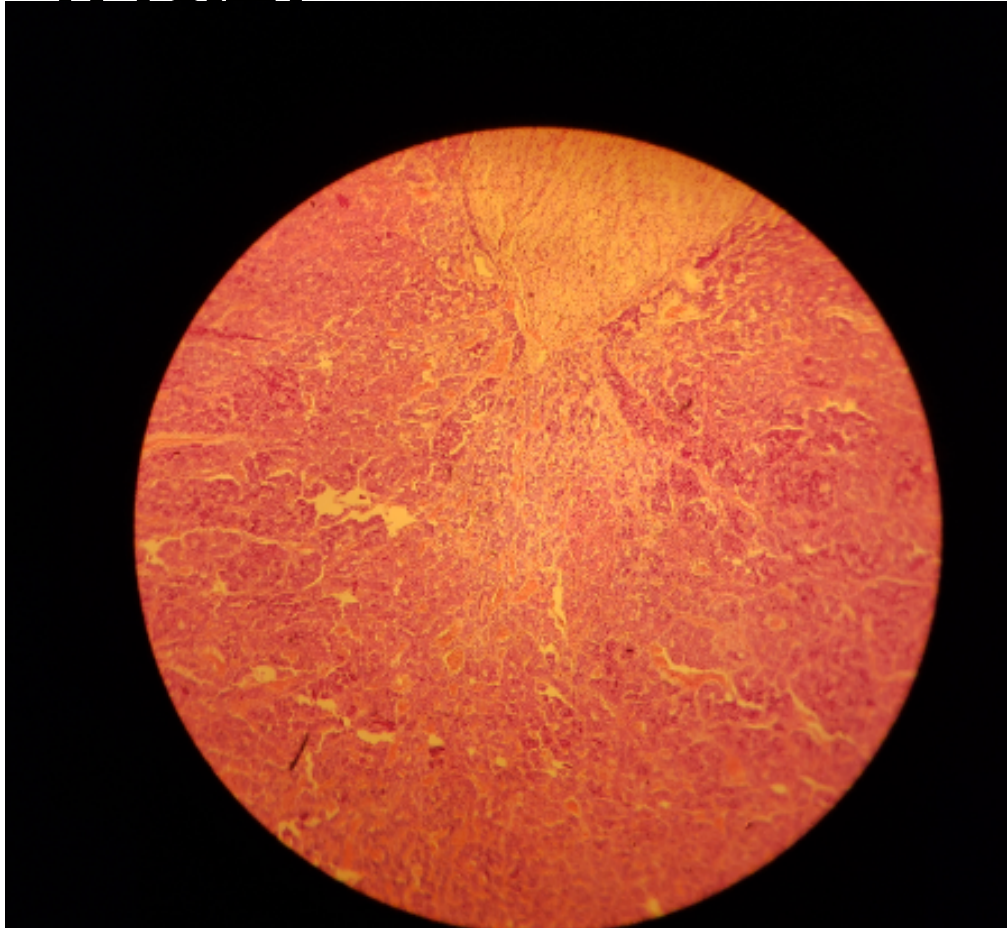
- Junqueira's Basic Histology Text
- Wheaters' Functional Histology A text and Colour Atlas.

# **ENDOCRINE SYSTEM**

## **LAB 22**

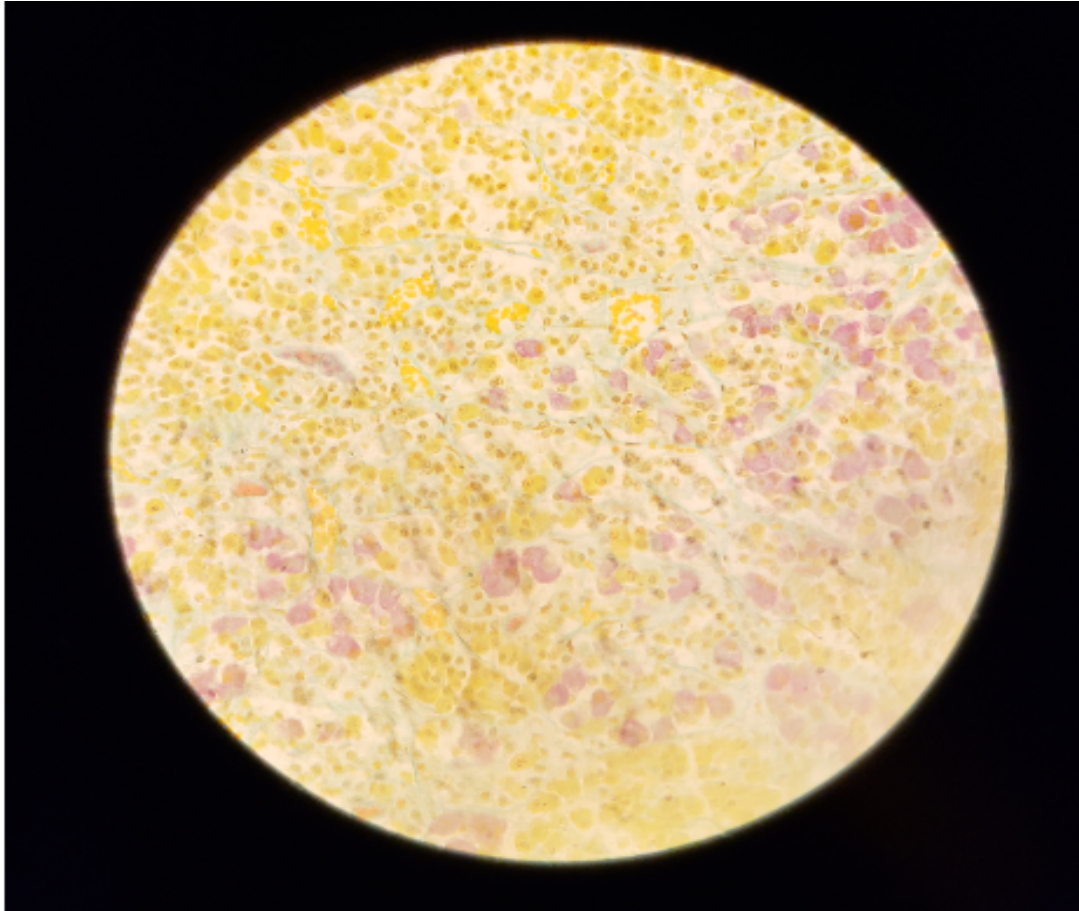
**MR Richwell HAKACHA**

# SLIDE H14.31 HYPOPHYSIS,HUMAN (H&E)



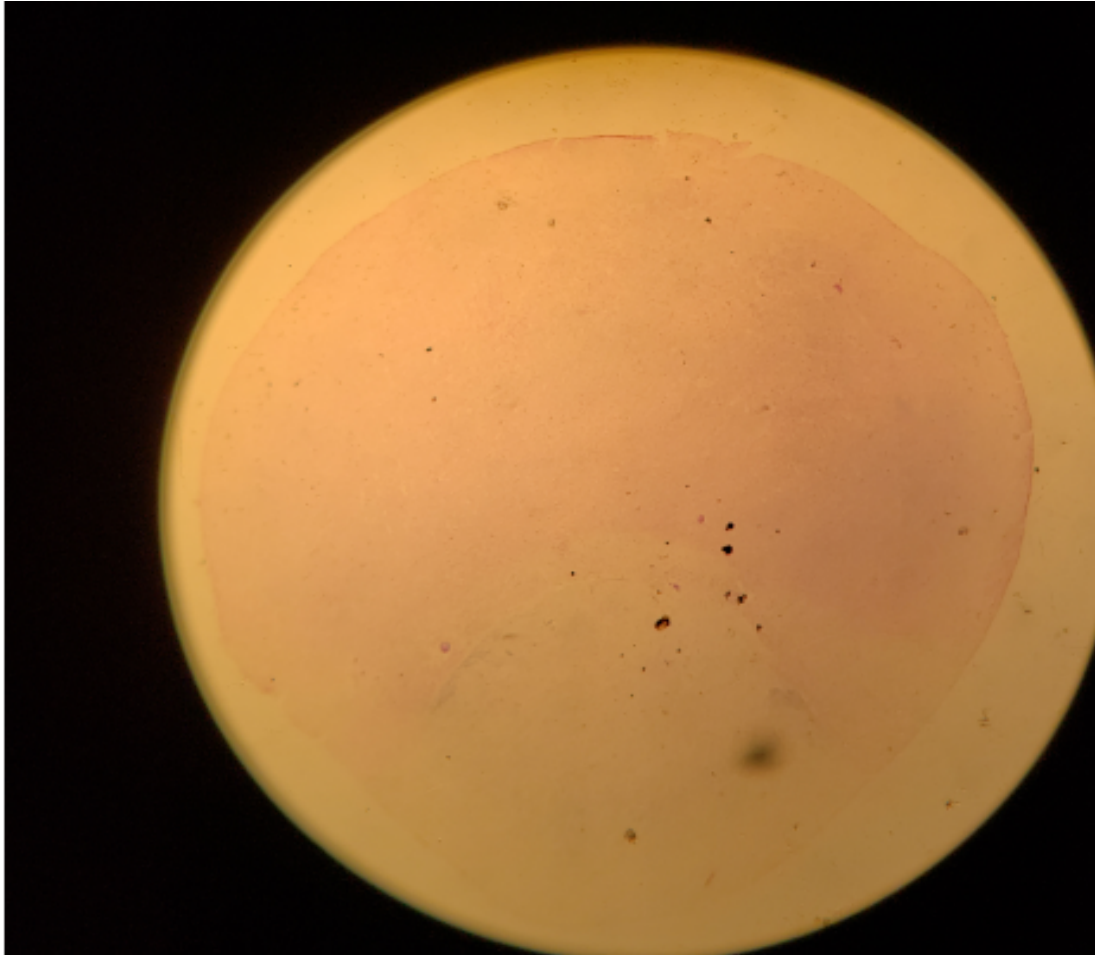
- Pars distalis (dark)
- Pars nervosa (Light)
- Numerous blood sinusoids

# SLIDERS



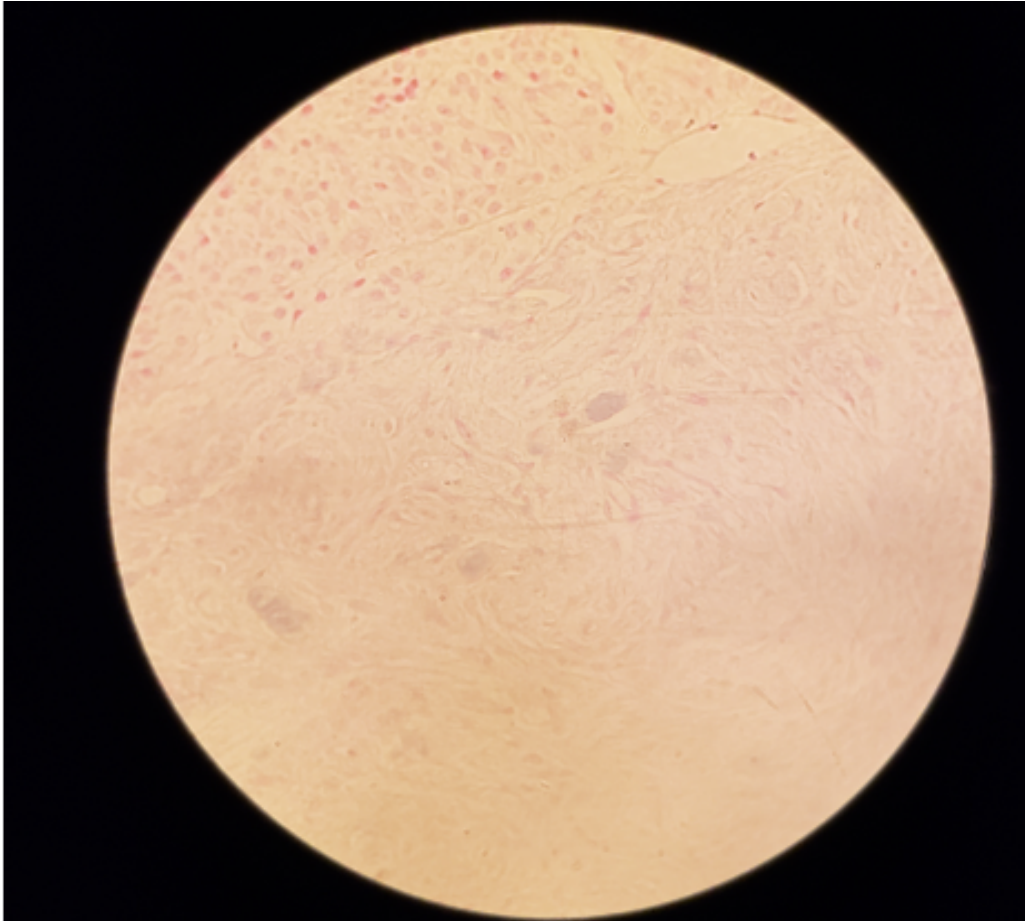
- Acidophil stain **yellowish** cyto granules
- Basophils **brownish** or **bluish** indifferent looking cells
- RBCs **orange**
- Collagen **greenish**

# SLIDE 104 HYPOPHYSIS RABBIT(GOMORI~S CHROME ALUM HAEMATOXYLIN



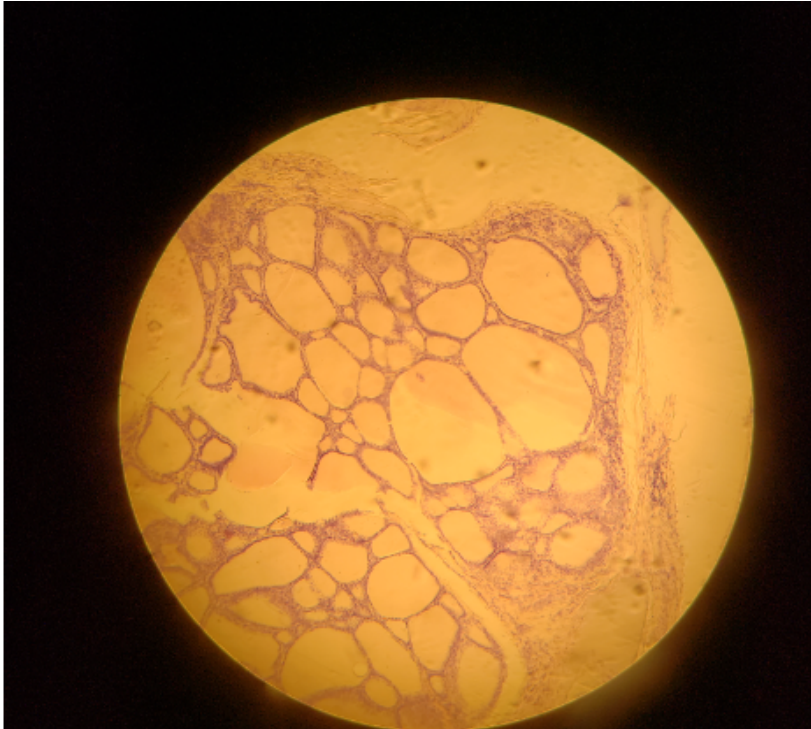
- Three lobes of hypophysis are clearly visible
- Note Pars intermedias close relationship with pars nervosa

# HP PARS NERVOSA



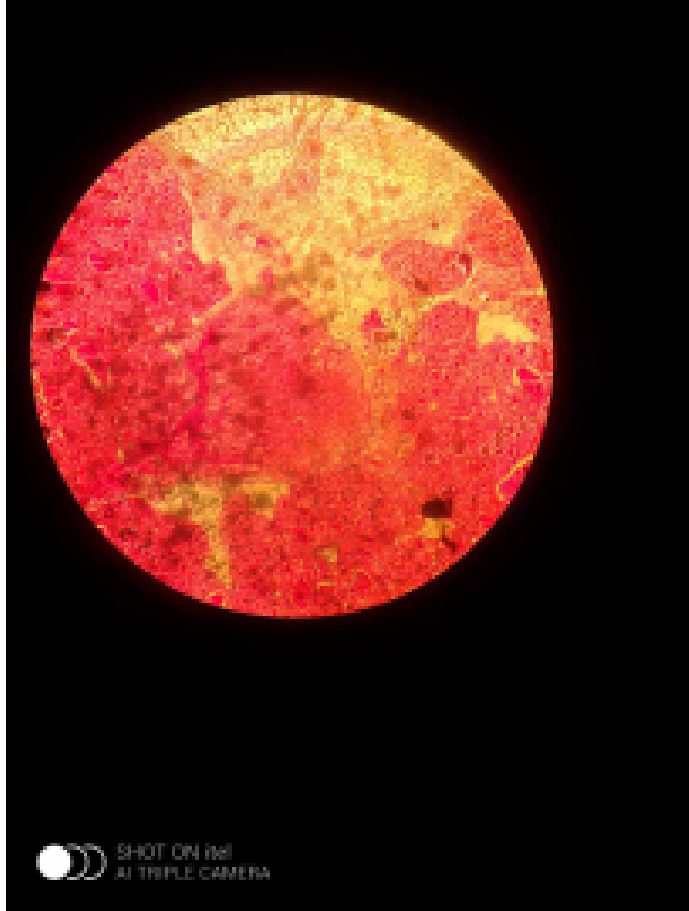
- Contain **nerve fibres**
- Glial cells (Pituicytes) only
- **Herring bodies**(neurosecretory products) may be recognised as accumulations of **dark blue granules**

# SLIDE H14.11 THYROID GLAND HUMAN H&E



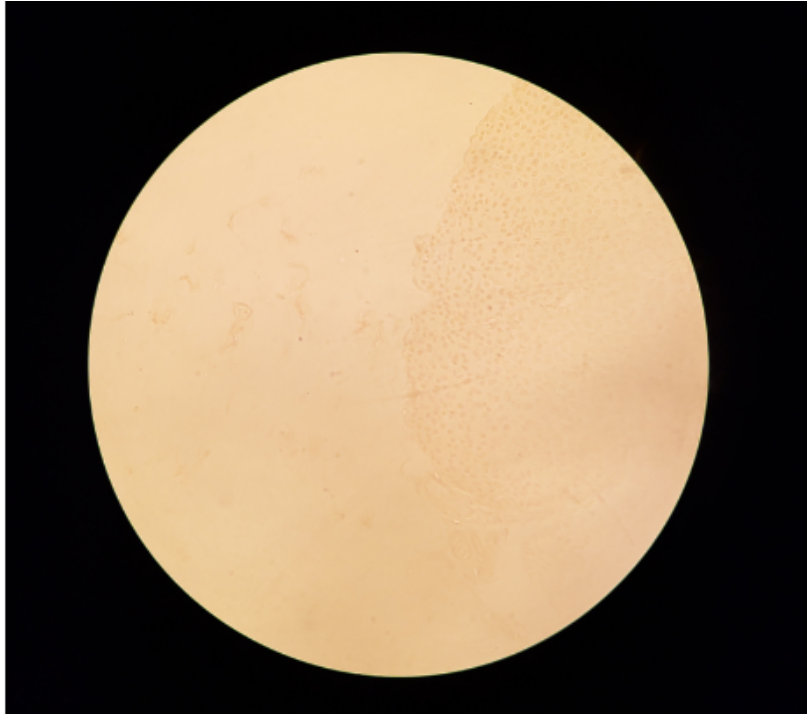
- Study gen pat of follicles
- Lined by low cuboidal epith
- Contain homogenous colloid material
- Interstitial tissues and capillaries

# SLIDE 109 THYROID AND PARATHYROID, KITTEN(H&E)



- Locate small island of parathyroid gland
- Parafollicular © cells

# SLIDE 14.16 PARATHYROID GLAND HUMAN(H&E)

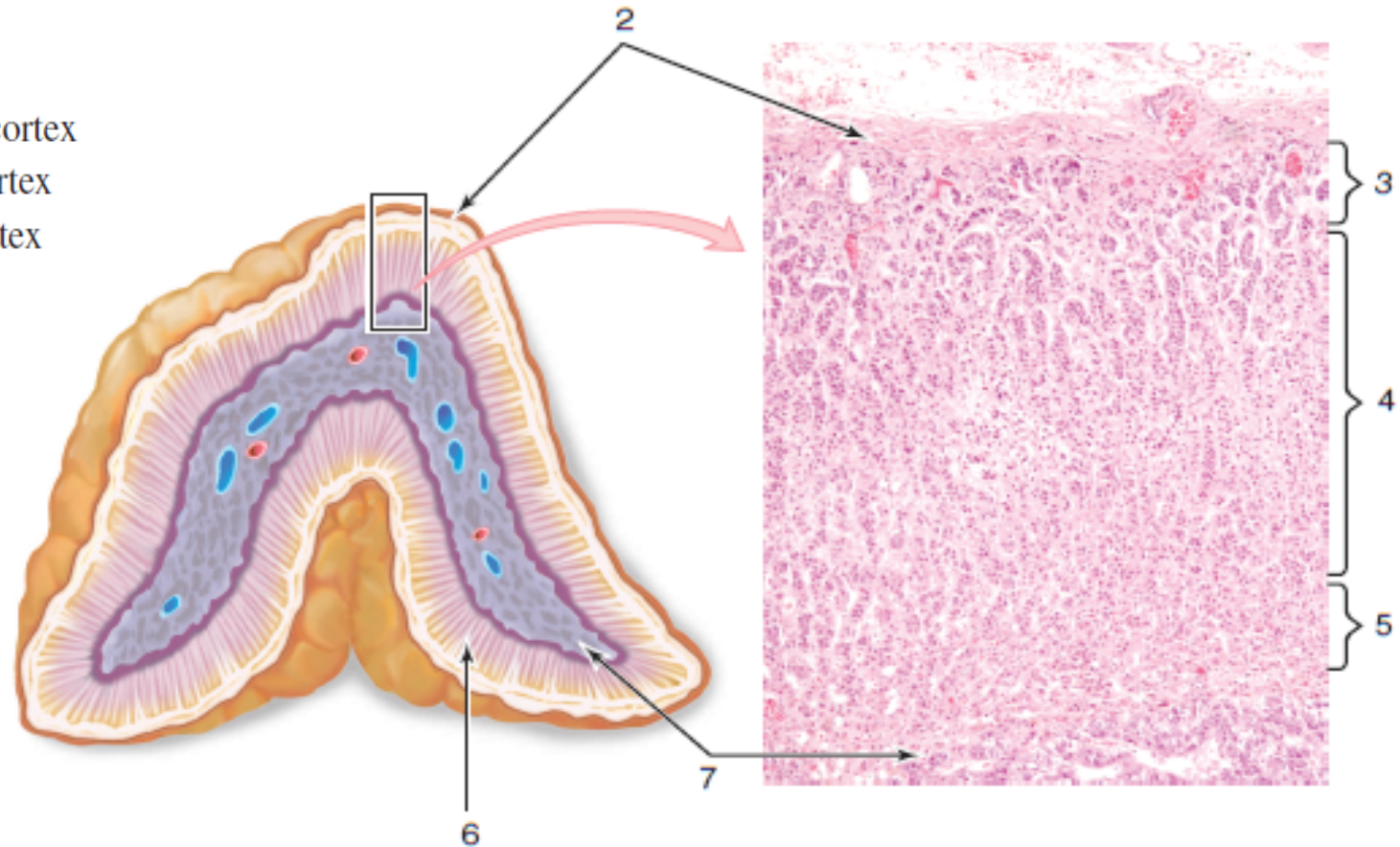


- Thin CT capsule but no lobules
- Parenchyma with closely packed chief(principle) cells
- NO Oxyphil(eosinophil) cells which appear after puberty

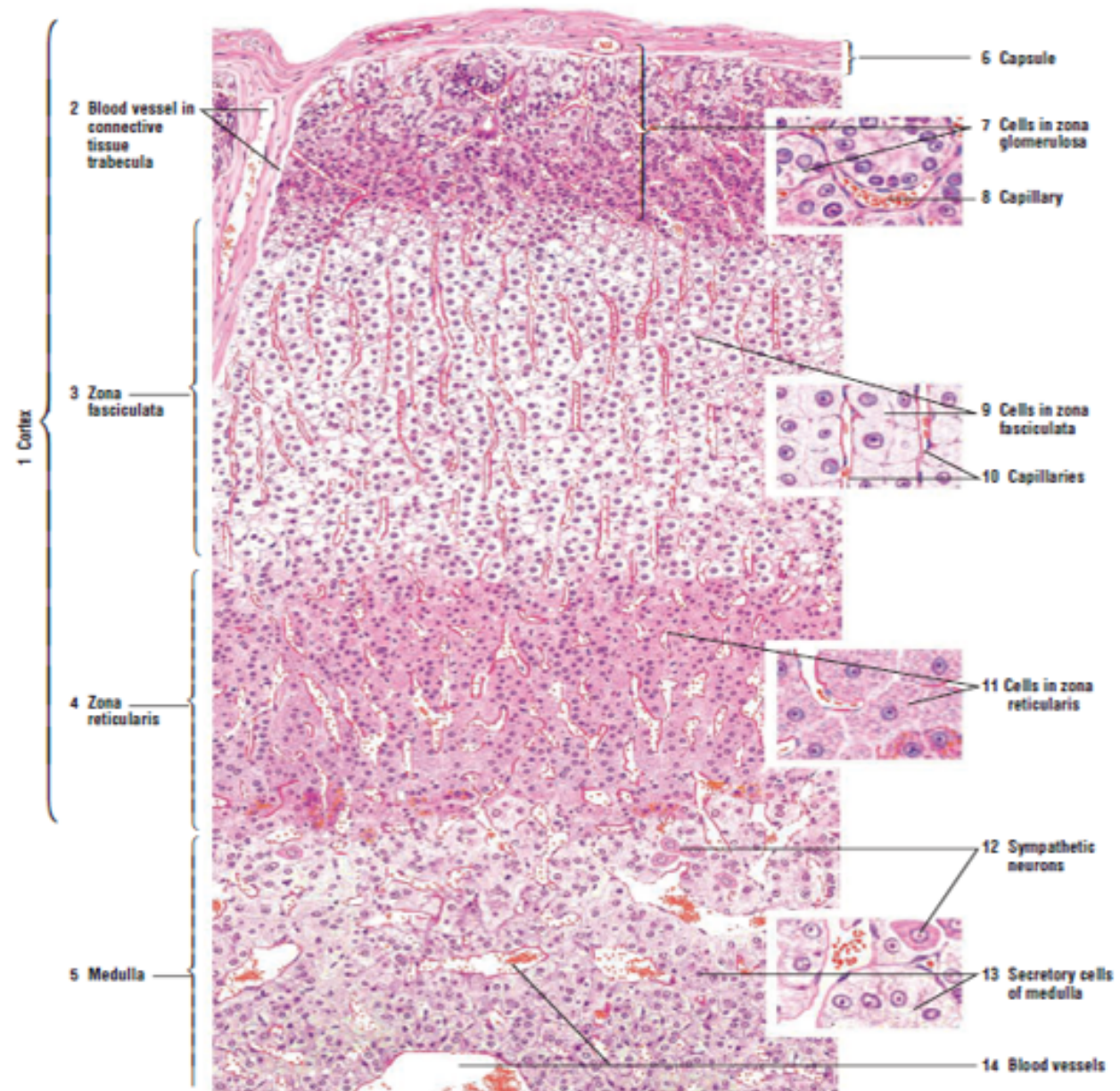


# SUPRARENAL GLAND

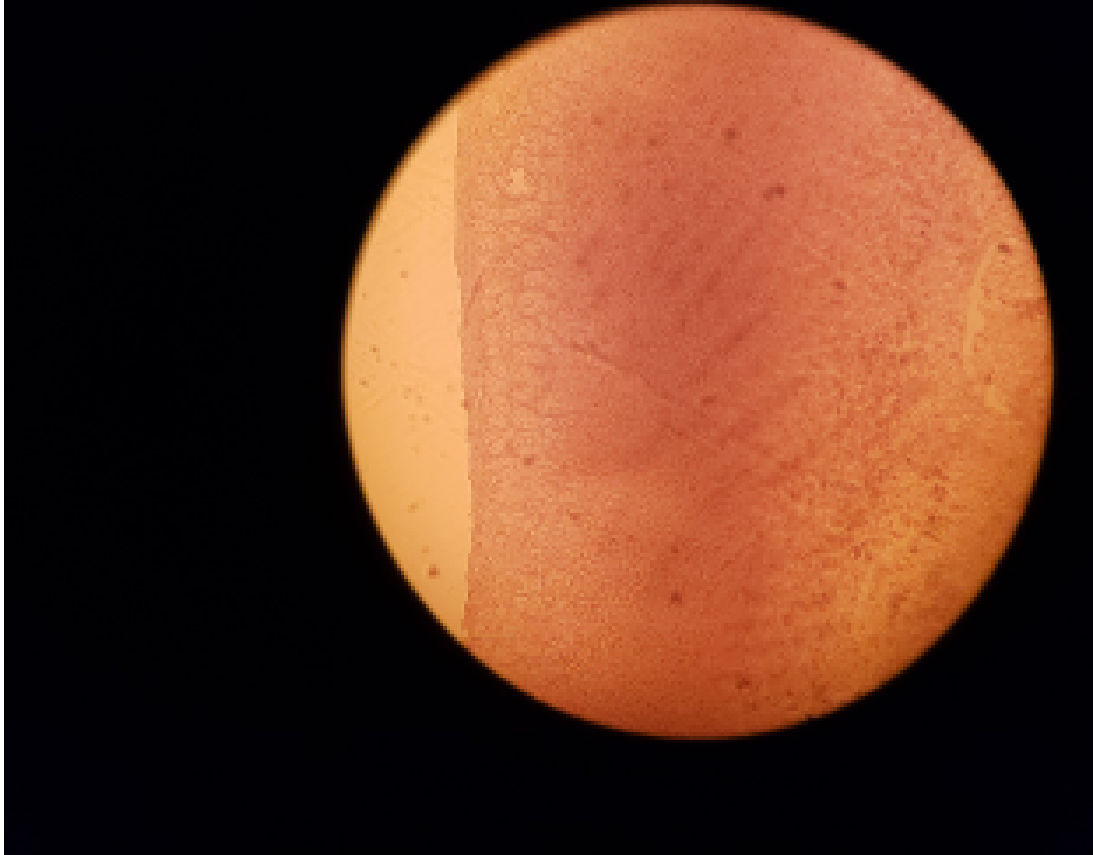
1. Adrenal gland
2. Capsule
3. Zona glomerulosa of adrenal cortex
4. Zona fasciculata of adrenal cortex
5. Zona reticularis of adrenal cortex
6. Adrenal cortex
7. Adrenal medulla



# CONT'D

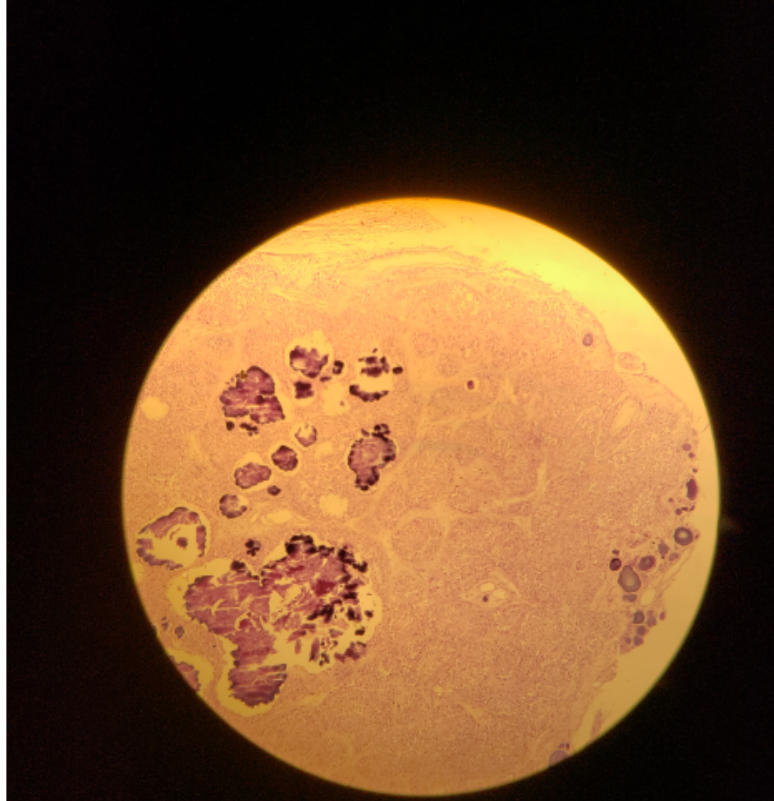


# SLIDE 106 SUPRARENAL GLAND (H&E)



- Capsule, Cortex, Medula
- Zona glomerulosa,
- Zona Fasciculata,
- Zona Reticularis

# SLIDE H14.36 PINEAL BODY(H&E)



- Small lobules
- Pinealocytes and glial cells
- Interlobular CT
- Dark stained lamellated bodies(Corpora arenacea), brain sand