

# AGA 2110

## ANATOMICAL PLANES & DIRECTIONAL TERMS USED IN THE STUDY OF ANATOMY

### Objective

1. To demonstrate the anatomical position of quadrupeds.
2. To identify and recognize the four anatomical planes of reference
3. To familiarize students with *Directional terms* that are used in Anatomy to describe positions of structures relative to other structures in the body of farm animals.

## INTRODUCTION

- ❑ Anatomists use terminology in everyday language
- ❑ Purpose of language is not to confuse but to increase precision & reduce medical errors

eg If a wound is located is located 'above carpus' located on the forearm can you say its on the palmer side or at the 'base of the carpus' or on 'the back side'

- ❑ Use of precise anatomical terminology is for eliminating ambiguity

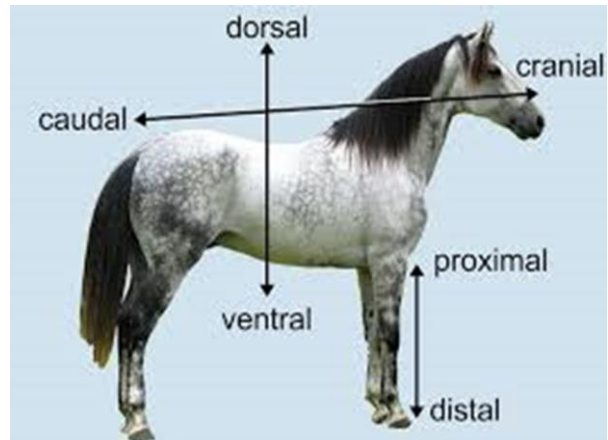
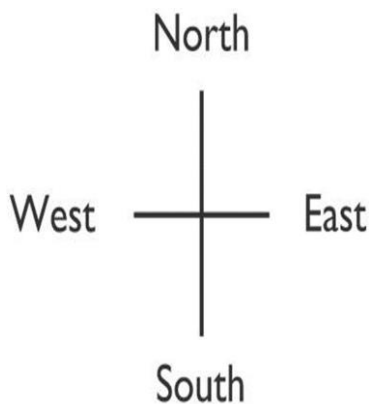
## TERMINOLOGY

- ❑ **Anatomical plane** – An imaginary plane that is used to divide the body into sections in order to make it easier to discuss anatomy
- ❑ **Quadruped** – A animal that walks on 4 legs
- ❑ Anatomical terms were derived from ancient Greek & Latin words
- ❑ Just as maps are oriented with North at the top, the standard body 'map' or '**anatomical position**' should be known

## FUNCTION OF STANDARD ANATOMICAL POSITION

- ❑ Purpose is to clearly talk about the different parts of an animal no what they are moving or position the animal is in thus making it easier to discuss anatomy
- ❑ In quadrupedal animals, standard anatomical position is with all 4 feet on the ground so that the belly of the animal is roughly parallel with the ground

## STANDARD ANATOMICAL POSITION



## INTRODUCTION

- ❑ Since an animal is rarely oriented exactly with a line on the earth's surface, our frames of reference must be in relation to the animal itself & must apply regardless of the position or direction of the animal hence **Anatomical planes** and **directional terms** are used.

## ANATOMICAL PLANES OF REFERENCE

- ❑ **Anatomical planes** are imaginary "slices" through the body that each divide it into 2 parts.
- ❑ Anatomical terms are based on imaginary 'slices' called planes that pass through the body and are used as terms of reference
- ❑ Anatomical terms are also based on directional terms that have opposite meanings of one another.

PLANE	PARTS
<b>Median</b>	equal left and right halves
<b>Sagittal</b>	left and right parts that are not necessarily equal
<b>Transverse</b>	cranial and caudal parts
<b>Dorsal</b>	dorsal and ventral parts

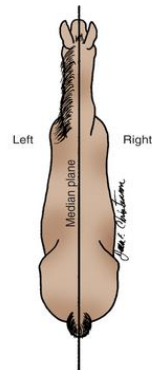
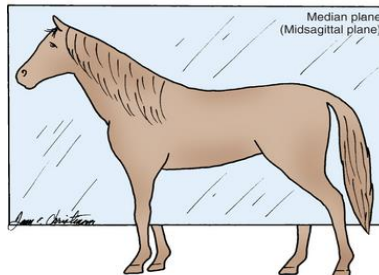
## ANATOMICAL PLANES OF REFERENCE

- ❑ **Anatomical planes** - Imaginary lines that are used to divide the body into sections to make it easier to describe the locations of the body parts.
- ❑ There are **4 anatomic planes of reference**, two of which are variations of each other.
  1. Median plane
  2. Sagittal plane
  3. Transverse plane
  4. Dorsal plane

## ANATOMIC PLANE OF REFERENCE

### 1. MEDIAN PLANE

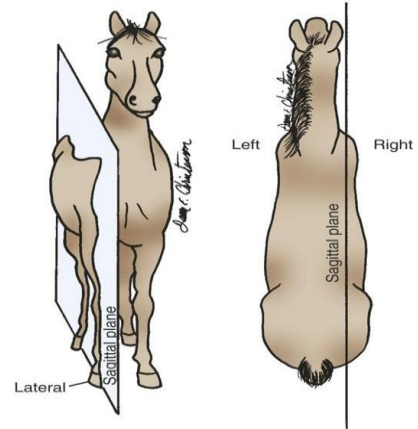
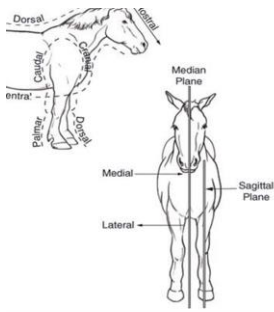
- Runs down the centre of the body dividing the animal into **left & right equal** parts
- Also called mid-sagittal plane



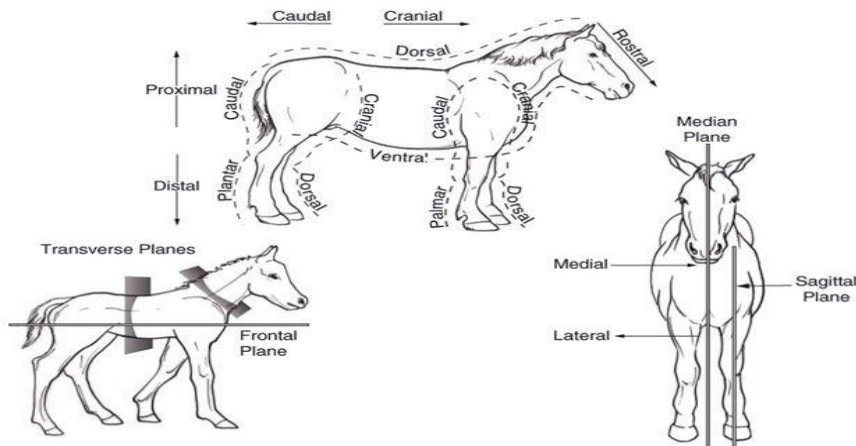
# ANATOMICAL PLANE OF REFERENCE

## 2. SAGITTAL PLANE

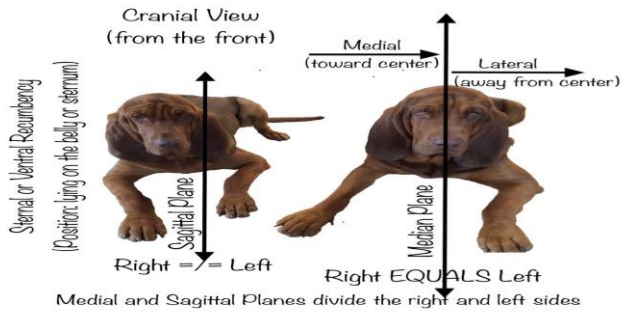
- A plane that runs the length of the body and divides it into left & right parts that are **not equal** halves



## MEDIAN AND SAGGITAL PLANES



## MEDIAN AND SAGITTAL PLANE

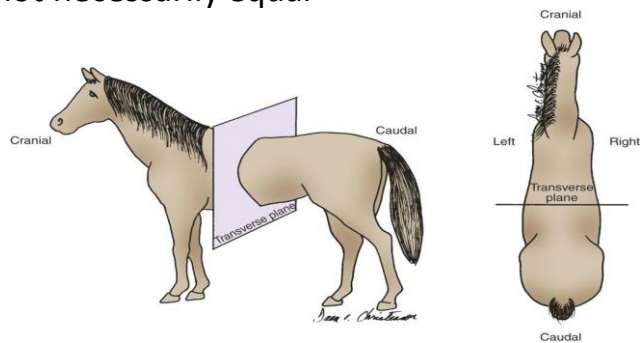


© Tracey Elaine Cavins

## ANATOMICAL PLANES OF REFERENCE

### 3. TRANSVERSE PLANE

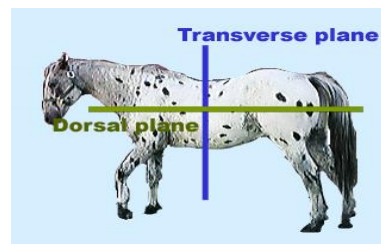
A plane that divides the body into cranial (head-end) & caudal (tail-end) parts that are not necessarily equal



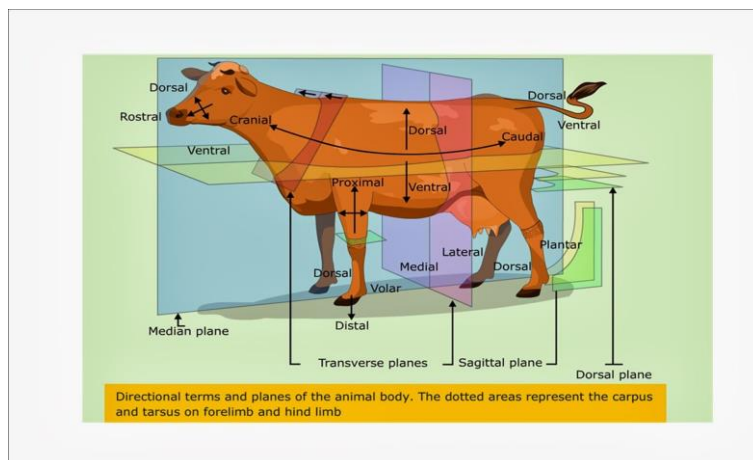
# ANATOMICAL PLANES OF REFERENCE

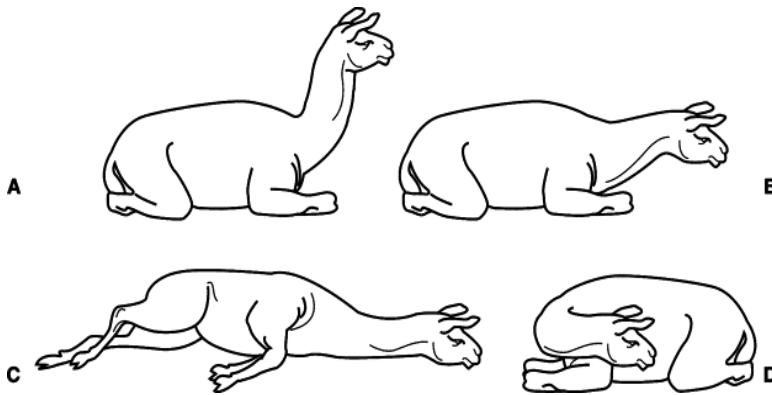
## 4. DORSAL PLANE

- A plane at right angles to the sagittal & transverse planes.
- It divides the body into dorsal (toward the animal's back) & ventral (toward the belly) parts that are not necessarily equal.



# ANATOMICAL PLANE OF REFERENCE





## DIRECTIONAL TERMS

- Provide a common language for accurately & clearly describing body structures regardless of the position of the animal's body
- Terms generally occur in pairs that have opposite meanings & are used to describe **relative** positions of body parts.
- Are relative
- Relative means "**what is located where**" relative to other structures

## DIRECTIONAL TERMS

- ❑ To accurately describe body parts, use terms that leave no doubt about their meanings.
- ❑ Terms such as *up, down, above, below* and *beside* are not very useful because they depend on the orientation of the animal.
- ❑ Orientation of the animal – eg upright, on its side, on its back e.t.c

Examples;

- 1) If an animal is lying on its left side, is its right lung above its left lung or beside it?

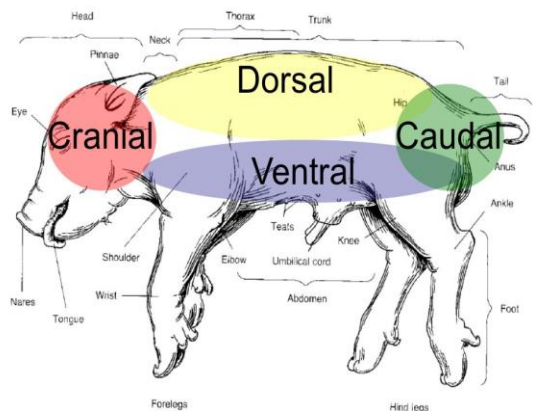
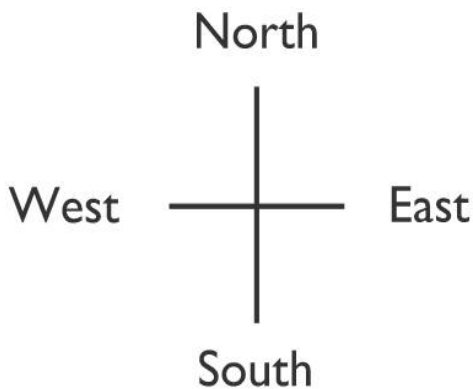
## DIRECTIONAL TERMS/ DESCRIPTIVE TERMS

- ❑ Directional terms provide a common language for accurately & clearly describing body structures regardless of the position of the animal's body.
- ❑ Descriptive terms describe **"where on the animal"**
- ❑ These terms generally occur in pairs that have opposite meanings & are used chiefly to describe relative positions of body parts.

## DIRECTIONAL TERMS

- must have the same meaning regardless of the **orientation** of the animal or the **position** of the observer.
- Basic anatomic terminology is based on imaginary slices called **planes**.
- Correct terminology must be used to describe “**where**” on an animal.
- We will no longer use the following terms:
  - Back
  - Front
  - Below
  - Tail
  - Head
  - The middle
  - The end
  - The bottom of

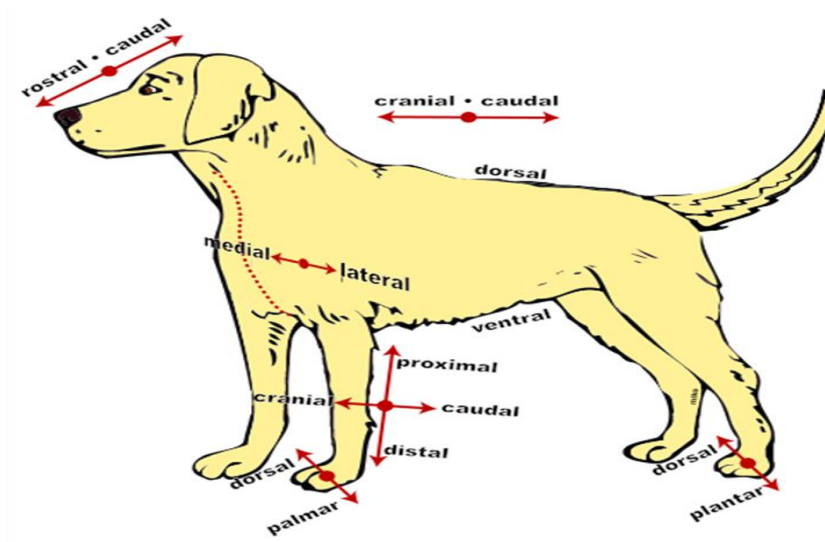
## DIRECTIONAL/ DESCRIPTIVE TERMS



## DIRECTIONAL TERMS

DIRECTIONAL TERM	DEFINITION	EXAMPLE
<b>CRANIAL</b>	Towards the head	<ol style="list-style-type: none"> <li>1. The shoulder is cranial to the hip means shoulder is closer to the head than is the hip</li> <li>2. The lungs are cranial to the intestines</li> </ol>
<b>CAUDAL</b>	Towards the tail	<ol style="list-style-type: none"> <li>1. The ribs are caudal to the neck</li> <li>2. The caudal end of the ribs</li> <li>3. The caudal vertebrae</li> </ol>

## DIRECTIONAL TERMS



## DIRECTIONAL TERMS

- ❑ **ROSTRAL** is a special term used only to describe positions or directions on the head.
- ❑ The term cranial loses its meaning on the head because the cranium is part of the head.
- ❑ Caudal retains its normal meaning on the head because it still means toward the tail end of the animal.
- ❑ Rostral means toward the tip of the nose (rostrum).

## DIRECTIONAL TERMS

Cranial/Rostral/Caudal:

- ▶ **Cranial** -- toward the head
- ▶ **Rostral** -- toward the nose/beak
- ▶ **Caudal** -- toward the tail
- ▶ Separated by the transverse plane



## DIRECTIONAL TERMS

DIRECTIONAL TERM	DEFINITION	EXAMPLE
<b>ROSTRAL</b>	Towards the (muzzle) nose *Nose - rostrum	<ol style="list-style-type: none"> <li>1. There are more grey hairs in the rostral part of the head</li> <li>2. An animal's eyes are located rostral to its ears</li> </ol>
<b>CAUDAL</b>	Back – towards the back	

## DIRECTIONAL TERMS

**DORSAL AND VENTRAL** - refer to “up and down” directions/positions with the animal in a standing position.

Dorsal means toward the back (top surface) of a standing animal & ventral means toward the belly (bottom surface) of a standing animal.

Dorsal & ventral are easiest to visualize in a standing animal, but they retain their meanings regardless of the animal's position.

# DORSAL AND VENTRAL

**VENTRAL ASPECT**



**DORSAL ASPECT**



## DIRECTIONAL TERMS

DIRECTIONAL TERM	DEFINITION	EXAMPLE
<b>DORSAL</b>	Towards/ beyond the backbone or vertebral column	<ol style="list-style-type: none"> <li>1. The kidneys are dorsal to the intestines; they are closer to the vertebral column</li> <li>2. The backbone is dorsal to the belly</li> </ol>
<b>VENTRAL</b>	Towards the belly	<ol style="list-style-type: none"> <li>1. The mammary gland is ventral to the intestines</li> <li>2. Intestines are ventral to the kidneys</li> <li>3. There are 5 types of taste buds on the ventral surface of a dog's tongue</li> </ol>

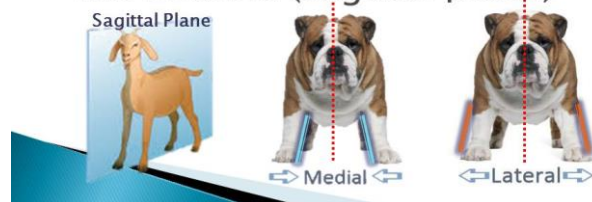## DIRECTIONAL TERMS

### ☐ MEDIAL & LATERAL

- refer to positions relative to the median plane.

Medial/Lateral:

- ▶ **Medial** – directed *toward* the midline (sagittal plane)
- ▶ **Lateral** -- directed *away* from the midline (sagittal plane)

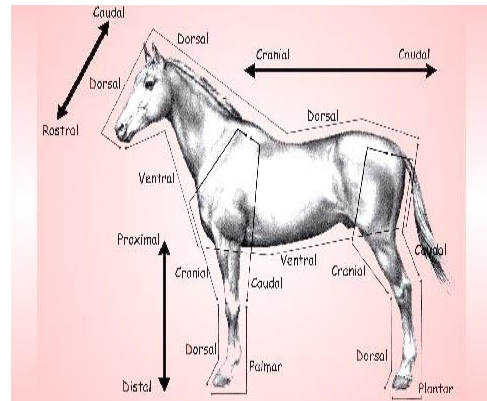


## DIRECTIONAL TERMS

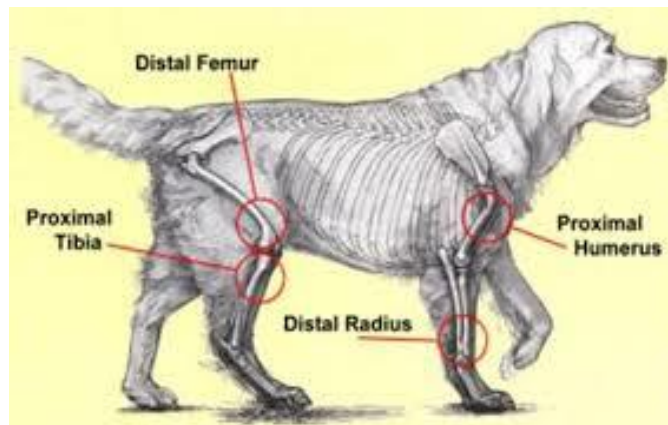
DIRECTIONAL TERM	DEFINITION	EXAMPLE
<b>MEDIAL</b>	TOWARDS THE MEDIAN PLANE	<ol style="list-style-type: none"> <li>1. The heart is medial to the lungs</li> <li>2. The heart is the most medial organ in the body</li> <li>3. The bladder is medial to the thigh</li> </ol>
<b>LATERAL</b>	Away (further) from the median plane	<ol style="list-style-type: none"> <li>1. The ribs are lateral to the lungs</li> <li>2. The animal was made to lie in lateral recumbency</li> <li>3. Ears are lateral to the eyes</li> </ol>

## DIRECTIONAL TERMS

- ❑ **Proximal and distal** - are used to describe positions only on extremities, such as **legs, ears, and tail**, relative to the body.
- ❑ **Proximal** – means closer to the body
- ❑ **Distal** – further from the body



## PROXIMAL /DISTAL



## DIRECTIONAL TERMS

DIRECTIONAL TERM	DEFINITION	EXAMPLE
<b>PROXIMAL</b>	Closer to the body than (only used for structures on limbs)	<ol style="list-style-type: none"> <li>1. The shoulder is proximal to the elbow</li> <li>2. The proximal end of the tail attaches to the body</li> </ol>
<b>DISTAL</b>	Further from the body than (only used for structures on limbs)	<ol style="list-style-type: none"> <li>1. The ankle is distal to the knee</li> <li>2. The toes are located on the distal end of the leg</li> <li>3. The hoof is distal to the knee</li> <li>4. Bladder is distal to the kidney</li> </ol>

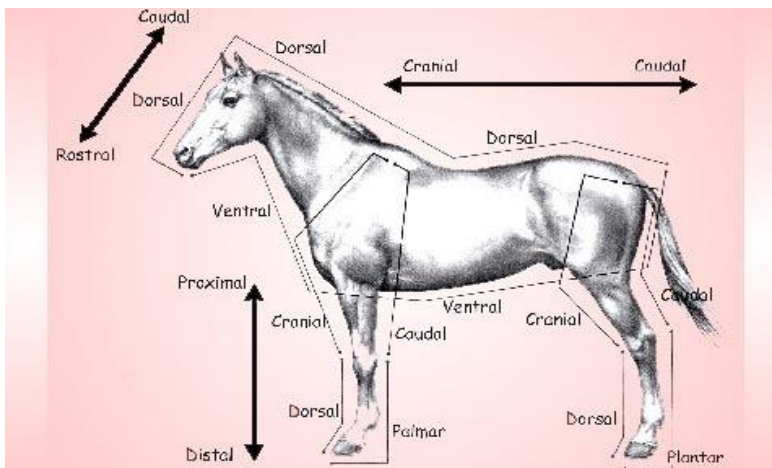
## DIRECTIONAL TERMS

- ❑ The back surface of the front leg from the carpus distally is called the **PALMAR SURFACE** — like the palm of our hand proximal to the carpus it is the caudal surface.
- ❑ The back of the hind leg from the tarsus distally is called the plantar surface—like the plantar or ground surface of our foot—and proximal to the tarsus it is called the caudal surface, just like the front leg.
- ❑ The “front” surface of both the front & hind legs is termed dorsal from the carpus & tarsus distally & cranial proximal to them

## DIRECTIONAL TERMS

DIRECTIONAL TERM	DEFINITION	EXAMPLE
<b>PALMAR</b>	The caudal surface of the forelimb distal to the carpus. Or The "walking" surface of the forelimb	There is a small cut on the left palmar surface
<b>PLANTAR</b>	The caudal surface of the hindlimb distal to the tarsus Or The "walking" surface of the hind paw	The pads are on the plantar side of the foot

## PALMAR/ PLANTAR



## SUPERFICIAL/DEEP

- ❑ Superficial is a directional term that indicates one structure is located more externally than another or closer to the surface of the body
- ❑ The term superficial is a relative one. This means it is not limited to the structures on the very outside of the body such as skin or eyes instead it's about what is located where relative to another structure
- ❑ it can refer to muscles, bone, organs and more

## DIRECTIONAL TERMS

DIRECTIONAL TERM	DEFINITION	EXAMPLE
<b>DEEP (internal)</b>	Towards the centre	The femur is deep to the quadriceps muscles
<b>SUPERFICIAL (External)</b>	Towards the surface	The skin is superficial to the muscles
		The spine is deep in the body

# SUPERFICIAL AND DEEP

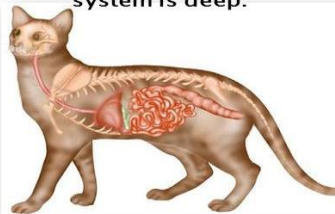
## Superficial/Deep

- ▶ **Superficial** -- located near the surface
- ▶ **Deep** -- located internally, toward the center

**Superficial:** The integumentary system (skin) is superficial



**Deep:** The Digestive system is deep.



# PRONATION AND SUPINATION

## Supination/Pronation:

- ▶ **Supination** -- rotate the limb outward, laterally.
- ▶ **Pronation** -- rotate the limb inward, medially.



**Supination**



**Pronation**

# ABDUCTION/ADDUCTION

- **Abduction** -- move the limb away from the body.
- **Adduction** -- move the limb toward the body.

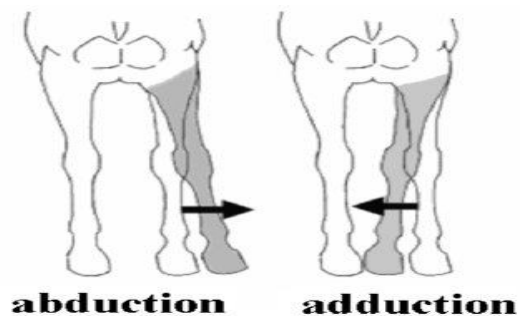
Abduction/Adduction:

▶ **Abduction** -- move the limb away from the body.

▶ **Adduction** -- move the limb toward the body.



# ABDUCTION/ADDUCTION



# RECUMBENT

## Medical terms for lying down

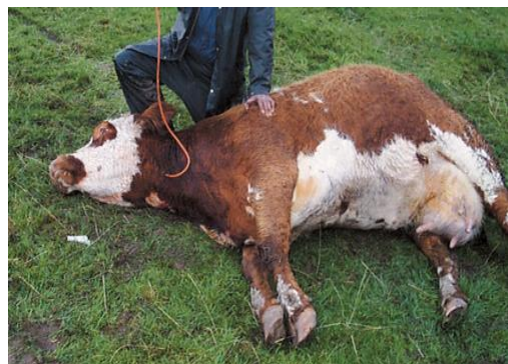- Dorsal recumbency** – lying on the back
- Ventral recumbency** – lying on the stomach
- Lateral recumbency** – lying on the side
- eg A cow is recumbent

# RECUMBENT

## Sternal recumbency



## Lateral recumbency

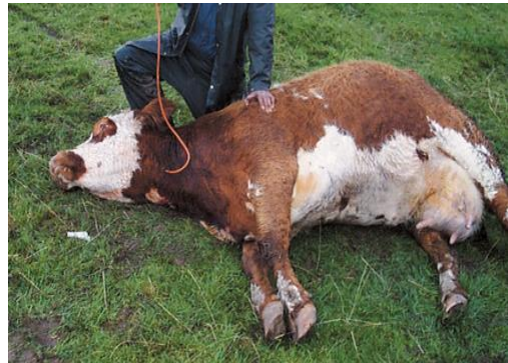

# RECUMBENT

## Dorsal recumbency



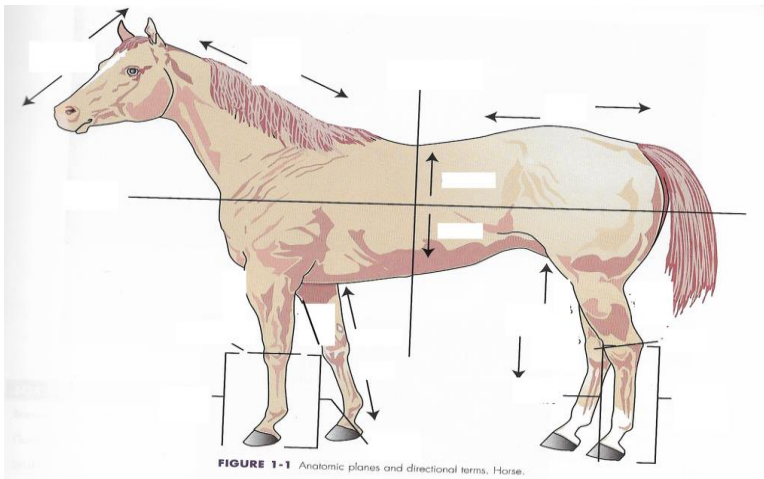
## Lateral recumbency



## COMMON TERMS FOR BODY PARTS

- Head – cranium
- Neck – cervical
- Trunk – thorax
- Belly – abdomen
- front legs – forelimb
- Back legs – hindlegs/ hindlimbs
- Paw – carpus/tarsus, metacarpus/metatarsus, phalanges

## REVISION – DIRECTIONAL TERMS



## COMMON REGIONAL TERMS

- **Barrel** Trunk of the body—formed by the rib cage and the abdomen
- **Brisket** Area at the base of the neck between the front legs that covers the cranial end of the sternum
- **Cannon** - Large metacarpal or metatarsal bone of hoofed animals
- **Fetlock Joint** between cannon bone (large metacarpal/metatarsal) & the proximal phalanx of hoofed animals
- **Flank** - Lateral surface of the abdomen between the last rib and the hind legs
- **Hock** - Tarsus